

CASE REPORT

Unusual presentation of multiple aneurysms of the ascending aorta

Sergio Francisco Santos Jr.,¹ Marcelo Luiz Peixoto Sobral,^{II} Anderson da Silva Terrazas,^{II} Gilmar Geraldo Santos,^{II} Noedir A. G. Stolf^{III,IIII}

^ISanta Casa de Itabuna, Cirurgia Cardiovascular, Itabuna/BA, Brazil. ^{II}Hospital Beneficência Portuguesa de São Paulo, Cirurgia Cardiovascular, São Paulo/SP, Brazil. ^{III}Faculdade de Medicina da Universidade de São Paulo, São Paulo/SP, Brazil.

Email: sergio.cardiaca@gmail.com
Tel.: 55 11 3505-5262

INTRODUCTION

At the beginning of the twentieth century, Carrell and Guthrie were the first to use homografts to reconstruct dilated vessels, starting a new era in aorta surgery.¹ In 1952, Cooley and DeBakey conducted the first successful ascending aorta intervention without cardiopulmonary bypass in the resection of a sacciform aneurysm by aortorrhaphy.² In 1956, the same authors performed the first successful replacement of the ascending aorta using cardiopulmonary bypass.³ Since then, aortic surgery has developed quickly because of advances in cardiopulmonary bypass, post-operative care, and surgical techniques that reduce the mortality rates of these procedures.^{4,5} At present, less invasive techniques, such as endovascular interventions, are performed, especially in thoracic and thoracoabdominal aortic disease, depending on factors such as whether the patients would be at high risk during conventional procedures.^{6,7} Recent studies and case reports have shown the possibility of performing endovascular procedures in the ascending aorta, which seems to be a promising approach.⁷

Concerning ascending aorta aneurysms, there are several surgical approaches depending on the level of the disease of the aortic valve, aortic root, sinotubular junction and the ascending aorta. These issues are relevant in the context of congenital diseases such as Marfans syndrome,⁷ Ehlers-Danlos syndrome,⁸ congenital aortic valve malformations, and acquired aortic valve diseases.⁹

It is accepted that apoptosis is the major mechanism for the control of cell density in developing physiological and pathological conditions affecting smooth muscle cells. It was shown that death signals may be triggered outside the cells by cytokine pathways and stress mechanical forces.⁸ Today, it is known that when there is aortic dilation, there is also cystic medial necrosis. This histological abnormality is characterized by a triad of noninflammatory smooth muscle cell loss, the fragmentation of elastic fibers and the accumulation of basophilic ground substance within cell-depleted areas

of the medial layer of the vessel wall, all of which are noninflammatory in nature.⁹

Medial degeneration does not uniformly involve the ascending aorta.^{8,9} The convexity of the vessel looks more damaged because of more severe medial necrosis, greater loss of smooth muscle cells and apoptosis and greater elastic fiber fragmentation. These alterations play an important role in the development of aortic aneurysms because they participate in the matrix remodeling process resulting in the synthesis of extracellular proteins such as collagen, elastin, and proteoglycans.⁸

CASE REPORT

We report the case of a 24-year-old man who presented progressive precordial pain and dyspnea that had worsened in the last six months prior to the consultation with no previous history of arterial hypertension, dyslipidemia, smoking habits, or infectious diseases, such as syphilis or immunodeficiency syndrome. The physical examination showed no signs of congenital syndromes and revealed only severe systolic murmur in the aortic focus. Preoperative examinations were conducted as routine. Laboratory tests as well as the chest radiograph were unchanged. The electrocardiogram showed sinus rhythm, incomplete right bundle branch block and moderate left ventricular hypertrophy. The echocardiogram revealed aortic stenosis caused by a thickened aortic valve, which determined a gradient of 65 mmHg, left ventricular ejection fraction of 0.63, ascending aortic diameter of 30 mm, and systolic and diastolic diameters of 32 and 48 mm, respectively. Then, we proposed the surgery for aortic valve replacement. The procedure was performed by median sternotomy. After the pericardiotomy, we noticed an uncommon aspect of the ascending aorta, with an irregular surface and thinned dilated areas with soft superficial texture (Figure 1). Aortic cannulation was performed above and medial to the innominate artery, and right atrial cannulation was performed through the right atrial appendage. A left ventricular vent was placed via the right superior pulmonary vein. After total heparinization, cardiopulmonary bypass was then established, the aorta was cross-clamped and a transverse aortotomy was performed. The internal aspect of the vessel was thickened, with multiple focal cavities of different sizes corresponding to the external dilatations; no thrombi were found (Figure 2).

This is an Open Access article distributed under the terms of the Creative Commons Attribution Non-Commercial License (<http://creativecommons.org/licenses/by-nc/3.0/>) which permits unrestricted noncommercial use, distribution, and reproduction in any medium, provided the original work is properly cited.

No potential conflict of interest was reported.

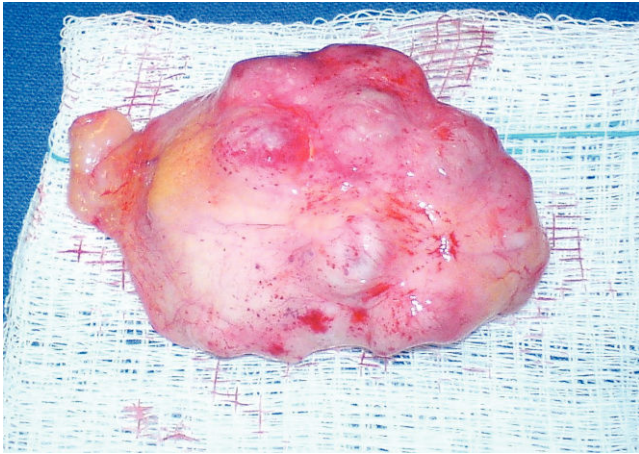

Figure 1 - External macroscopic aspect of the ascending aorta segment.

Antegrade cold blood cardioplegic solution was infused every twenty minutes. The three thickened aortic leaflets, as well as the anterolateral convexity and anteromedial concavity of the aorta were excised, leaving the posterior one third, macroscopically normal, to serve as support tissue to the vascular prosthesis that would be placed. Samples were submitted for histological study, and the procedure was completed. The prosthesis implanted was a mechanical no. 21; a Dacron tube prosthesis (no. 24) was positioned in replacement of the ascending aorta above the coronary ostia. De-airing was performed through a catheter placed in the tube; the aortic cross-clamp was removed. As the heartbeats became effective, the cardiopulmonary bypass was ended, and the surgery was finalized as usual. The patient was sent to the intensive care unit, where he remained for one day. He was then discharged by the tenth day in good health. He recovered and has lived until the present moment without complications.

The histopathological findings were ascending aorta with areas of intimal fibrosis with dystrophic calcification consistent with arteriosclerosis. Areas of medial cystic degeneration with saccular dilations were observed to be diffusely distributed; inflammation was absent (Figure 3-A,B,C). The

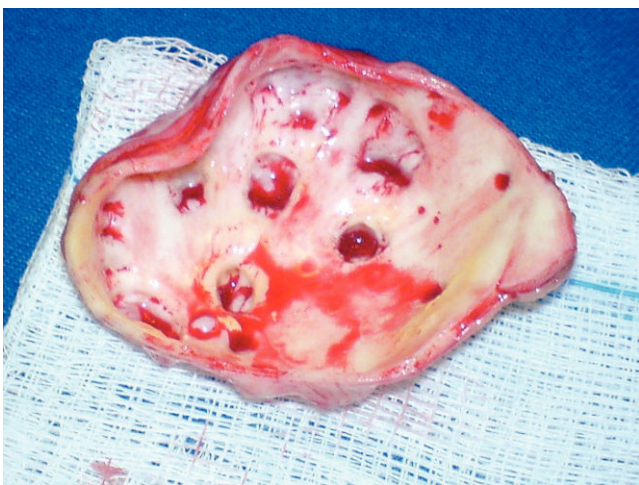

Figure 2 - Internal macroscopic aspect of the ascending aorta segment. Note the multiple focal cavities of different sizes corresponding to the external dilations.

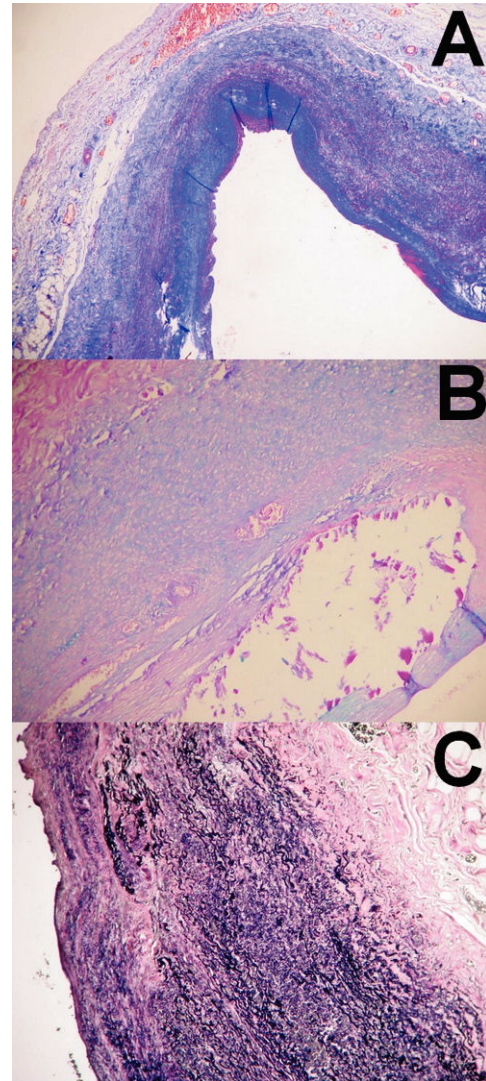


Figure 3 - A) Aorta segment on the level of the little saccular dilations on the aneurysmatic wall showing a severe lack of smooth muscle cells (Tricromic of Masson, 50x). B) "Proteoglycan lakes" are related to the areas of widespread loss of elastic fibers (Alcian Blue, 200x). C) Intense elastic fiber fragmentation area (Verhoeff, 200x).

aortic leaflets were fibrous with myxomatous degeneration and dystrophic calcification. The loss of smooth muscle cells was markedly important, as was the deposition of extracellular matrix following the degeneration.

Angiotomography of the aorta was performed post-operatively and showed no other injuries in the aorta. Furthermore, the prosthetic graft in the ascending aorta and the mechanic valve prosthesis in the aortic position were properly positioned (Figure 4).

Some laboratory tests were performed in order to try to identify infectious diseases, such as syphilis and HIV, and autoimmune diseases, such as vasculitis, with no positive results.

DISCUSSION

These related microscopic changes determine the thinness of the aortic wall; however, these changes do not explain

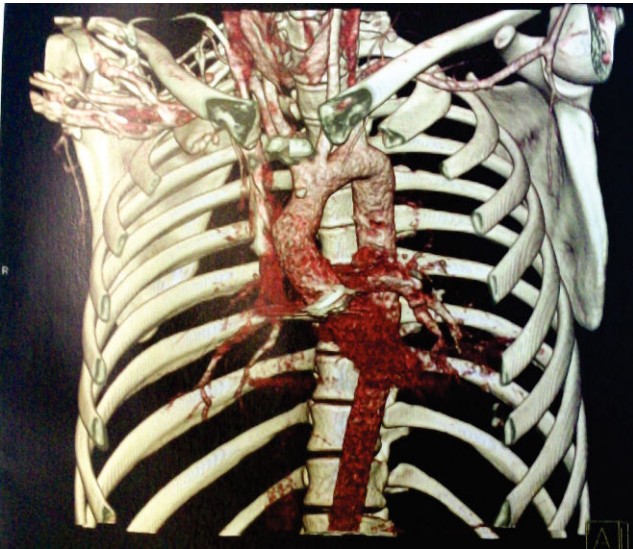


Figure 4 - Angiotomographic construction in three dimensions of the aorta and its branches. No evidence of further injury. Proper positioning of the aortic vascular Dacron graft and the aortic mechanic valve prosthesis.

why this thinning happened in an irregular fashion, causing cavities rather than the uniform dilation that would be expected. The cited histopathological findings confirm cystic medial degeneration, amply described in the medical literature, as the main alteration in those without defined syndromes that could cause modifications in the connective tissues.

Some infectious diseases may cause aneurysms of the ascending aorta; however, in these cases, fibrotic thickening and aortic dilation commonly occur. In this case, post-operative examinations were performed but did not identify diseases such as syphilis or potential causes of autoimmune vasculitis. Poststenotic dilation of the ascending aorta often occurs in chronic cases and displays a uniform enlargement pattern.

Unfortunately, we did not have the chance to proceed with immunohistochemical studies of the surgical samples,

which limits the determination of this disease's etiopathogenesis.

We decided to perform an ascending aorta replacement, which was not indicated by classical aneurysm definitions. Although the largest diameter was 30 mm, not more than 1.5 times the size of the normal aorta, failure to intervene could cause further complications in the future, such as greater dilations, thromboembolic events, aortic dissection or aortic rupture.

AUTHOR CONTRIBUTIONS

Santos Jr SF, surgeon assistant, was responsible for the literature researches and manuscript writing. Sobral MLP, surgeon, was also responsible for the literature researches. Terrazas AS, training surgeon, was responsible for the literature researches. Santos GG, co-chief of surgical team, and literature advisor. Stolf NAG, chief of surgical team, literature advisor, and reviewer.

REFERENCES

1. Brinster DRi, Rizzo RJi, Bolman RMi III. Ascending Aortic Aneurysms. In: Cohn LH, ed. *Cardiac Surgery in the Adult*. New York: McGraw-Hill. 2008;1223-50.
2. Cooley DA, De Bakey ME. Surgical considerations of intrathoracic aneurysms of the aorta and great vessels. *Ann Surg*. 1952;135:660-680, doi: 10.1097/0000658-195205000-00010.
3. Cooley DA, DeBakey ME. Resection of entire ascending aorta in fusiform aneurysm using cardiac bypass. *JAMA*. 1956;162:1158-9.
4. Cohn LH, Rizzo RJ, Adams DH, Aranki SF, Couper GS, Beckel N, et al. Reduced Mortality and Morbidity for Ascending Aortic Aneurysm Resection Regardless of Cause. *Ann Thorac Surg*. 1996;62:463-8, doi: 10.1016/0003-4975(96)00280-9.
5. Cooley DA. Aortic aneurysm operations: past, present, and future. *Ann Thorac Surg*. 1999;67:1959-62, doi: 10.1016/S0003-4975(99)00393-8.
6. Almeida RMS, Leal JC, Saadi EK, Braile DM, Rocha AST, Volpiani G, et al. Thoracic endovascular aortic repair: a Brazilian experience in 255 patients over a period of 112 months. *Interact Cardiovasc Thorac Surg*. 2009;8:524-8, doi: 10.1510/icvts.2008.192062.
7. Palma JH, Gaia DF, Guilhen JS, Buffolo E. Endovascular treatment of chronic type A dissection. *Interact Cardiovasc Thorac Surg*. 2008;7:164-6, doi: 10.1510/icvts.2007.165027.
8. Agozzino L, Santè P, Ferraraccio F, Accardo M, De Feo M, De Santo LS, et al. Ascending aorta dilatation in aortic valve disease: morphological analysis of medial changes. *Heart Vessels*. 2006;21:213-20, doi: 10.1007/s00380-005-0891-z.
9. Bonderman D, Gharehbaghi-Schnell E, Wollenek G, Maurer G, Baumgartner H, Lang IM. Mechanisms Underlying Aortic Dilatation in Congenital Aortic Valve Malformation. *Circulation*. 1999;99:2138-43.