

CLINICAL SCIENCE

Thyroid hormonal disturbances related to treatment of hepatitis C with interferon-alpha and ribavirin

Debora Lucia Seguro Danilovic,^I Maria Cassia Mendes-Correa,^{II} Maria Cristina Chammas,^{III} Heverton Zambrini,^{II} Suemi Marui^I

^IUnidade de Tireóide - Laboratório de Endocrinologia Celular e Molecular - LIM 25 - Faculdade de Medicina da Universidade de São Paulo, São Paulo, SP, Brazil. ^{II}Disciplina de Moléstias Infecciosas, Hospital das Clínicas da Faculdade de Medicina da Universidade de São Paulo, São Paulo, SP, Brazil. ^{III}Disciplina de Radiologia, Hospital das Clínicas da Faculdade de Medicina da Universidade de São Paulo, São Paulo, SP, Brazil.

OBJECTIVE: To characterize thyroid disturbances induced by interferon-alpha and ribavirin therapy in patients with chronic hepatitis C.

INTRODUCTION: Interferon-alpha is used to treat chronic hepatitis C infections. This compound commonly induces both autoimmune and non-autoimmune thyroiditis.

METHODS: We prospectively selected 26 patients with chronic hepatitis C infections. Clinical examinations, hormonal evaluations, and color-flow Doppler ultrasonography of the thyroid were performed before and during antiviral therapy.

RESULTS: Of the patients in our study, 54% had no thyroid disorders associated with the interferon-alpha therapy but showed reduced levels of total T3 along with a decrease in serum alanine aminotransferase. Total T4 levels were also reduced at 3 and 12 months, but free T4 and thyroid stimulating hormone (TSH) levels remained stable. A total of 19% of the subjects had autoimmune interferon-induced thyroiditis, which is characterized by an emerge of antithyroid antibodies or overt hypothyroidism. Additionally, 16% had non-autoimmune thyroiditis, which presents as destructive thyroiditis or subclinical hypothyroidism, and 11% remained in a state of euthyroidism despite the prior existence of antithyroidal antibodies. Thyrotoxicosis with destructive thyroiditis was diagnosed within three months of therapy, and ultrasonography of these patients revealed thyroid shrinkage and discordant change in the vascular patterns.

DISCUSSION: Decreases in the total T3 and total T4 levels may be related to improvements in the hepatocellular lesions or inflammatory changes similar to those associated with nonthyroidal illnesses. The immune mechanisms and direct effects of interferon-alpha can be associated with thyroiditis.

CONCLUSION: Interferon-alpha and ribavirin induce autoimmune and non-autoimmune thyroiditis and hormonal changes (such as decreased total T3 and total T4 levels), which occur despite stable free T4 and TSH levels. A thyroid hormonal evaluation, including the analysis of the free T4, TSH, and antithyroid antibody levels, should be mandatory before therapy, and an early re-evaluation within three months of treatment is necessary as an appropriate follow-up.

KEYWORDS: Thyroid hormones; Hepatitis C; Interferon-induced thyroiditis; Destructive thyroiditis; Thyroid ultrasonography.

Danilovic DLS, Mendes-Correa MC, Chammas MC, Zambrini H, Marui S. Thyroid hormonal disturbances related to treatment of hepatitis C with interferon-alpha and ribavirin. Clinics. 2011;66(10):1757-1763.

Received for publication on March 29, 2011; First review completed on May 16, 2011; Accepted for publication on July 4, 2011

E-mail: deboraseguro@hotmail.com

Tel.: 55-11-95177498

INTRODUCTION

Hepatitis C is a disease that is disseminated worldwide, and chronic infections affect up to 80% of the infected

subjects.¹ Consequently, interferon-alpha (IFN α) therapy has frequently been used. IFN α is one of a group of cytokines with antiviral, antiproliferative, and immunomodulatory properties. In cases of hepatitis C, the presence of moderate to severe necroinflammatory activity and/or moderate to severe fibrosis (as assessed by a liver biopsy) represent formal indications of IFN α use. The drug is available in both conventional and pegylated forms and is frequently used in association with ribavirin, another antiviral drug.^{2,3} The treatment is continuous and lasts from 6 to 12 months, and retreatment can be necessary.

This is an Open Access article distributed under the terms of the Creative Commons Attribution Non-Commercial License (<http://creativecommons.org/licenses/by-nc/3.0/>) which permits unrestricted noncommercial use, distribution, and reproduction in any medium, provided the original work is properly cited.

No potential conflict of interest was reported.

IFN α has several adverse effects, ranging from influenza-like symptoms to severe hematologic abnormalities and pulmonary complications.⁴ These adverse effects provoke dose reduction in up to 40% of cases and treatment withdrawal in up to 14% of cases.⁵

IFN α can commonly induce thyroiditis, which is classified as either autoimmune or non-autoimmune interferon-induced thyroiditis (IIT).⁶ Autoimmune IIT manifests as Hashimoto's thyroiditis, which is defined by an emerge of or worse in antithyroid antibody levels with or without hypothyroidism. In rare cases, autoimmune IIT also manifests as Graves' disease, which is defined by antithyroid antibodies with hyperthyroidism. Non-autoimmune IIT presents as destructive thyroiditis and hypothyroidism.⁶

Hashimoto's thyroiditis is diagnosed in up to 40% of patients, and hypothyroidism can be triggered by IFN α .⁷ Hypothyroidism frequently escapes diagnosis due to the overlap of its symptoms with those induced by IFN α itself, such as fatigue, somnolence and depression.

Rarely, IFN α induces Graves' disease, the diagnosis of which is based on hyperthyroidism with goiter and the presence of thyroid stimulating hormone receptor antibodies.⁷ Its treatment demands precaution due to the hepatotoxic and hematologic side effects of antithyroid drugs.

Destructive thyroiditis represents a form of non-autoimmune IIT characterized by self-limited thyrotoxicosis with a triphasic evolution similar to that of subacute thyroiditis. In the first phase, the patient shows thyrotoxicosis, low radioiodine uptake and the absence of antithyroid antibodies. Hypothyroidism follows euthyroidism within a few weeks to months. Hypothyroidism can persist, especially in the presence of antithyroid antibodies. Destructive thyroiditis may recur upon re-treatment, and it is not necessary to discontinue IFN α use.⁶

Our study prospectively characterized the manifestations of thyroid disturbances induced by IFN α and ribavirin therapy in chronically HCV-infected subjects.

MATERIALS AND METHODS

Patients

Out of the 112 subjects diagnosed with chronic hepatitis C and receiving follow-up at the *Hospital das Clínicas da Faculdade de Medicina da Universidade de São Paulo* between January 2007 and July 2009, 26 patients who were beginning IFN α and ribavirin therapy were prospectively selected. None of the patients had previously been treated with interferon. The diagnosis of chronic HCV infection was based on a positive anti-HCV serology and the presence of viral nucleic acid, as evaluated by polymerase chain reaction (PCR) using the commercial Amplicor HCV test (Roche Diagnostics Systems). The type and duration of the IFN α therapy was based on the viral genotype. Non-cirrhotic genotypes 2 and 3 received non-pegylated IFN α for 24 weeks. Cirrhotic genotypes 2 and 3, genotype 1 and HCV with human immunodeficiency virus (HIV) co-infection (independent of the HCV genotype) received pegylated IFN α for 48 weeks, provided that the HCV RNA became undetectable or that the number of viral copies decreased at least 2 logs (100-fold) within 12 weeks. Any patients with HBV infections, those who were pregnant, and those who were using amiodarone or lithium were excluded.

The study was approved by the institutional research ethics committee, and all of the subjects gave their informed written consent to participate.

Methods

The patients underwent clinical and hormonal evaluations before treatment and every 12 weeks during treatment.

Serum alanine aminotransferase (ALT) and aspartate aminotransferase (AST) were measured using conventional methods. HCV genotyping was performed using a reverse hybridization assay, the Line Probe Assay (INNO-LiPA HCV/VERSANTTM HCV Genotype Assay, Bayer Corporation, Tarrytown, NY, USA).

Total T3 (TT3), total T4 (TT4), free T4 (FT4), TSH and thyroglobulin (Tg) levels were measured using commercial fluoroimmunoassay kits (AutoDELFIA®, Upsala, Turku, Finland). Serum anti-thyroglobulin (anti-Tg) and anti-thyroperoxidase (anti-TPO) antibodies were measured using commercial indirect fluoroimmunoassay kits (AutoDELFIA®, Upsala, Turku, Finland). Thyroid-stimulating hormone receptor antibody (TRAb) levels were evaluated by an immunoradiometric assay (RSR, Cardiff, Wales, UK).

Hashimoto's thyroiditis was defined by increased levels of anti-Tg or anti-TPO antibodies (>35 mUI/L). Subclinical hypothyroidism was diagnosed when TSH levels were increased (>4.5 mUI/L) and when FT4 levels were within the normal range (0.7 – 1.5 ng/dL), whereas overt hypothyroidism was diagnosed based on increased TSH levels associated with decreased FT4 levels. Thyrotoxicosis was characterized by increased FT4 levels and depressed TSH levels (<0.03 mUI/L). Destructive thyroiditis was diagnosed by the presence of thyrotoxicosis in the absence of TRAbs, followed by subclinical or overt hypothyroidism (either transitory or permanent).

Color-flow Doppler thyroid ultrasonography (CDUS) was performed by a single investigator (7.5–12 MHz, Philips HDI 5000 device; Philips Medical Systems, Bothell, WA, USA) before therapy and after 12 months of therapy. The thyroid parenchyma and echogenicity, the presence of nodules, the glandular volume and vascularization were evaluated. Vascularization was classified according to Bogazzi et al., as follows: pattern 0, the absence of intraparenchymal vascularity or minimal spots; pattern I, the presence of parenchymal blood flow with a patchy and uneven distribution; pattern II, a mild increase in color-flow Doppler signal with patchy distribution; pattern III, a marked increase in color-flow Doppler signal with diffuse homogeneous distribution.⁸

Statistical analysis

The data were processed using SPSS 13.0 software. Two-tailed *p*-values were calculated, and *p*-values of <0.05 were considered to be statistically significant.

The categorical variables are presented as absolute and relative frequencies (percentages). Any differences were evaluated by Pearson's χ^2 test and Fisher's exact test, where appropriate. The continuous variables are presented as the means \pm standard deviations. Kolmogorov-Smirnov or Shapiro-Wilk statistics were used to test for any deviations from normality. Any differences among the studied subgroups were determined using Student's *t*-test and one-way ANOVA for the normally distributed data, and the Mann-Whitney U, Wilcoxon, and Kruskal-Wallis tests were used for the non-normally distributed data.

RESULTS

Clinical features

A total of 26 patients, including 15 female patients, were treated with IFN α and ribavirin. The mean patient age was 43.1 ± 11.8 years. Of the subjects, 85% had normal thyroid function and no antithyroid antibodies before the onset of treatment. Four patients (15%) were diagnosed with Hashimoto's thyroiditis with euthyroidism.

Throughout the duration of the IFN α treatment, 14 patients maintained normal thyroid function. IFN α induced thyroiditis in 35% of the cases. Autoimmune thyroiditis, which is characterized as an emerge of antithyroidal antibodies and overt autoimmune hypothyroidism, was detected in 19% of the cases (two patients). Destructive thyroiditis occurred in 8% of the patients, and 8% developed non-autoimmune subclinical hypothyroidism. IIT appeared after 6.2 ± 3.3 months of therapy. However, all of the cases of destructive thyroiditis involved asymptomatic thyrotoxicosis, with hormonal diagnosis occurring as early as three months into the treatment. Finally, 11% of the patients remained in a state of euthyroidism after hepatitis C therapy despite the prior presence of antithyroidal antibodies.

Patients with normal thyroid function during IFN α treatment

In the 14 patients (eight males) with normal thyroid function before and during the IFN α treatment, a significant decrease in TT3 levels ($p=0.038$) was observed after 12 months of therapy, along with a significant reduction in TT4 levels after 3 and 12 months ($p=0.039$ and $p=0.008$, respectively), despite TT3 and TT4 levels falling within the normal range. Interestingly, the FT4 and TSH levels remained stable. A decrease in ALT levels ($p=0.055$), suggestive of the precocious regression of hepatocellular lesions, was also noted, although the AST levels presented no significant decrease (Figure 1).

Patients with interferon-induced thyroiditis

The clinical, hormonal and CDUS characteristics of the subjects with autoimmune and non-autoimmune IIT were compared to those of patients with no therapy-related thyroid disorders (Table 1).

All of the patients who were diagnosed with autoimmune IIT were female, which represented a significantly higher number of females ($p=0.045$) compared to subjects with no therapy-related thyroid disorders. The pre-treatment levels of TT3 (141 ± 18 ng/dL, $p=0.018$) and TT4 (8.8 ± 0.7 μ g/dL, $p=0.005$) were significantly lower, and the TSH levels tended to be higher (3.1 ± 1.2 mUI/L, $p=0.079$) in the patients with non-autoimmune IIT compared to the patients with no thyroid disorders (TT3, 184 ± 36 ng/L; TT4, 11.9 ± 2.0 μ g/dL; TSH, 1.8 ± 0.7 mUI/L). No differences in age, race, HIV co-infections, the HCV genotype, the type of IFN α used (pegylated or non-pegylated), the length of the therapy and the CDUS features were observed between the IIT patients and the subjects with no thyroid-related disorders.

Two subjects developed autoimmune hypothyroidism during the IFN α treatment. One had prior anti-Tg and anti-TPO antibodies, and the other had developed both antibodies at the onset of the hormonal disturbance. No specific symptoms were reported, even with TSH levels as high as 123 mU/L and 128 mU/L, respectively.

Levothyroxine replacement therapy was necessary and was maintained through the final evaluation. The thyroid disturbances in the cases of autoimmune IIT were unresolved during follow-up.

The hormonal dysfunction in both of the cases of non-autoimmune subclinical hypothyroidism regressed during or after IFN α withdrawal. One of the cases presented an asymptomatic TSH increase (5.8 mU/L) within five months of the IFN α therapy, with subsequent normalization despite the maintenance of the antiviral therapy. The other case showed an asymptomatic TSH increase (6.2 mU/L) after ten months of therapy, and hormonal normalization occurred six months after IFN α withdrawal.

Two patients had destructive IFN α -induced thyroiditis (Figure 2). The first case presented as asymptomatic thyrotoxicosis within three months of therapy (Figure 2A). The thyroglobulin levels rose from 27.7 ng/dL to 106 ng/dL. The tests for the anti-Tg and anti-TPO antibodies and TRAB remained negative. The initial CDUS revealed heterogeneous isoechoic parenchyma and increased vascularization (pattern III), and the glandular volume was 8.4 g. One month after the diagnosis of thyrotoxicosis, a new examination revealed a decrease in thyroid vascularization (pattern II) and concomitant glandular shrinkage (42%). Such modifications persisted during CDUS performed 8.5 months after the end of the therapy. The second case had a similar evolution (Figure 2B). The diagnosis of asymptomatic thyrotoxicosis was made within 3.4 months of the onset of therapy. The thyroglobulin levels rose from 10.5 ng/dL to 147 ng/dL. Although negative for TRAB, anti-Tg and anti-TPO antibodies were detected at low levels (41 UI/L and 66 UI/L, respectively). The initial CDUS revealed a heterogeneous isoechoic parenchyma and mildly increased vascularization (pattern II), and the glandular volume was 18 g. Three months after the diagnosis of thyrotoxicosis, another examination revealed a hypoechoic parenchyma with increased vascularization (pattern III) and a 14.4% decrease in thyroid volume, which persisted according to CDUS performed two months after the end of therapy.

DISCUSSION

We performed a careful prospective study of 26 HCV-infected patients during IFN α and ribavirin treatment, and only 54% of these patients maintained normal thyroid function, which should alert the clinician to these important potential side effects.

Previous data identified a decrease in FT4 levels within reference values concomitant to a slight reduction in free T3 levels without TSH or thyroglobulin changes during six months of conventional IFN α therapy.⁹ We observed decreases in both TT3 and TT4 levels within 12 months of therapy with conventional and pegylated IFN α in association with ribavirin.

As FT4 and TSH remained stable, we could not attribute such hormonal changes to an IFN α -induced organification defect.¹⁰ The decreases in TT3 and TT4 levels may be related to interleukin-6 (IL-6). Previous studies have reported an increase in IL-6 serum levels with conventional and pegylated IFN α treatments.^{11,12} IL-6 reduces thyroperoxidase mRNA levels and TSH-stimulated thyroid hormone secretion separately from decreasing thyroid hormone binding proteins.¹³ Therefore, IL-6 reduces TT3 without changes in FT4 or TSH levels. Corssmit et al. reported the acute effects of IFN α in healthy volunteers.¹⁴ They observed significant

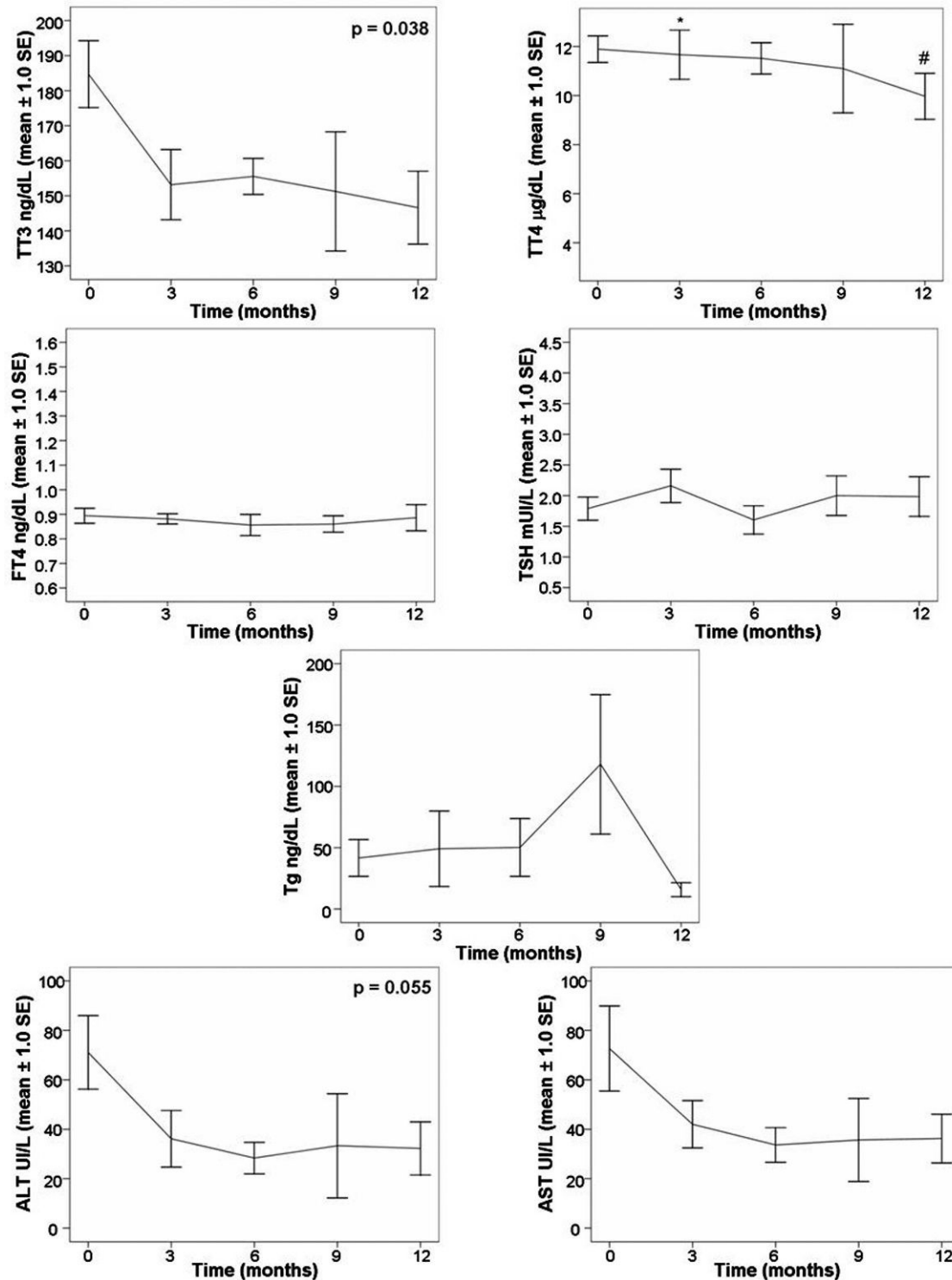


Figure 1 - Hormonal, thyroglobulin, and aminotransferases changes during the 12-month follow-up of 14 HCV-infected patients with normal thyroid function during IFN α and ribavirin treatment. Differences were assessed using Kruskal-Wallis tests. * $p = 0.039$ compared to the initial levels. # $p = 0.008$ compared to the initial levels. Reference values: TT3, 40 to 180 ng/dL; TT4, 4.5 to 12 µg/dL; FT4, 0.7 to 1.5 ng/dL; TSH, 0.4 to 4.5 mIU/L; Tg <55 ng/dL (by fluoroimmunoassay); AST <37 or <31 U/L and ALT <41 or <31 U/L for males or females, respectively.

decreases in TT3 and TSH levels along with an increase in reverse T3 levels without any change in TT4 or FT4 levels. They attributed the hormonal changes to increases in IL-6 levels and interferon-induced cortisol release. Finally, the

decrease in TT3 and TT4 levels during treatment may be related to the improvement of the hepatocellular lesions, as indicated by the reduction in ALT levels. Unfortunately, we did not evaluate thyroxine-binding globulin (TBG) to confirm

Table 1 - The characteristics of the subjects with autoimmune and non-autoimmune interferon-induced thyroiditis and the subjects with no thyroid disorders during interferon-alpha and ribavirin therapy.

	No thyroid disorder (n = 14)	Autoimmune IIT (n = 5)	Non-autoimmune IIT (n = 4)
Time to diagnosis (mo)	-	6.7 ± 3.5	9.9 ± 2.2
Age (years)	44.9 ± 12.7	35.6 ± 10.3	48.5 ± 5.7
Sex (male/female) ^a	8/6	0/5	2/2
HIV	2	1	1
HCV genotype			
1	8	4	2
2	0	0	1
3	6	1	1
IFN α			
Conventional	5	0	1
Pegylated	9	5	3
Duration of therapy (weeks)	33.6 ± 14.2	39.6 ± 9.8	42.0 ± 12.0
Before IFN α :			
TT3 (ng/dL) ^b	184.7 ± 35.8	191.8 ± 27.7	141.8 ± 17.7
TT4 (μ g/dL) ^c	11.9 ± 2.0	13.2 ± 2.5	8.8 ± 0.7
FT4 (ng/dL)	0.9 ± 0.1	0.9 ± 0.1	0.8 ± 0.1
TSH (mUI/L) ^d	1.8 ± 0.7	1.8 ± 1.4	3.1 ± 1.2
CDUS*:			
Heterogeneity (%)	11 (91.7)	5 (100)	3 (75.0)
Hypoechoogenicity (%)	2 (16.7)	1 (20.0)	0 (0)
Glandular volume (g)	12.6 ± 6.8	9.3 ± 2.8	10.6 ± 5.1
Nodules (%)	5 (41.7)	1 (20.0)	1 (25.0)
Vascularization (%)			
I	3 (25.0)	0	0
II	2 (16.7)	1 (25.0)	1 (33.3)
III	7 (58.3)	3 (75.0)	2 (66.7)
Final CDUS*			
Heterogeneity (%)	9 (81.8)	2 (100)	4 (100)
Hypoechoogenicity (%)	2 (18.2)	1 (50.0)	2 (50.0)
Glandular volume (g)	12.7 ± 5.7	12.3 ± 0.7	9.8 ± 4.9
Nodules (%)	4 (36.4)	0 (0)	2 (50.0)
Vascularization (%)			
I	1 (11.1)	0 (0)	0 (0)
II	6 (66.7)	1 (50.0)	1 (25.0)
III	2 (22.2)	1 (50.0)	3 (75.0)

Reference values: TT3, 40 to 180 ng/dL; TT4, 4.5 to 12 μ g/dL; FT4, 0.7 to 1.5 ng/dL; TSH, 0.4 to 4.5 mUI/L (as determined by a fluoroimmunoassay). n, the number of patients; IIT, interferon-induced thyroiditis; IFN α , interferon-alpha; CDUS, thyroid color-flow Doppler ultrasound.

*the frequency based on the number of patients, with the CDUS results showing the indicated parameter.

^ap = 0.045 when comparing the groups with no thyroid disorder and autoimmune IIT.

^bp = 0.018 when comparing the groups with no thyroid disorder and non-autoimmune IIT.

^cp = 0.005 when comparing the groups with no thyroid disorder and non-autoimmune IIT.

^dp = 0.079 when comparing the groups with no thyroid disorder and non-autoimmune IIT.

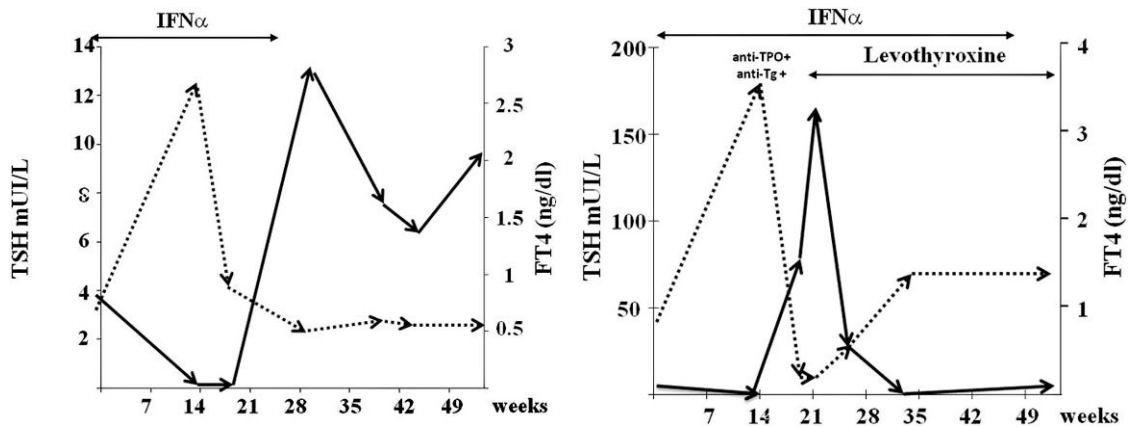


Figure 2 - TSH and FT4 changes during the follow-up of 2 HCV-infected patients with destructive thyroiditis induced by IFN α and ribavirin. Reference values: FT4, 0.7 to 1.5 ng/dL; TSH, 0.4 to 4.5 mUI/L (as determined by a fluoroimmunoassay).

this hypothesis. Previous studies have suggested that TT3 and TT4 levels increase in cases of chronic liver disease in proportion to the severity of the liver dysfunction (due to high TBG levels).^{15,16}

We confirmed the existence of two main forms of IIT (autoimmune and non-autoimmune). The mechanisms involved in autoimmune thyroiditis associated with IFN α have not yet been clarified. IFN α and its receptor activate the JAK-STAT pathway, activating the expression of genes encoding cytokines and adhesion molecules. IFN α also increases the expression of MHC class I antigens, activates cytotoxic T cells, and induces the T helper 1-mediated immune response.⁶ The mean time to the diagnosis of IFN α -induced autoimmune thyroid disturbance was six months, which suggests that longer exposure is required to stimulate immune mechanisms.

The direct effects of IFN α on the thyroid may be responsible for non-autoimmune thyroiditis.⁶ It is possible that HCV itself promotes a local immune response in thyrocytes. In addition, IFN α directly induces thyrocyte death and inhibits TSH-induced gene expression and protein production of Tg, TPO and the sodium iodine symporter,^{17,18} which promote follicular destruction and hypothyroidism. We found a significant increase in thyroglobulin levels within three months of the onset of therapy in the cases of destructive thyroiditis, indicating the direct, acute and destructive effects of IFN α on follicular cells.

One limitation of this study is the small number of patients, especially those who developed IIT. Nevertheless, we were able to identify an association between the female gender and autoimmune IIT, as previously reported in larger populations.^{19,20} Our data support the conclusion that the development of IIT is not related to the type of IFN α (i.e., conventional vs. pegylated).²¹ We are the first to describe an association between reduced pre-treatment levels of TT3 and TT4 and slightly increased TSH levels as predictors of non-autoimmune IIT. We speculate that a smaller thyroid hormone reserve facilitated the hormonal disturbance after a direct cellular lesion caused by IFN α .

The higher frequency (8%) of destructive thyroiditis (compared to previous data)^{7,22} is remarkable. This discrepancy may have occurred because of the early hormonal evaluation that we performed (at three months). CDUS would help to differentiate thyrotoxicosis caused by either destructive thyroiditis or auto-immune thyroiditis (Graves' disease). Unfortunately, Graves' disease was not diagnosed during the IFN α therapy. Our patients with destructive thyroiditis had either mild (pattern II) or marked (pattern III) increases in vascularization. In contrast to amiodarone-induced thyroiditis, we expected that destructive thyroiditis would lead to CDUS patterns of less than II, and autoimmune thyroiditis would lead to pattern III.⁸ Possible explanations for these findings are the use of delayed CDUS exams for diagnosis and the concomitant autoimmune mechanisms that were induced, which were represented by dramatic increases in anti-Tg and anti-TPO antibody levels (case 2). Both of the patients developed rapid thyroid volume shrinkage, which is compatible with destructive lesions. Additional CDUS exams are necessary to define the role of ultrasound in differentiating IFN α -induced thyrotoxicosis.

In summary, treating HCV infections with IFN α and ribavirin induces autoimmune and non-autoimmune thyroiditis and hormonal changes, which are represented by

decreases in TT3 and TT4 levels despite stable levels of FT4 and TSH. Consequently, a thyroid hormonal evaluation, including measurements of FT4, TSH, and antithyroid antibody levels, should be mandatory before therapy. As thyroid disturbances were detected within three months of treatment, we suggest an early hormonal re-evaluation during IFN α treatment. Thus, thyroid disturbances will not remain undiagnosed.

ACKNOWLEDGEMENTS

This study received financial support from *Fundação de Amparo à Pesquisa do Estado de São Paulo* (FAPESP) grant 2006/06080-2.

REFERENCES

1. Antonelli A, Ferri C, Fallahi P, Ferrari SM, Ghinoi A, Rotondi M, et al. Thyroid disorders in chronic hepatitis C virus infection. *Thyroid*. 2006;16:563-72, doi: 10.1089/thy.2006.16.563.
2. Manns MP, McHutchison JG, Gordon SC, Rustgi VK, Shiffman M, Reindollar R, et al. Peginterferon alfa-2b plus ribavirin compared with interferon alfa-2b plus ribavirin for initial treatment of chronic hepatitis C: a randomised trial. *Lancet*. 2001;358:958-65, doi: 10.1016/S0140-6736(01)06102-5.
3. Fried MW, Shiffman ML, Reddy KR, Smith C, Marinos G, Goncalves FL, Jr., et al. Peginterferon alfa-2a plus ribavirin for chronic hepatitis C virus infection. *N Engl J Med*. 2002;347:975-82, doi: 10.1056/NEJMoa020047.
4. de Araujo ES, Campos AF, Yamashiro J, Mello ES, Takagaki T, Barone AA. Expectoration of large bronchial casts secondary to the treatment of chronic hepatitis C with pegylated interferon and ribavirin. *Clinics*. 2010;65:745-8, doi: 10.1590/S1807-5932010000700016.
5. Russo MW, Fried MW. Side effects of therapy for chronic hepatitis C. *Gastroenterology*. 2003;124:1711-9.
6. Tomer Y, Blackard JT, Akeno N. Interferon alpha treatment and thyroid dysfunction. *Endocrinol Metab Clin North Am*. 2007;36:1051-66; x-xi, doi: 10.1016/j.ecl.2007.07.001
7. Mandac JC, Chaudhry S, Sherman KE, Tomer Y. The clinical and physiological spectrum of interferon-alpha induced thyroiditis: toward a new classification. *Hepatology*. 2006;43:661-72, doi: 10.1002/hep.21146.
8. Bogazzi F, Bartalena L, Brogioni S, Mazzeo S, Vitti P, Burelli A, et al. Color flow Doppler sonography rapidly differentiates type I and type II amiodarone-induced thyrotoxicosis. *Thyroid*. 1997;7:541-5, doi: 10.1089/thy.1997.7.541.
9. Del Monte P, Bernasconi D, De Conca V, Randazzo M, Meozzi M, Badaracco B, et al. Endocrine evaluation in patients treated with interferon-alpha for chronic hepatitis C. *Horm Res*. 1995;44:105-9.
10. Roti E, Minelli R, Giuberti T, Marchelli S, Schianchi C, Gardini E, et al. Multiple changes in thyroid function in patients with chronic active HCV hepatitis treated with recombinant interferon-alpha. *Am J Med*. 1996;101:482-7, doi: 10.1016/S0002-9343(96)00259-8.
11. Grungriff K, Reinhold D, Ansong S. Serum concentrations of sIL-2R, IL-6, TGF-beta1, neopterin, and zinc in chronic hepatitis C patients treated with interferon-alpha. *Cytokine*. 1999;11:1076-80, doi: 10.1006/cyto.1999.0504.
12. Falasca K, Mancino P, Ucciferri C, Dalessandro M, Manzoli L, Pizzigallo E, et al. Quality of life, depression, and cytokine patterns in patients with chronic hepatitis C treated with antiviral therapy. *Clin Invest Med*. 2009;32:E212-8.
13. Corssmit EP, de Metz J, Sauerwein HP, Romijn JA. Biologic responses to IFN-alpha administration in humans. *J Interferon Cytokine Res*. 2000;20:1039-47, doi: 10.1089/107999000750053690.
14. Corssmit EP, Heijligenberg R, Hack CE, Ender E, Sauerwein HP, Romijn JA. Effects of interferon-alpha (IFN-alpha) administration on leucocytes in healthy humans. *Clin Exp Immunol*. 1997;107:359-63, doi: 10.1111/j.1365-2249.1997.269-ce1161.x.
15. Borzio M, Caldara R, Borzio F, Piepoli V, Rampini P, Ferrari C. Thyroid function tests in chronic liver disease: evidence for multiple abnormalities despite clinical euthyroidism. *Gut*. 1983;24:631-6, doi: 10.1136/gut.24.7.631.
16. L'Age M, Meinhold H, Wenzel KW, Schleusener H. Relations between serum levels of TSH, TBG, T4, T3, rT3 and various histologically classified chronic liver diseases. *J Endocrinol Invest*. 1980;3:379-83.
17. Caraccio N, Giannini R, Cuccato S, Faviana P, Berti P, Galleri D, et al. Type I interferons modulate the expression of thyroid peroxidase, sodium/iodide symporter, and thyroglobulin genes in primary human thyrocyte cultures. *J Clin Endocrinol Metab*. 2005;90:1156-62, doi: 10.1210/jc.2004-1173.
18. Akeno N, Tomer Y. Dissecting the mechanisms of interferon-induced thyroiditis (IIT): direct effects of interferon alpha on thyroid epithelial cells. In: 89th Annual Meeting of the Endocrine Society, Toronto, Canada, 2007.

19. Gelu-Simeon M, Burlaud A, Young J, Pelletier G, Buffet C. Evolution and predictive factors of thyroid disorder due to interferon alpha in the treatment of hepatitis C. *World J Gastroenterol.* 2009;15:328-33, doi: 10.3748/wjg.15.328.
20. Jamil KM, Leedman PJ, Kontorinis N, Tarquinio L, Nazareth S, McInerney M, et al. Interferon-induced thyroid dysfunction in chronic hepatitis C. *J Gastroenterol Hepatol.* 2009;24:1017-23, doi: 10.1111/j.1440-1746.2008.05690.x.
21. Tran HA, Attia JR, Jones TL, Batey RG. Pegylated interferon-alpha2beta in combination with ribavirin does not aggravate thyroid dysfunction in comparison to regular interferon-alpha2beta in a hepatitis C population: meta-analysis. *J Gastroenterol Hepatol.* 2007;22:472-6, doi: 10.1111/j.1440-1746.2006.04771.x.
22. Wong V, Fu AX, George J, Cheung NW. Thyrotoxicosis induced by alpha-interferon therapy in chronic viral hepatitis. *Clin Endocrinol (Oxf).* 2002;56:793-8, doi: 10.1046/j.1365-2265.2002.01553.x.