

## CLINICAL SCIENCE

---

### SUBCOSTAL MINI INCISION: A GOOD OPTION FOR DONOR NEPHRECTOMY

Hideki Kanashiro, Renato Falci Jr, Affonso Celso Piovisan, Fernando Saito, Fabio Cesar Miranda Torricelli, Willian Carlos Nahas

doi: 10.1590/S1807-59322010000500008

---

Kanashiro H, Falci Jr, R, Piovisan AC, Saito F, Torricelli FCM, Nahas WC. Subcostal mini incision: a good option for donor nephrectomy. Clinics. 2010;65(5):507-10.

**OBJECTIVES:** We describe the results of over one hundred nephrectomies performed using a subcostal mini incision.

**INTRODUCTION:** A major effort has been undertaken to encourage living donor renal transplantation. New techniques that use minimally invasive approaches to perform donor nephrectomy have been progressively accepted. Among these new procedures is the mini-incision approach.

**METHODS:** We prospectively analyzed one hundred and seventeen consecutive donors that were subjected to subcostal mini-incision nephrectomy at a single center. Surgical time, warm and cold ischemia time, intraoperative complications, time until hospital discharge, presence of infection, bleeding, the need for a second operation, and death were analyzed. Eventual loss of donor renal function was indicated by increases in serum creatinine and proteinuria.

**RESULTS:** The mean time of surgery was  $180.5 \pm 26.2$  minutes. The mean warm ischemia time was  $93 \pm 8.3$  seconds, while the mean cold ischemia time was  $85.9 (\pm 23.5)$  minutes. We had one case with an intraoperative complication, and only two patients required another operation. An intra-abdominal abscess occurred in one patient (0.85%), proteinuria occurred in one patient (0.85%), and a transitory increase of creatinine levels occurred in two patients (1.7%).

**DISCUSSION:** Reducing the length of the abdominal incision did not influence surgical time or result in an increase in intraoperative complications relative to our historical data or literature reports. Organ preparation was accomplished successfully with a brief warm ischemia time. Additionally, the mean hospital stay was short, and few surgical complications occurred.

**CONCLUSION:** The use of a subcostal mini incision is both safe and similar to conventional techniques previously described in the literature.

**KEYWORDS:** Transplantation; Kidney; Nephrectomy; Minimally invasive procedures; Living donor transplant.

---

#### INTRODUCTION

End stage renal disease (ESRD) is a major health problem. Over the last few decades, significant improvements have been made with dialysis (equipment and methods) that have helped to steadily increase the life expectancy of patients with ESRD. Consequently, the prevalence of ESRD has also increased.<sup>1</sup>

Renal transplantation is widely accepted as the best

treatment for these patients because it is superior to dialysis in terms of both survival and quality of life. Additionally, it is the most economically attractive option. However, renal donations have not been sufficient to cover the number of ESRD patients that are on the waiting list for a transplant. If the current trends continue, over the next twenty years there will be a five-fold increase in waiting time.<sup>1</sup>

Renal transplantations from a living donor provide better short- and long-term results than transplants from a cadaver. Thus, a major effort has been undertaken to encourage this practice.<sup>2,3</sup> New techniques that use minimally invasive approaches have been progressively accepted. They are less invasive for the donor and require shorter operation times.<sup>4</sup> The new procedures include retroperitoneal and transperitoneal laparoscopic procedures, hand-assisted laparoscopic surgery, and mini-incision approaches.

---

Department of Urology, Faculdade de Medicina da Universidade de São Paulo – São Paulo/SP, Brazil.

Email: hkanashiro@uol.com.br

Tel.: 55 11 5044-0210

Received for publication on January 22, 2010

First review completed on February 22, 2010

Accepted for publication on March 01, 2010

---

In the present study, we describe the results of over one-hundred nephrectomies performed in our center using a subcostal mini incision and compare them to data on lombotomies and laparoscopic approaches from our previous experience and the literature.

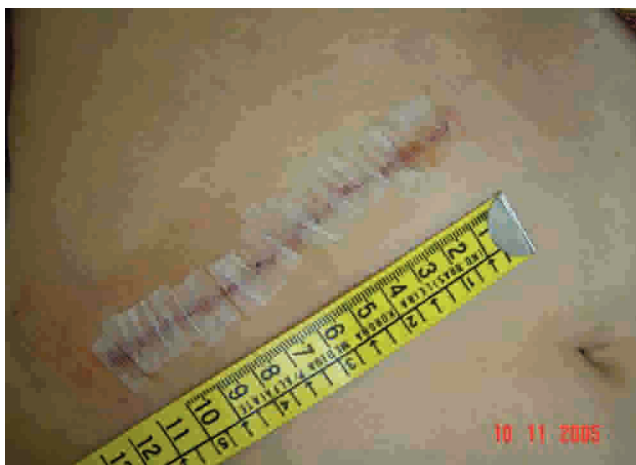## MATERIALS AND METHODS

We prospectively analyzed one hundred and seventeen consecutive donors that were subjected to subcostal mini incision nephrectomy between January 2005 and May 2007 at a single center. The mean age of the patients was  $41.4 \pm 10.1$  years, and 70% were female. The mean body mass index was  $25.6 \pm 2.7$  kg/m<sup>2</sup>. More than half of the patients (55.5%) had a BMI higher than 25 kg/m<sup>2</sup>.

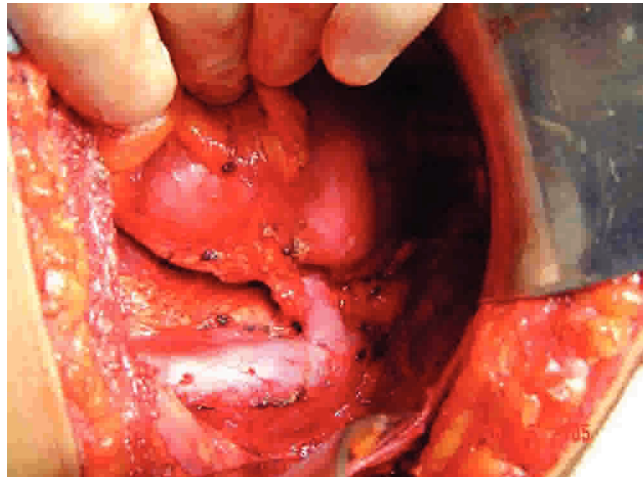
The right kidney was more frequently used than the left (64.9% versus 35.1%, respectively), leaving the best kidney with the donor. Most donors were related to the recipients (87 out of 117 or 86.3%).

The patients were positioned in a horizontal dorsal position with an inclination of 30 degrees above the surgical bed. A small mini incision of 10 cm was made on the skin about 3 cm below the last costal arch in the right flank (Figure 1). Subcutaneous soft tissues were dissected until the muscle layers were found. The external oblique, internal oblique, and transverse muscles were cut. If the right kidney was chosen, transperitoneal access was used; if the left kidney was chosen, retroperitoneal access was used. We used a regular orthostatic retractor in all cases. The dissection was performed first on the ureter, preserving periureteral fat, followed by dissection of the renal vein, artery, and upper pole (Figure 2).

In procedures involving the right kidney, the renal vein was cut near its insertion in the lower cava vein, and a direct 4-0 polypropylene suture was used for vena cava repair. On



**Figure 1** - The mini subcostal approach for donor nephrectomy: An incision of 10 cm is made about 3 cm below the last costal arch in the right flank.



**Figure 2** - Hilar dissection of the right kidney through a mini subcostal incision: Optimal exposition of the vena cava and renal vessels.

the left side, the vessels were ligated near their insertion.

Surgical time, the presence of anatomical variations, warm and cold ischemia time, and intraoperative complications were all analyzed. A postoperative evaluation was made and immediate and late surgical complications such as infection, bleeding, the need for a second operation, and death were reported. Eventual loss of donor renal function was indicated by increases in serum creatinine and proteinuria.

## RESULTS

The mean time of surgery was  $180.5 \pm 26.2$  minutes. The mean warm ischemia time was  $93 \pm 8.3$  seconds, while the mean cold ischemia time was  $85.9 \pm 23.5$  minutes. The most common anatomical variation that we observed was the presence of two renal arteries, which occurred in 11% of patients. We also observed other variations, including the presence of two renal veins (2.5%), three renal veins (1.7%), three renal arteries (< 1%), two ureters (< 1%), or a retroaortic renal vein (< 1%). The most common length of stay in the hospital before discharge was three days.

No deaths associated with nephrectomy occurred among the donors. We had one case with an intraoperative complication involving a hepatic laceration due to epiploon adherence. This patient evolved uneventfully in the postoperative time.

Only two patients required another operation, both for gonadal vein bleeding. An intra-abdominal abscess occurred in one patient (0.85%). No further cases of infection were observed.

After being discharged, proteinuria occurred in one patient (0.85%) and a transitory increase of creatinine levels occurred in two patients (1.70%).

## DISCUSSION

Since the introduction of laparoscopic nephrectomy for transplantation in 1995, its safety has been under discussion.<sup>5-11</sup> Many authors have compared the laparoscopic option to open nephrectomy in living donors. The major disadvantages of this technique include increases in both cold and warm ischemia time and prolonged surgery<sup>12,14</sup>. Other limitations of laparoscopy are the limited access to adequate equipment in developing countries, higher costs, more technical difficulties, and the learning curve necessary for this procedure.

Some studies reported good results with the laparoscopic approach. However, the surgeons conducting the surgery had great expertise using this technique for nephrectomies.<sup>7,8</sup> Therefore, the best results may not be reproducible at centers without staff who have previous experience with laparoscopy.

In 2004, we published our initial study of fifteen videolaparoscopic left nephrectomies using live renal donors. The mean surgical time was 179.5 minutes, and the warm ischemia time of the graft was 3.79 minutes. The mean estimated bleeding was 141 mL. There was no need for a blood transfusion or conversion to open surgery. Opioids were required for analgesia in only two cases. On average, 3.1 doses of dipyrone were used for each patient during the hospital stay, and hospital discharge occurred 3.2 days after the operation. Two patients required re-operations, and one of them eventually died.<sup>13</sup>

The use of mini incision nephrectomy is a safe option for the standard urologist. It has no limitations regarding equipment, and it is less invasive than conventional nephrectomy.<sup>14</sup> Comparing this initial experience with

mini incision nephrectomy with our previous laparoscopic nephrectomy data, there was no significant difference in either surgical time or length of hospital stay.<sup>13</sup> In the subcostal nephrectomy group, both the warm ischemia time and incidence of re-operations were lower, and no major complications or death occurred.

Aguiar et al. compared subcostal mini-incision to lombotomy mini-incision and concluded that both are safe and that neither offers a clear advantage over the other<sup>15</sup>. Other studies have compared mini-incision open nephrectomy to laparoscopic access, demonstrating comparable safety with both procedures.<sup>15,17,18</sup> In terms of cost, previous studies have demonstrated that a subcostal mini incision costs less than a laparoscopy.<sup>19</sup>

In our study, reducing the length of the abdominal incision did not influence surgical time or result in an increase in intraoperative complications. Even with the presence of anatomical variations, neither an enlarged incision nor a change in surgical access was needed because the organ preparation could be accomplished successfully with brief warm and cold ischemia times. Additionally, the mean hospital stay was short, and few surgical complications occurred.

## CONCLUSIONS

The use of a subcostal mini-incision is both safe and similar to conventional techniques previously described in the literature. This type of procedure may be associated with reduced surgical trauma, which in turn leads to a shorter hospital stay, an earlier return to normal activities, and reduced morbidity and mortality. Additionally, the risk of complications proved to be low.

## REFERENCES

1. Ratner LE. Report Card on Living Kidney Donation. *Am J Transpl.* 2003;3:830-4.
2. Ingelfinger JR. Risks and Benefits to the Living Donor. *N Engl J Med.* 2005;353:447-9.
3. Najarian JS, Chavers BM, McHugh LE, Matas AJ. Twenty years or more of follow-up of living kidney donors. *Lancet.* 1992;340:807-10.
4. Lind MY, Liem YS, Bemelman WA, Dooper PM, Hop WC, Weimar W, et al. Live donor nephrectomy and return to work: does the operative technique matter? *Surg Endosc.* 2003;17:591-5.
5. Ratner LE, Ciseck LJ, Moore RG, Cigarroa FG, Kaufman HS, Kavoussi LR. Laparoscopic live donor nephrectomy. *Transplantation.* 1995;60:1047-9.
6. Øyen O, Andersen M, Mathisen L, Kvarstein G, Edwin B, Line PD, et al. Laparoscopic versus open living-donor nephrectomy: experiences from a prospective, randomized, single-center study focusing on donor safety. *Transplantation.* 2005;79:1236-40.
7. Simforoosh N, Basiri A, Tabibi A, Shakhssalim N and Seyed M.M. Comparison of laparoscopic and open donor nephrectomy: a randomized controlled trial. *BJU Int.* 2005; 95:851-5.
8. Wilson CH, Bhatti AA, Rix DA, Soomro NA. Comparison of laparoscopic and open donor nephrectomy: UK experience. *BJU Int.* 2005; 95:131-5.
9. Azeka E, Auler Júnior JO, Fernandes PM, Nahas WC, Fiorelli AI, Tannuri U, et al. Registry of Hospital das Clínicas of the University of São Paulo Medical School: first official solid organ and tissue transplantation report – 2008. *Clinics.* 2009;64:127-34.
10. Mitre AI, Dénes FT, Nahas WC, Simões FA, Colombo JR Jr, Piovesan AC, et al. Comparative and prospective analysis of three different approaches for live-donor nephrectomy. *Clinics.* 2009;64:23-8.

11. Branco AW, Kondo W, Branco Filho AJ, George MA, Rangel M, Stunitz LC. A comparison of hand-assisted and pure laparoscopic techniques in live donor nephrectomy. *Clinics*. 2008 Dec;63:795-800.
12. Power RE, Preston JM, Griffin A, Martin I, Wall DR, Nicol DL. Laparoscopic vs open living donor nephrectomy: a contemporary series from one centre. *BJU Int*. 2006;98:133-6.
13. Mitre AI, Denes FT, Piovesan AC, Simoes FA, Castilho LN, Arap S. Laparoscopic nephrectomy in live donor. *Int Braz J Urol*. 2004;30:22-8.
14. Neipp M, Jackobs S, Becker T, zu Vilsendorf AM, Winny M, Lueck R, et al. Living donor nephrectomy: flank incision versus anterior vertical mini incision. *Transplantation*. 2004;78:1356-61.
15. Lewis GRR, Brook NR, Waller JR, Bains JC, Veitch PS, Nicholson ML. A comparison of traditional open, minimal-incision donor nephrectomy and laparoscopic donor nephrectomy. *Tranpl Intl*. 2004;17:589-95.
16. Aguiar WF, Passerotti CC, Claro JFA, Almeida CJR, Gattas N, Cedenho AP, et al. Mini-incisions by lombotomy or subcostal access in living kidney donors: a randomized trial comparing pain, safety, and quality of life. *Clin Transplant*. 2007;21:269-76.
17. Greenstein MA, Harkaway R, Badosa F, Ginsberg P, Yang SL. Minimal incision living donor nephrectomy compared to the hand-assisted laparoscopic living donor nephrectomy. *World J Urol*. 2003;20:356-9.
18. Majeed AW, Troy G, Nicholl JP, Smythe A, Reed MW, Stoddard CJ, et al. Randomised, prospective, single-blind comparison of laparoscopic versus small-incision cholecystectomy. *Lancet*. 1996;347:989-94.
19. Wolf JS Jr, Marcovich R, Merion RM, Konnak JW. Prospective, case matched comparison of hand assisted laparoscopic and open surgical live donor nephrectomy. *J Urol*. 2000;163:1650-3.