



## ORIGINAL PAPER

# [Translated article] Improvement of survival after 10 years with the Durom-type hip resurfacing prosthesis in selected patients: Experience of a public university hospital

F. Marqués López\*, M. Cuenca Llavall, C. Mestre Cortadellas, M. Tey Pons, A. León García

Unidad de Cadera, Parc de Salut Mar, Universidad Autónoma de Barcelona, Barcelona, Spain

Received 22 June 2021; accepted 7 September 2021

Available online 24 March 2022

### KEYWORDS

Hip resurfacing;  
Hip arthroplasty;  
Durom system;  
Metal-on-metal;  
Survivorship;  
Young patients

### Abstract

**Introduction:** Hip resurfacing arthroplastys are a valid alternative for the treatment of degenerative hip disorders in young adults. Poor results and adverse soft tissue effects have been reported with high levels of chromium and cobalt, limiting its indications. Objective is to analyse clinical and functional survival results of the Durom system 10 years after its implementation in a public hospital. The hypothesis is that better results and survival are obtained in patients selected according to FDA criteria.

**Material and methods:** Retrospective cohort study of 83 patients, 91 hips in 76 men and 7 women operated between 2005 and 2013 with Durom-type prostheses. Demographic study, diagnosis, BMI, radiological study, serum chromium cobalt levels, functional assessment according to MPD and HSS, complications and survival at 10 years of follow-up. A cohort of active men under 65 years of age and heads over 48 mm is selected.

**Results:** Follow-up time of 121 months with a range from 84 to 176 months. With a mean age of 52.78 years, with 4 deaths and loss of follow-up of 3 cases. There are 12 complications that require reoperation (14.45%) with 2 chronic infections, 4 femoral neck fractures, 4 acetabular loosening and 2 cases of pseudotumors. With an overall survival of 85.4% (71–91.9) and 87.85% (85.5–91.1) in the absence of infection. No statistical relationship between complications and neck narrowing and the angles of inclination of the components. In selected patients, 69 men and 73 hips, we obtained an overall survival of 91.82% and excluding infection of 93.18% at 10 years.

**Conclusions:** The indication of the Durom system in the treatment of degenerative processes in selected active young patients presents better results and survival at 10 years, although somewhat lower than other highly indicated veneering models.

© 2021 SECOT. Published by Elsevier España, S.L.U. This is an open access article under the CC BY-NC-ND license (<http://creativecommons.org/licenses/by-nc-nd/4.0/>).

DOI of original article: <https://doi.org/10.1016/j.recot.2021.09.006>

\* Corresponding author.

E-mail address: [88797@parcdesalutmar.cat](mailto:88797@parcdesalutmar.cat) (F. Marqués López).

<https://doi.org/10.1016/j.recot.2021.09.015>

1888-4415/© 2021 SECOT. Published by Elsevier España, S.L.U. This is an open access article under the CC BY-NC-ND license (<http://creativecommons.org/licenses/by-nc-nd/4.0/>).

**PALABRAS CLAVE**

Prótesis de recubrimiento;  
Artroplastia cadera;  
Sistema Durom;  
Metal-metal;  
Supervivencia;  
Pacientes jóvenes

## Mejoría de la supervivencia a los 10 años con la prótesis de recubrimiento de cadera tipo Durom en pacientes seleccionados. Experiencia de un hospital público universitario

**Resumen**

**Introducción:** Las prótesis de recubrimiento son una alternativa válida para el tratamiento de los trastornos degenerativos de cadera del adulto joven, pero han sido reportados malos resultados y efectos adversos en partes blandas con niveles altos de cromo y cobalto, limitándose sus indicaciones. Nuestro objetivo es analizar resultados clínicos, funcionales y de supervivencia del modelo Durom a los 10 años de su implantación en un hospital público. La hipótesis es que se obtienen mejores resultados y supervivencia en pacientes seleccionados según criterios de la FDA.

**Material y métodos:** Estudio retrospectivo de cohortes con 83 pacientes —91 caderas en 76 hombres y 7 mujeres— operados entre 2005 y 2013 con prótesis tipo Durom. Estudio demográfico, diagnóstico, IMC, radiológico con posición de implantes, estrechamiento del cuello y tipo de unión ósea, niveles de cromo y cobalto en suero, valoración funcional según MPD y HSS, complicaciones y supervivencia a los 10 años de seguimiento. Se selecciona una cohorte de varones activos menores de 65 años y cabezas superiores a 48 mm para la misma valoración.

**Resultados:** El tiempo de seguimiento fue de 121 meses, con un rango de 84 a 176 meses. La edad media fue de 52,78 años, con 4 defunciones y pérdida de seguimiento de 3 casos. Se producen 12 complicaciones que precisan reintervención (14,45%) con 2 infecciones crónicas, 4 fracturas del cuello femoral, 4 aflojamientos acetabulares y 2 casos de pseudotumores. La supervivencia global fue del 85,4% (71-91,9), y del 87,85% (85,5-91,1) en ausencia de infección a los 10 años. No hubo relación estadística entre las complicaciones y el estrechamiento de cuello y los ángulos de inclinación de los componentes. En pacientes seleccionados —69 hombres y 73 caderas— obtenemos una supervivencia global del 91,82% y, excluyendo la infección, del 93,18% a los 10 años.

**Conclusiones:** La indicación del sistema Durom en el tratamiento de procesos degenerativos de los pacientes jóvenes activos seleccionados presenta mejores resultados y supervivencia a los 10 años, aunque algo inferior a otros modelos de recubrimiento muy indicados.

© 2021 SECOT. Publicado por Elsevier España, S.L.U. Este es un artículo Open Access bajo la licencia CC BY-NC-ND (<http://creativecommons.org/licenses/by-nc-nd/4.0/>).

**Introduction**

Metal-on-metal resurfacing prostheses have been a valid alternative for arthroplasty treatment of degenerative hip disease, especially in young active male patients.<sup>1</sup> The wide range of motion, the absence of dislocations and their great tribological advantages have been highlighted.<sup>1</sup> However, the health alert raised by functional adverse effects and soft tissue disturbances (pseudotumours) with high serum chromium and cobalt levels, with perivascular lymphocytic infiltrates in anatomopathological studies (ALVAL), especially in women,<sup>1</sup> have limited the indication for this type of arthroplasty, making patient selection very important. Overall, the results reported in the literature depend on the model of resurfacing arthroplasty and the demographics of the population in which it is implanted, according to the 2016 Australian Registry.<sup>2</sup> In 2005, the Durom-type resurfacing prosthesis and its MMC version (Zimmer-Biomet, Warsaw, IN, USA) were introduced in the orthopaedic surgery and traumatology department of the Parc de Salut Mar of the Autonomous University of Barcelona (Fig. 1). In 2016, the US Food and Drug Administration (FDA) set limited indications for resurfacing arthroplasty and selected only 2 approved models,<sup>3</sup>

Birmingham Hip Resurfacing by Smith & Nephew and Conserve Plus Micropore.

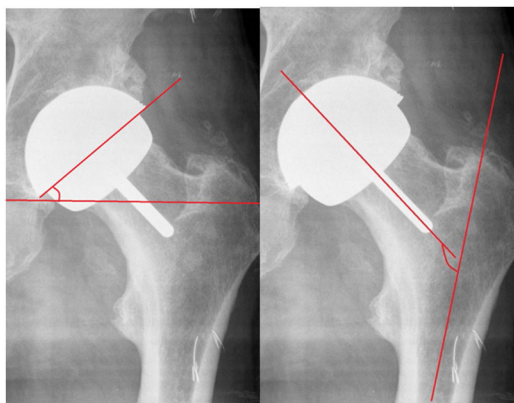
The aim of the present study is to analyse the results, complications and 10-year survival of this type of implant. Our hypothesis is that better results and survival are obtained in patients selected according to FDA criteria.

**Material and methods**

This is a retrospective cohort study of patients who underwent surgery in our centre with a total resurfacing prosthesis using the Durom model and its MMC Cup version in the period from 2005 to 2013 with a follow-up of 84 to 176 months, and a mean of 121 months. We conducted a demographic study, including diagnosis, body mass index, complications, reinterventions, and implant survival. Functional assessment according to the Merle Postel D'Aubigné and Harris Hip Score scale, radiological assessment with PACS, evaluating: acetabular and femoral component position in frontal and axial projections (Fig. 2), radiolucencies in the Lee and Charnley areas of the cup; radiolucencies in the stem area according to the method of Pollard et al.,<sup>4</sup> neck narrowing according to the scale of Spencer et al.<sup>5</sup> at 3 months (Fig. 3), and horizontal offset variation. Engh's score was



**Figure 1** Durom system and the MMC version (with the permission of Zimmer Biomet).

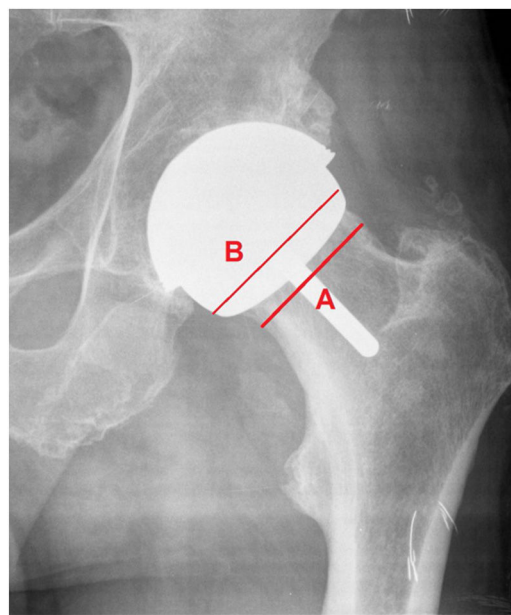


**Figure 2** Positions of the components in the frontal plane.

used for cup osseointegration (union, stable fibrous union, non-union) and Brooker's score for periarticular calcifications. Blood chromium and cobalt levels were measured annually in a laboratory validated for the general population. We also studied survival and complications in the cohort of patients to which the FDA criteria for the indication of this type of implant were applied: active males aged less than 60 years and femoral heads greater than 48 mm.<sup>6-8</sup>

### Durom and MMC cup

Hemispherical titanium vanadium vacuum and plasma sprayed hemispherical press-fit cup with an angle of 165° (less than a 1.5 mm hemisphere), flattened at the pole with a Metasul interior with equatorial grooves to increase the primary press-fit, and whose MMC version adds 3 longitudinal grooves removing the equatorial groove.



**Figure 3** Calculation of neck narrowing (A/B ratio).

The femoral component was designed to be cemented with an alignment stem with recesses for cement extrusion to achieve a layer of 3 mm to 4 mm, is sized in 2 mm increments, and is 6 mm less than the acetabular component.

This implant was no longer marketed in 2013, and therefore no longer implanted in our department, and the indication for resurfacing prosthesis was discontinued, but clinical controls continue to date.

A modified lateral approach of Hardinge was used in all cases and antibiotic prophylaxis with cefazolin was used, or vancomycin in allergic patients. The indications for the specific technique previously used in cadavers were followed and a visit was made to a surgeon who was an expert in this technique and implanted using the same approach.

Antithrombotic prophylaxis was administered with enoxaparin during the first postoperative month, and no prophylaxis with indomethacin for periarticular calcifications was administered. The patient was allowed to sit at 24 h and underwent gait re-education partially weight-bearing with 2 crutches, with outpatient controls at one month, 3 and 6 months, one year and, thereafter, every two years. In cases of loss to follow-up, the shared clinical history of Catalonia was used, with access to clinical data and complementary examinations. All patients underwent serum analysis to determine chromium and cobalt levels, renal function, and CRP annually. Ultrasound and magnetic resonance imaging (MRI) with metal artefact attenuation software were performed in cases of unexplained pain and suspected pseudotumour.

Survival was calculated according to the Kaplan-Meier method, with revision pending or revision performed for any reason at the end of follow-up.

SPSS (version 14, SPSS Inc., Chicago, IL, USA) was used for the statistical analysis. Differences between pre- and postoperative data for functional scales and radiographic parameters were analysed with the Student's t-test for normal distribution, and the data based on means and SD.

## Results

We obtained a cohort of 83 patients, 91 hips in 76 men and 7 women, 43 right, 40 left and 8 bilateral, with a mean age of  $52.78 \pm 8$  years, and a body mass index of 28.42. The surgery was performed by 3 surgeons with expertise in hip surgery.

Indications: 69 hips for osteoarthritis, 21 for sequelae of AVN, and one case for proximal femoral deformity, not indicated in sequelae of dysplasia.

At the end of follow-up there had been 4 deaths (one due to AMI and 3 due to neoplasia) and 3 patients were lost to follow-up, resulting in a final cohort of 76 patients with 82 operated hips in 69 men and 7 women, with a mean follow-up of 121 months.

The mean functional assessment (Merle Postel D'Aubigné) preoperatively was 13.56, and 17.5 and 17.44 at 5 and 10 years, respectively, with statistically significant differences. The mean preoperative Harris Hip Score was  $57.9 \pm 12$  and the postoperative HHS at the end of follow-up was  $96.3 \pm 5.9$ , equally significant, which was maintained at the end of follow-up.

The mean acetabular diameter was  $56 \pm 3$  mm (65–52) and head diameter was  $50 \pm 3$  mm (56–42).

The mean acetabular angle obtained was  $38.42 \pm 8.05$  and femoral angle was  $143.54 \pm 8.2$ , pre- and postoperative offset ratio of .94. Neck narrowing was observed in 7 cases (8.53%) in the first 3 months, remaining stable over time, and type II calcifications in 3 cases (3.65%).

Radiolucencies were observed in Lee and Charnley zone I in 2 cases, in zone II in 3 cases, and in both zones in 2 cases. A sclerotic line was detected at the tip of the femoral stem (type I pedestal sign) in 8 patients, with no radiolucency observed in the entire periphery of the stem (type III). Following Engh's score, 78 integrated cotyles, no stable fibrous union and 4 cases of loosening were obtained. Mean serum chromium and cobalt levels were  $.87 \mu\text{g/l}$  (.55–1.1) and  $.23 \mu\text{g/l}$  (.15–.29), respectively (Table 1), the normal reference in our laboratory (Catalonia reference) being lower than 2 for cobalt and lower than 4.6 for chromium.

After 10 years we have 76 patients and 82 hips with 12 complications (14.45%) and reinterventions, with 2 chronic infections, 4 femoral neck fractures, 4 aseptic acetabular loosening, and 2 cases of painful prosthesis and pseudotumour with normal chromium and cobalt levels: 1.1/.13 and .5/.17, respectively (Table 2). Overall survival was 85.54% (95% CI 71.1–91.9) and 87.85% (95% CI 85.5–91.1) in the absence of infection. Minor complications not requiring intervention included one case of trochanteric pain, one case of neurapraxia of the external popliteal sciatic nerve, which resolved spontaneously, and one case of persistent Trendelenburg gait.

It is important to note that of the 4 subcapital fractures, 2 occurred in women aged 65 and 53 years, respectively, with heads of 52 mm and 44 mm, in the first and second month after implantation. Of the 4 cases of acetabular loosening, one occurred in a 55-year-old male at 3 months after implantation, and of the other 2, one case was noteworthy in a 60-year-old female at 9 weeks.

Statistical analysis showed no relationship between complications and neck narrowing and angles of inclination of the prosthetic components.

After applying the FDA criteria (active males under 60 years of age with heads greater than 48 mm), we obtained a cohort of 73 hips in 69 men. Six complications requiring rescue were obtained: one infection, one fracture, one pseudotumour, and three cases of acetabular loosening (one of them already referred to above, at 3 months), and we obtained an overall survival rate of 91.82% and a survival rate excluding infection of 93.18% at 10 years (Table 3).

## Discussion

The poor results obtained in young patients when conventional hip prostheses with metal-to-metal friction torque and non-crosslinked-polyethylene were indicated were the reason for the resurgence of resurfacing prostheses.<sup>9</sup> These prostheses had tribological advantages, with the use of the metal-to-metal friction torque, with better bone preservation and good functional outcomes, and in meeting patient expectations.<sup>9–11</sup>

Resurfacing prostheses are technically demanding, with a recognised learning curve, and require correct patient selection and preoperative planning.<sup>10</sup>

In some published series the current failure rate is much higher than expected. The figures are worrying, therefore, in national registries of major arthroplasties.<sup>2,3,7</sup>

The most frequent complications described are fixation failure of the acetabular component, subcapital fracture and abnormal reactions to high serum chromium and cobalt levels that cause an ALVAL-type tissue response and pseudotumours.<sup>2,12,13</sup>

In 2010, the Spanish Agency of Medicines and Medical Devices and other international agencies issued a health alert regarding the use of the ASR model (DePuy Johnson & Johnson, Warsaw, In, USA), due to the high rate of mechanical failure and elevated levels of serum chromium and cobalt metal ions with toxic implications, and warned of the high number of wear particles in periarticular tissues. The Australian Registry<sup>2</sup> reported a 10-year revision rate of 7% with the use of this type of implant, a rate that is considered unacceptable.

The Durom resurfacing prosthesis was designed by Grigoris et al.<sup>14</sup> in 2000 and brought to the Spanish market in 2001, and was modified and replaced by the MMC model in 2009, both of which were withdrawn from the market in 2013.

There are few studies on the implantation of resurfacing prostheses using a modified lateral approach of Hardinge as indicated by Delgado en 2009,<sup>15</sup> and the only reference using the Durom model and this approach is by Gravius et al.,<sup>16</sup> with good functional results without Trendelenburg gait and with good survival, although with a short follow-up.

Neck narrowing occurred in 7 cases (8.53%) in our series, low compared to other series reporting up to 25%.<sup>5</sup> No statistically significant association with mechanical complications was found, consistent with other studies.<sup>5,9</sup> This phenomenon has not been explained, possibly related to biomechanical changes or circulation disorders, as they are more frequently described after posterior approaches,<sup>17,18</sup> which would explain the low frequency with our lateral approach.

**Table 1** Series.

N = 82	Mean	Standard deviation	Maximum	Minimum
Age, years	52.78	±8.96	65	16
Follow-up time, months	121	±1.2	176	84
PMA	17.4	±1.2	13	18
HSS	96.3	±1765.9	100	72
Acetabular diameter, mm	56	±3	64	52
Head diameter, mm	50	±3	56	42
Cervico-diaphyseal angle, grade	143.44	±8.79	162	124
Acetabular angle, grade	38.48	±7.9	58	24
Serum chromium	.87	±.43	2.10	.28
Serum cobalt	.23	±.14	.94	.01

**Table 2** Complications at 10 years.

Subcapital fracture	Chronic infections	Acetabular loosening	Painful prosthesis pseudotumour	Reinterventions
4	2	4	2	12 (14.45%)

**Table 3** Complications at 10 years of the group selected by the Food and Drug Administration.

Subcapital fracture	Chronic infections	Acetabular loosening	Painful prosthesis pseudotumour	Reinterventions
1	1	3	1	6 (8.21%)

In our series we reported a 5-year mechanical failure rate of the Durom cup of 3.3%, with a survival of 96.7% in the absence of infection and at 10 years of 87.85%, which contrasts with the 2010 results of Long et al.<sup>19</sup> of 11% failure, and of Migaud et al.<sup>20</sup> in 2012 of 6%, compared with Venditoli et al.<sup>21</sup> with 0% in 2007, and Grigoris et al.<sup>14</sup> with .05% in 2006. Data from the Australian Registry report that the Durom model has a cumulative revision rate at 5 years of 6.7%,<sup>22</sup> with poor outcomes.

On analysis of mechanical complications at 10 years, we observe 4 subcapital fractures in 3 women and 1 man, 2 of which occurred within the first 3 months, at the ages of 56 and 63 years; we also observed 4 acetabular loosening in 3 men and 1 woman, and 2 of these occurred within the first 3 months of implantation, at the ages of 56 and 60 years. These data indicate, on the one hand, poor patient selection (women over 55 years of age), and on the other, a learning curve for the procedure, as indicated by many studies using the same implant.<sup>16,21,23</sup> Regarding the remaining complications that required intervention, we had 2 chronic infections that required replacement in 2 stages and that were finally cured according to the standards for prosthetic hip infection in our department for patients in that age range.

Two cases of pseudotumour and painful prosthesis (2.4%) were detected at 6 and 9 years, respectively, by ultrasound and MRI with metal artefact attenuation. No significantly high chromium and cobalt levels were detected in these two cases. They were replaced with conventional hip prostheses with a polyethylene ceramic torque, with good results. Our incidence of pseudotumours is lower compared to the 3.3% for large cysts and 8.3% for small cysts described by

Robinson et al.<sup>24</sup> and the reported incidence of 16.5 and 10.6% for cysts larger than 1 cm. This could be because we only performed ultrasound and MRI in cases of suspicion due to pain and other symptoms (limitation of the study).

In a previous study by the same group (Cuenca et al.<sup>25</sup>), a relationship was found between chromium levels and the greater angle of position in the frontal plane of the femoral component with functional results, with significant differences being observed with angles greater than 143°.

The overall survival of our series of 85.54% at 10 years is lower than expected when compared to conventional primary arthroplasty series, which exceed 93% in most studies.<sup>6,7,26,27</sup>

In 2014 and 2017, the National Institute for Health and Care Excellence recommended the use of resurfacing prostheses to treat osteoarthritis of the hip if a revision rate of less than 5% was achieved at 10 years with the prosthetic models reported, advising their indication in young males. The FDA<sup>8</sup> accepted only 2 prosthetic models, the Birmingham Hip Resurfacing (Smith & Nephew) being the most widely used in the American market in active male patients under 60 years of age with femoral heads over 48 mm.

Once our cohort of patients was selected according to these criteria, we obtained an overall all-cause survival of 91.82% and 93.18% if infection was ruled out, below expectations, with a good functional outcome according to the scales used (Merle Postel D'Aubigné and Harris Hip Score), with chromium and cobalt levels not significantly above the reference values, which contrasts with other studies with worse survival rates, such as that of Naal et al.,<sup>28</sup> at 88.2% with the same implant, and Seppanen et al.,<sup>29</sup> with a survival

rate of 72%. The most frequent complication is mechanical loosening of the acetabular component, as emphasised by Long et al.<sup>19</sup>

If we compare survival in patients selected according to the same criteria, but using the Birmingham hip resurfacing implant, we obtain better survival rates, such as that shown by Ford et al.,<sup>3</sup> of 98.2% at 10 years, and that of Van der Straeten,<sup>30</sup> of 95% at 10 years and 90% at 22 years, excluding arthroplasties with the ASR and CORMET devices.

In the same work by Van der Straten,<sup>30</sup> survival in men is 99% at 10 years and 92.5% at 21 years, whereas in women it is 90% and 81.3%, respectively.

The limitations of the study include its retrospective nature, the inclusion of all cases (learning curve) with some early complications that would be avoidable with greater experience in implantation, and the performance of MRI and ultrasound scans only in suspected cases of pseudotumour or local soft tissue complication due to symptoms, and not being able to rule out detection of these abnormal reactions in asymptomatic patients.

In conclusion, we believe that the use of the Durom/MMC resurfacing system for the treatment of degenerative processes in selected patients (active men under 60 years of age), and once the learning curve has been completed, shows better results, with good survival. However, results are inferior to those of other resurfacing models on the market, and this highlights the problems of acetabular fixation.

## Level of evidence

Level of evidence IV.

## Conflict of interests

The authors have no conflict of interests to declare.

## Funding

The authors declare that they have received no funding for the conduct of the present research, the preparation of the article, or its publication.

## References

- Pandit H, Glyn-Jones S, McLardy-Smith P, Gundle R, Whitwell D, Gibbons CL, et al. Pseudotumors associated with metal-on-metal hip resurfacings. *J Bone Joint Surg Br.* 2008;90:847–51.
- Australian Orthopaedic Association National Joint Replacement Registry. Annual report 2016. Adelaide: AOANJRR; 2016. Available at: <https://aoanjrr.sahmri.com/en/annual-reports-2016> [accessed 12.06.18].
- Ford M, Hellman M, Kazarian G, Clohisy J, Ryan M, Nunley R, et al. Five to ten-year results of the Birmingham Hip Resurfacing Implant in the U.S.: a single institution's experience. *J Bone Joint Surg Am.* 2018;100:1879–87.
- Pollard TC, Baker RP, Eastaugh-Waring SJ, Bannister GC. Treatment of the young active patients with osteoarthritis of the hip. A five- to seven-year comparison of hybrid total hip arthroplasty and metal-on-metal resurfacing. *J Bone Joint Surg Br.* 2006;88:592–600.
- Spencer S, Carter R, Murray H, Meek R. Femoral neck narrowing after metal-on-metal hip resurfacing. *J Arthroplasty.* 2008;23:1105–9.
- Mehra A, Berryman F, Matharu G, Pynsent P, Isbister E. Birmingham hip resurfacing: a single surgeon series reported at a minimum of 10 years follow up. *J Arthroplasty.* 2015;30:1160–6.
- Haddad F, Konan S, Tahmassebi J. A prospective comparative study of cementless total hip arthroplasty and hip resurfacing in patients under the age of 55 years. *Bone Joint J.* 2015;97B:617–22.
- U.S. Food and Drug Administration. Information for orthopaedic surgeons. Silver Springs: FDA; 2019.
- Grigoris P, Roberts P, Bosch H. The evolution of hip resurfacing arthroplasty. *Orthop Clin North Am.* 2005;36:125–34.
- Amstutz H, Beaulé P, Dorey F, Le Duff M, Campbell P, Gruen T. Metal on metal hybrid surface arthroplasty: two to six year follow up study. *Bone Joint Surg Am.* 2004;86:28–39.
- Triclot P. Metal on metal: history, state of the art (2010). *Int Orthop.* 2011;35:201–6.
- Morlock M, Bishop N, Rutler W, Delling G, Hahn N. Biomechanical, morphological and histological studies of early failures in hip resurfacing arthroplasty. *Proc Inst Mech Eng H.* 2006;220:333–43.
- Gallart X, Riba J, Fernández-Valencia J, Bori J, Muñoz-Mahamud E, Combalia A. La prótesis de cadera en el adulto joven. Prótesis de superficie y prótesis de vástago corto. *Rev Esp Cir Ortop Traumatol.* 2018;62:142–52.
- Grigoris P, Roberts P, Panousis K. The development of the Durom metal-on-metal hip resurfacing. *Hip Int.* 2006;16:65–72.
- Delgado A. Abrodajes quirúrgicos en la artroplastia de superficie de cadera. *Rev Esp Cir Ortop Traumatol.* 2009;53:398–404.
- Gravius S, Wirtz D, Maus U, Andereya S, Muller-Rath R, Mumme T. Durom hip resurfacing arthroplasty: first clinical experiences with lateral approach. *Z Orthop Unfall.* 2007;145:461–7.
- Amarasekera H, Costa M, Foguet P, Krikler S, Prakash U, Griffin D. The blood flow to the femoral head neck junction during resurfacing arthroplasty: a comparison of two approaches using laser Doppler flowmetry. *J Bone Joint Surg Br.* 2008;90:442–5.
- Beaulé P, Campbell P, Shim P. Femoral head blood flow during hip resurfacing. *Clin Orthop Relat Res.* 2007;456:148–52.
- Long WT, Dastane M, Harris MJ, Wan Z, Dorr LD. Failure of the Durom Metasul acetabular system. *Clin Orthop Relat Res.* 2010;468:400–5.
- Migaud H, Putman S, Combes A, Berton C, Bocquet D, Vasseur L, et al. Metal-on-metal bearing: is this the end of the line? We do not think so. *HSS J.* 2012;8:262–9.
- Vendittoli PA, Ganapathi M, Duval N, Lavoie P, Roy A, Lavigne M. Randomised controlled trial comparing two methods of acetabular cup positioning during total hip arthroplasty. *Hip Int.* 2007;17:137–42.
- Prosser GH, Yates PJ, Wood DJ, Graves SE, Steiger RN, Miller LN. Outcome of primary resurfacing hip replacement: evaluation of risk factors for early revision. *Acta Orthop.* 2010;81:66–71.
- Heilpern G, Shah N, Fordyce M. Birmingham hip resurfacing arthroplasty: a series of 110 consecutive hips with a minimum five-year clinical and radiological follow-up. *J Bone Joint Surg Br.* 2008;90:1137–42.
- Robinson PG, Wilkinson AJ, Meek RM. Metal ion levels and revision rates in metal-on-metal hip resurfacing arthroplasty: a comparative study. *Hip Int.* 2014;24:123–8.
- Cuenca M, Torres R, León A, Mestre C, Marqués F. Does femoral component alignment increase metal ion levels in metal-on-metal hip resurfacing? *Int J Adv Jt Reconstruct.* 2020;7:2–8.
- Hartmann A, Kieback JD, Lutzner J, Gunther KP, Goronzy J. Adverse reaction to metal debris in a consecutive series of

- Durom hip resurfacing: pseudotumor incidence and metal ion concentration. *Hip Int.* 2017;27:343–8.
27. Pijls BG, Meessen JM, Tucker K, Stea S, Steenbergen L, Fenstad AM, et al. MoM total hip replacements in Europe: a NORE report. *EFORT Open Rev.* 2019;4:423–9.
  28. Naal FD, Pilz R, Munzinger U, Hersche G, Leunig M. High revision rate at 5 years after hip resurfacing with the Durom implant. *Clin Orthop Relat Res.* 2011;469:2598–604.
  29. Seppanen M, Karvonen M, Virolainen P, Remes V, Pulkkinen P, Eskelinen A, et al. Poor 10-years survivorship of hip resurfacing arthroplasty. *Acta Orthop.* 2016;87:554–9.
  30. Van der Straeten C, International Hip Resurfacing Group. Hip resurfacing arthroplasty in young patients: international high-volume centers' report on the outcome of 11,382 metal-on-metal hip resurfacing arthroplasties in patients  $\leq 50$  years at surgery. *Hip Int.* 2020, <http://dx.doi.org/10.1177/1120700020957354>.