



Revista Española de Cirugía Ortopédica y Traumatología

www.elsevier.es/rot



CASE REPORT

How to create by your own a customized hip cement mega-spacer for a hip megaprosthesis two-stage revision surgery after oncologic limb-salvage surgery – Surgical technique and case report[☆]

M. Fa-Binefa, M. Valera Pertegás, A. Peiró Ibañez, L. Trullols Tarragó,
P. Machado Granados, I. Gracia Alegría^{*}

Orthopedic Oncology Unit, Hospital de la Santa Creu i Sant Pau, Universitat Autònoma de Barcelona, Barcelona, Spain

Received 6 November 2023; accepted 2 January 2024

KEYWORDS

Hip megaprosthesis;
Arthroplasty;
Surgical oncology;
Reoperation;
Prosthesis-related
infections;
Cement spacers

Abstract Managing chronic periprosthetic infections in patients who have undergone limb-salvage surgery following a malignant bone tumor with megaprosthesis often involves a two-stage revision surgery with the use of a cement-spacer. This paper shows details the preparation of a self-made intramedullary metal-stabilized mega-cement spacer for patients needing a two-stage revision surgery due to infection after oncologic bone tumor resection and limb-salvage surgery with megaprosthesis and present two clinical cases treated with this technique. The report provides a practical surgical technique to create a cement hip mega-spacer using readily available tools in most orthopedic surgical settings.

© 2024 SECOT. Published by Elsevier España, S.L.U. This is an open access article under the CC BY-NC-ND license (<http://creativecommons.org/licenses/by-nc-nd/4.0/>).

PALABRAS CLAVE

Megaprótesis de
cadera;
Artroplastia;
Oncología quirúrgica;
Reintervención
quirúrgica;

¿Cómo crear un megaespaciador personalizado para una cirugía de revisión en 2 tiempos de megaprótesis de cadera después de una cirugía de salvamento de extremidad por causa oncológica? - Técnica quirúrgica y reporte de 2 casos

Resumen El manejo de las infecciones periprotésicas crónicas en pacientes que han sido sometidos a cirugía de salvamento de extremidades mediante megaprótesis por un tumor maligno óseo a menudo implica una cirugía de revisión en 2 tiempos con el uso de un espaciador de cemento. Este artículo detalla la técnica quirúrgica para la creación de un megaespaciador de cemento con estabilización rígida intramedular y muestra 2 casos clínicos tratados con esta

[☆] Orthopedic Oncology Unit, Hospital de la Santa Creu i Sant Pau, Universitat Autònoma de Barcelona, Barcelona, Spain.

^{*} Corresponding author.

E-mail address: igracia@santpau.cat (I. Gracia Alegría).

<https://doi.org/10.1016/j.recot.2024.01.002>

1888-4415/© 2024 SECOT. Published by Elsevier España, S.L.U. This is an open access article under the CC BY-NC-ND license (<http://creativecommons.org/licenses/by-nc-nd/4.0/>).

Please cite this article as: M. Fa-Binefa, M. Valera Pertegás, A. Peiró Ibañez et al., How to create by your own a customized hip cement mega-spacer for a hip megaprosthesis two-stage revision surgery after oncologic limb-salvage. . . , Revista Española de Cirugía Ortopédica y Traumatología, <https://doi.org/10.1016/j.recot.2024.01.002>

Infecciones
relacionadas con
prótesis;
Espaciadores de
cemento

técnica de pacientes que necesitan una cirugía de revisión en 2 tiempos debido a una infección tras la resección del tumor óseo oncológico y cirugía de salvamento de extremidades con megaprótesis. Este texto proporciona una técnica quirúrgica sencilla y accesible para la creación de un megaespaciador de cadera de cemento utilizando herramientas disponibles en la mayoría de los quirófanos de nuestro entorno.

© 2024 SECOT. Publicado por Elsevier España, S.L.U. Este es un artículo Open Access bajo la licencia CC BY-NC-ND (<http://creativecommons.org/licenses/by-nc-nd/4.0/>).

Introduction

Advancements in the treatment of malignant bone tumors and progress in chemotherapy and radiation therapies have led to an increased demand for limb-salvage surgeries, which often involve the use of a megaprosthesis following surgical resection.¹ Megaprosthesis surgical implants exhibit higher complication rates compared to standard hip or hip revision surgeries. Factors such as patient life expectancy, implant design, pathologic soft tissue resection, and accompanying treatments can contribute to infection rates averaging 15–37%.¹ Addressing megaprosthesis infection typically involves a multidisciplinary approach, incorporating follow-ups with an infectious disease team, antibiotics, and two-stage revision surgeries with cement spacers.² Preformed antibiotic spacers have demonstrated improved surgical outcomes in terms of surgery duration, complication rate, and infection eradication in total hip arthroplasty.³ However, such data has not been extensively studied in oncologic patients. Moreover, due to the unique characteristics and relatively infrequent use of megaprosthesis, specific preformed spacers might not always be available or in stock for surgeries that cannot always be delayed.

The objective of this paper is to detail a replicable and accessible technique to assemble a tailored cement-spacer for hip megaprosthesis. This technique can accommodate and adjust to various modular components and bone stock availability, assisting surgical teams with the complex challenge of hip megaprosthesis infections after bone tumor surgery.

Surgical technique

To create the custom cement spacer for a hip megaprosthesis, the following items are needed: (1) explanted stem, (2) specific hip cement spacer, (3) Steinmann's pins, (4) metal banding x2, and (4) plastic tubes (syringe, others).

After surgical explant we will have the available length and width of the hip megaprosthesis stem in the different modular/interface levels.

First, we tried the optimal head measure for the different hip commercial cement spacers available. In our case we used the hip stem cement spacer *Vancogenx Space Hip XL Flat System* (Tecres SPA).

Then, we measured the distance from the stem tip to the first module-width and from the first module-width to

the second module-width interfaces and marked these same distances in the hip cement spacer.

After that, we added two 6 mm Steinmann's pins in each side of the cement spacer, with a 10 cm superposition with the preformed cement spacer stem and blocked them to the cement stem with two proximal metallic bands.

Once, we used the sterile container tube of a thoracic catheter (Argyle – Thoracic Catheter – Covidien) which has same with as the original distal megaprosthesis stem. However other plastic tubular structures available in the surgery room, such as syringes can be used. This structure can vary depending on required width and available structures but must be wider than new width of the distal stem with added Steinmann. Steinmann can be < 6 mm in cases with thinner stems.

Afterwards that we introduce the tubular plastic structure until the first marked width-change marked interface from the original megaprosthesis. A transparent dressing or a glove can be used to fix it proximally and avoid leaks. Distal tube is cut according to surgeon preferences and distal bone stock available.

We proceed with the antibiotic-based cementation from the distal tube opening. When cementation process is finished, we remove external plastic cover with a blade.

Then, we used a 60 ml-syringe with similar width to the original proximal module of the megaprosthesis, also using a dressing or a glove to fix it proximally and avoid leaks.

Finally, as that diaphysis are usually wider than healthy ones, we proceed again with same cementation process. If needed, a distal cement crown can be hand added in situ to give extra support.

This method facilitates the undertaking of a first-stage megaprosthesis revision surgery in the context of infections specific to hip megaprosthesis (Fig. 1).

Case report and outcomes

Two cases of first-stage septic hip megaprosthesis revision surgery are documented. Both patients suffered periprosthetic infections with a tumor prosthesis initially implanted as a reconstructive measure after a proximal femur resection for limb-sparing surgery of bone sarcoma.

Case report 1

Man 62yo, with hypertension and smoking history, choroid melanoma 10 years ago, was diagnosed 6 years ago of

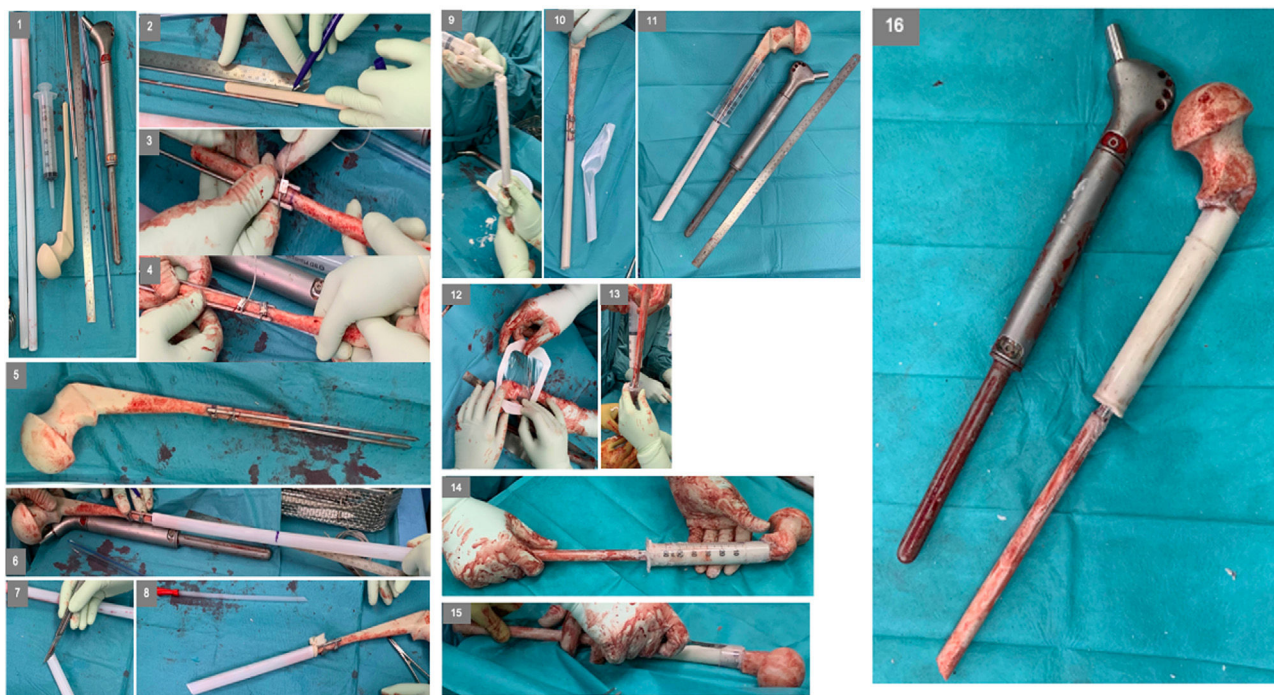

Figure 1 Customized hip cement mega-spacer for a hip megaprosthesis two-stage revision surgery. (1) Material, (2) measure first interphase, (3) Steinman cerclage no. 1, (4) Steinman cerclage no. 2, (5) hip spacer – Steinman construct, (6) measure check, (7) cut according to measurement, (8) glove cement stop, (9) first interphase cementation, (10) plastic tub extraction, (11) preparation of second interphase cementation, (12) dressing cement stop, (13) second interphase cementation, (14) cemented second interphase, (15) syringe tub cut, and (16) final result compared to explanted megaprosthesis.

a proximal femur II/III chondrosarcoma requiring surgical treatment with marginal resection and a double mobility hip megaprosthesis. Postoperative radiotherapy was done for 6 months with no evidence of periprosthetic infection or tumor recurrence. In the following years, he was diagnosed of loosening requiring revision surgery with negative intraoperative cultures. After 2 months, he presented in the emergency room with tenderness, increased CRP, and he was diagnosed of subacute surgical site infection with negative cultures for *Staphylococcus epidermidis* requiring two-stage surgical revision. A customized hip antibiotic-loaded cement mega-spacer was used for the first stage of revision surgery as presented. Three months after that, in the 2nd stage revision surgery a revision mega prosthesis was implanted. Follow up, with long term suppressive antibiotic treatment, evolved with no other incidences (Fig. 2).

Case report 2

Women 21yo, with no previous pathology was diagnosed of a femoral osteogenic osteoblastic sarcoma. Patient started neoadjuvant chemotherapy and required resection tumor surgery with hip mega prosthesis reconstruction. In the immediate postoperative patient required embolization of medial gluteal artery. Postoperatively, surgical wound was associated to drainage, evolving to a fistula with positive cultures to *S. epidermidis* and starting antibiotherapy. During the following months she presented to emergency room twice with hip megaprosthesis dislocations and was proposed for a two-stage revision surgery. A customized hip

antibiotic-loaded cement mega-spacer was used for the first stage of revision surgery as presented (Fig. 3). Three months after that, in the 2nd stage revision surgery a revision mega prosthesis was implanted. Follow up, with long term suppressive antibiotic treatment, evolved with no other incidences.

Discussion

Cement spacers play a pivotal role in two-stage revision surgical techniques, with various researchers and literature exploring numerous means to adapt their use in hip and knee periprosthetic infections. Preformed or modeled cement spacers are reported to reduce complications in comparison to non-molded handmade spacers⁴ and some factors such as spacer design, acetabular and femoral bone loss, offset restoration have been significantly associated with perioperative spacer complications in two-stage revision surgeries.⁵ However, modeled cement spacers are not always accessible or available.

Previous literature suggested multiple options of customized handmade techniques for hip cement-spacers with good outcomes including: intraoperative articular knee cement spacer for knee revision surgeries,⁶ acetabular defect cement spacer cover for hip revision surgeries with acetabular defects,⁷ hip cement spacers made with dental silicone templates for total hip revision surgery⁸ and reverse hip prefabricated spacer for knee revision surgery with massive bone defects.⁹ Some authors also proposed alternative techniques including metallic implants com-

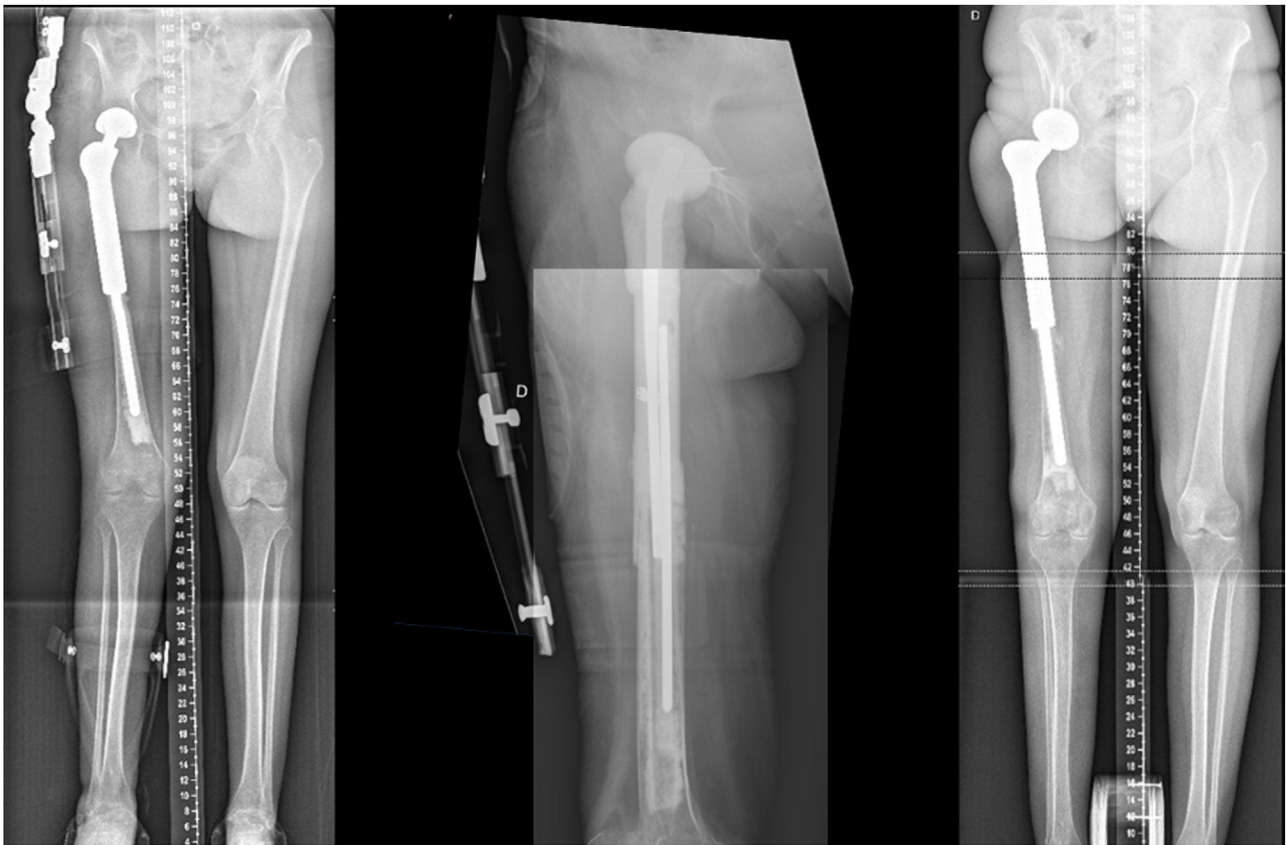

Figure 2 Customized hip cement mega-spacer for a hip megaprosthesis septic two-stage revision surgery after proximal femur chondrosarcoma (preoperative, 1st stage, and 2nd stage).

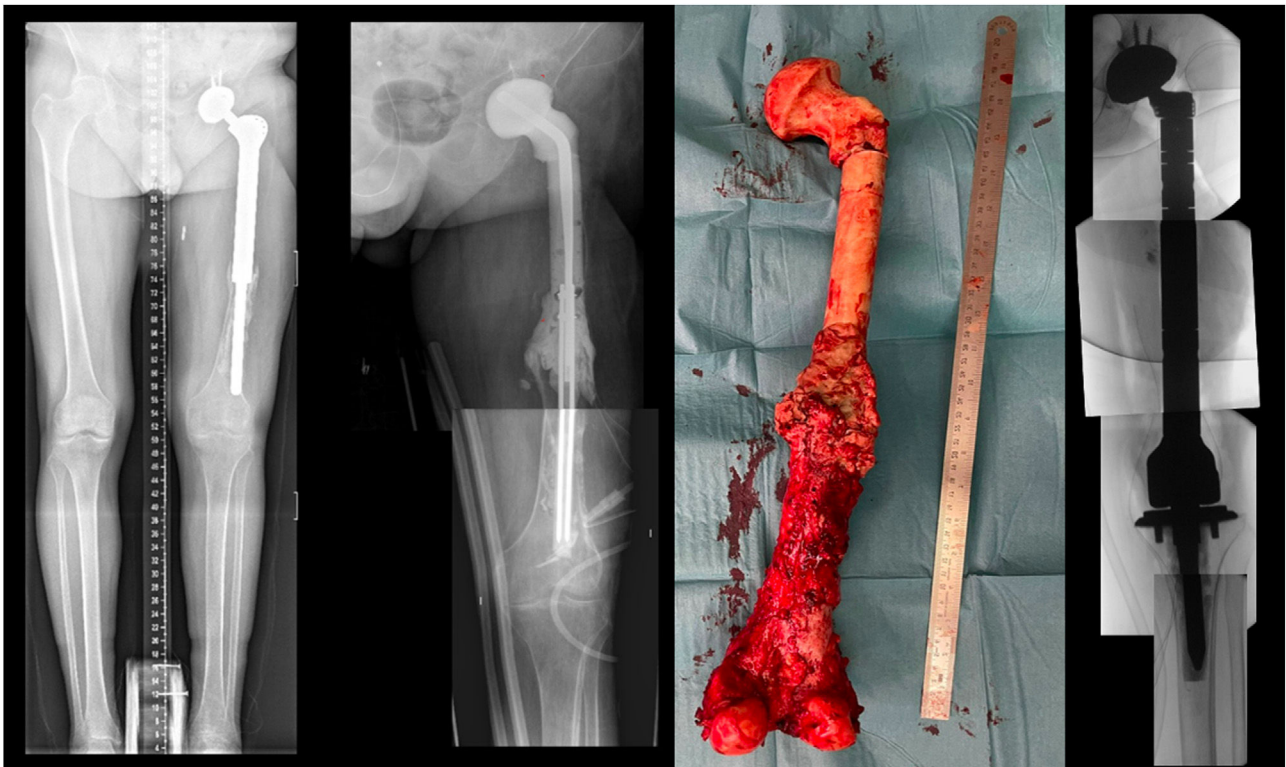


Figure 3 Customized hip cement mega-spacer for a hip megaprosthesis septic two-stage revision surgery after osteogenic osteoblastic sarcoma (preoperative, 1st stage, spacer and 2nd stage).

bined with cement spacers with good results including: hip arthroplasty revision surgery with Steinmann pins,¹⁰ hip arthroplasty revision surgery with reconstruction plates mixed with acetabular cement-ball,¹¹ knee revision surgery with intramedullary stabilized antibiotic spacers in patients with large segmental defects¹² and total femur prosthesis cement spacers.¹³

Despite the promising potential of antibiotic-loaded cement in cement spacers as part of the treatment regimen for periprosthetic joint infections,¹⁴ their efficacy against infection remains ambiguous.¹⁵ One major complication of two-stage revision surgery due to infections, is THA dislocation, reported in up to 8.9% of cases at 1 year follow up.¹⁶ The rate is potentially higher for megaprosthesis, considering the increased soft tissue damage due to pathology and surgery.

Nevertheless, there's a paucity of literature specifically addressing oncologic limb-salvage surgery with megaprosthesis. Most decision-making inputs come from literature on prosthetic revision surgery, experiential insights, or case series reports.

Conclusion

This technique empowers surgical resources of an orthopedic team to conduct a two-stage revision surgery. The straightforward, cost-effective, and accessible surgical technique allows for the creation of an intramedullary metal-stabilized mega-cement spacer for patients who have undergone limb-salvage megaprosthesis surgery following an oncologic bone tumor resection.

Level of evidence

Level of evidence IV.

Funding

This research has not received specific aid from public sector agencies, commercial sectors or non-profit entities.

Conflicts of interest

None declared.

References

1. Pilge H, Gradl G, von Eisenhart-Rothe R, Gollwitzer H. Incidence and outcome after infection of megaprotheses. *HIP Int.* 2012;22 Suppl. 8, <http://dx.doi.org/10.5301/HIP.2012.9576>.
2. Gundavda MK, Katariya A, Reddy R, Agarwal MG. Fighting megaprosthesis infections: what are the chances of winning? *Indian J Orthop.* 2020;54:469–76, <http://dx.doi.org/10.1007/s43465-020-00080-z>.
3. Rollo G, Logroscino G, Stomeo D, Cioffi R, Calvisi V, Meccariello L. Comparing the use of preformed vs hand-made antibiotic spacer cement in two stages revision of hip periprosthetic infection. *J Clin Orthop Trauma.* 2020;11 Suppl. 5:S772–8, <http://dx.doi.org/10.1016/j.jcot.2020.08.003>.
4. Pinsornsak P, Niruktisarn T, Surabotsopon P, Boontanapibul K. Novel molded antibiotic cement spacer: is it better than handmade cement spacer for treatment of chronically infected total hip arthroplasty? *Int Orthop.* 2022;46:1693–700, <http://dx.doi.org/10.1007/s00264-022-05456-4>.
5. Jones CW, Selemmon N, Nocon A, Bostrom M, Westrich G, Sculco PK. The influence of spacer design on the rate of complications in two-stage revision hip arthroplasty. *J Arthroplasty.* 2019;34:1201–6, <http://dx.doi.org/10.1016/j.arth.2019.02.012>.
6. Shen H, Zhang X, Jiang Y, et al. Intraoperatively-made cement-on-cement antibiotic-loaded articulating spacer for infected total knee arthroplasty. *Knee.* 2010;17:407–11, <http://dx.doi.org/10.1016/j.knee.2009.11.007>.
7. Fu J, Xiang Y, Ni M, et al. The use of augmented antibiotic-loaded cement spacer in periprosthetic joint infection patients with acetabular bone defect. *J Orthop Surg Res.* 2020;15, <http://dx.doi.org/10.1186/s13018-020-01831-2>.
8. Ohtsuru T, Morita Y, Murata Y, et al. Custom-made, antibiotic-loaded, acrylic cement spacers using a dental silicone template for treatment of infected hip prostheses. *Eur J Orthop Surg Traumatol.* 2018;28:615–20, <http://dx.doi.org/10.1007/s00590-017-2117-3>.
9. Flores X, Vicente M, Haddad S, Amat C, Carrera L, Corona PS. Espaciador de cadera «invertido» para defectos masivos de fémur distal en infecciones periprotésicas de rodilla. *Rev Esp Cir Ortop Traumatol.* 2016;60:346–54, <http://dx.doi.org/10.1016/j.recot.2016.06.008>.
10. Faschingbauer M, Reichel H, Bieger R, Kappe T. Mechanical complications with one hundred and thirty eight (antibiotic-laden) cement spacers in the treatment of periprosthetic infection after total hip arthroplasty. *Int Orthop.* 2015;39:989–94, <http://dx.doi.org/10.1007/s00264-014-2636-z>.
11. Maheshwari AV, Pivec R, Abraham R, Naziri Q. Reconstruction plate-based antibiotic cement spacers: clinical outcomes and description of technique. *J Long Term Eff Med Implants.* 2018;28:37–40, <http://dx.doi.org/10.1615/JLongTermEffMedImplants.2017020613>.
12. Ippolito JA, Thomson JE, Rivero SM, Beebe KS, Patterson FR, Benevenia J. Management of large segmental bone defects at the knee with intramedullary stabilized antibiotic spacers during two-stage treatment of endoprosthetic joint infection. *J Arthroplasty.* 2021;36:2165–70, <http://dx.doi.org/10.1016/j.arth.2021.01.026>.
13. Maupin JJ, Corning E, Steinmetz RG, White J. Creating a dual articulating antibiotic spacer for management of an infected total femur prosthesis hemiarthroplasty. *Arthroplast Today.* 2019;5:482–5, <http://dx.doi.org/10.1016/j.artd.2019.07.002>.
14. Amin SJ, Patel RM, Gutowski CJ, Kim TWB. Outcomes after antibiotic megaspacer implantation in patients with severe chronic periprosthetic infections. *J Orthop Res.* 2021;39:308–19, <http://dx.doi.org/10.1002/jor.24911>.
15. Chang M-W, Wu C-T, Yen S-H, Tan TL, Lin P-C, Kuo F-C. Influence of the type of bone cement used in two-stage exchange arthroplasty for chronic periarticular joint infection on the spacer replacement and reinfection rate. *J Clin Med.* 2023;12:600, <http://dx.doi.org/10.3390/jcm12020600>.
16. McAlister IP, Perry KI, Mara KC, Hanssen AD, Berry DJ, Abdel MP. Two-stage revision of total hip arthroplasty for infection is associated with a high rate of dislocation. *J Bone Jt Surg Am.* 2019;101:322–9, <http://dx.doi.org/10.2106/JBJS.18.00124>.