

# Prevention of post-laminectomy peridural fibrosis with aceclofenac. An experimental rabbit study

M.A. Sandoval<sup>a</sup> and D. Hernández-Vaquero<sup>b</sup>

<sup>a</sup>San Agustín Hospital. Avilés. Asturias.

<sup>b</sup>Department of Surgery. School of Medicine. Oviedo. Asturias.

**Purpose.** Peridural fibrosis is one of the most frequent complications of lumbar surgery and no mechanical procedure is known that can prevent its appearance. Aware of the ability of non-steroid anti-inflammatory drugs to inhibit inflammatory and fibroblastic response, we decided to examine the role of aceclofenac as a chemical barrier that can prevent the condition.

**Materials and methods.** We performed a laminectomy in the L4-L5 space in 24 rabbits, distributed into 2 groups, which were put down at 2 and 4 weeks respectively. The study group received a 5 mg/kg daily dose of aceclofenac for 7 days. Rabbits in the control groups were injected saline solution. After immunohistochemical staining, histologic preparations were studied by means of imaging techniques. The cell populations present in the inflammatory reaction were quantified as well as the thickness of the fibrous membrane.

**Results.** The mean fibrous surface was invariably smaller in the rabbits in the study groups than in those in the control groups (47% smaller at 2 weeks and 41% smaller at 4 weeks). The number of fibroblasts decreased by 8% in the study groups. Also, a smaller number of inflammatory cells was detected in these groups.

**Conclusions.** Although aceclofenac does not prevent the experimental formation of peridural fibrosis, it does delay it since it inhibits the presence of inflammatory cells in the fibrous scar at early stages and reduces the extent of its adhesiveness.

**Key words:** *peridural fibrosis, laminectomy.*

**Fuentes de financiación:** Ayuda a Nuevos Proyectos (NP-97-11) del Vicerrectorado de Investigación de la Universidad de Oviedo (1997).

Beca del Fondo de Investigación Sanitaria (00/0663) del Ministerio de Sanidad y Consumo (2000).

*Corresponding author:*

M.A. Sandoval.  
Hospital San Agustín. Avilés.  
C/ Cabruñana, 48, 1.º A  
33402 Avilés.  
E-mail: sandovalmag@yahoo.es

Received: April 2006.

Accepted: September 2006.

## Prevención con aceclofenaco de la fibrosis peridural post-laminectomía. Estudio experimental en conejos

**Objetivo.** La fibrosis peridural es una de las complicaciones más frecuentes de la cirugía lumbar y no se conoce ningún procedimiento mecánico que prevenga su aparición. Conocida la facultad de los antiinflamatorios no esteroideos de inhibir la respuesta inflamatoria y fibroblástica, nuestro trabajo pretende examinar la capacidad del aceclofenaco como barrera química que evite su formación.

**Material y método.** Practicamos una laminectomía en el espacio L4-L5 en 24 conejos, distribuidos en 2 grupos, que se sacrificaron a las 2 y 4 semanas, respectivamente. El grupo de casos recibió 5 mg/kg/día de aceclofenaco, durante 7 días. El grupo de controles recibió suero fisiológico inyectado. Tras una tinción inmunohistoquímica, las preparaciones histológicas fueron estudiadas mediante análisis de imagen. Se cuantificaron las poblaciones celulares presentes en la reacción inflamatoria y el grosor de la membrana fibrosa.

**Resultados.** La media de la superficie fibrosa fue siempre menor en los conejos de los grupos de intervención frente a los controles (47% menor a las 2 semanas y 41% menor a las 4 semanas). El número de fibroblastos disminuyó un 8% en los grupos experimentales. También se observó un menor número de todas las células inflamatorias.

**Conclusiones.** El aceclofenaco no evita la formación experimental de la fibrosis peridural, pero sí la retrasa, ya que inhibe la presencia de células inflamatorias en la cicatriz fibrosa en estadios precoces y reduce la extensión de su adhesividad.

**Palabras clave:** *fibrosis peridural, laminectomía.*

Funding: Aid for New Projects (NP-97-11) from the Vice-Deanship of the University of Oviedo (1997). Grant from the Health Research Fund (00/0663) of the Ministry of Health and Consumer Affairs (2000).

One of the most severe complications that may arise after disc surgery is periradicular or peridural fibrosis (PF).

PF consists in the formation of extradural fibrotic tissue that causes adhesions of the dura mater and the nerve roots to the paravertebral muscles of the spine, dorsally, and the disc and vertebral body anteriorly. This scar formation restricts mobility of the nerve root and makes it more vulnerable to relapses of disc protrusion and spinal canal stenosis. Some authors<sup>1</sup> consider that the main cause of postsurgical pain after lumbar disc removal and laminectomy is peridural fibrosis, which can cause entrapment of the nerve roots and neuropathic pain (deafferentation pain). Currently the most popular etiopathogenic theory is the one proposed, in 1974, by LaRocca and MacNab<sup>2</sup>, who state that PF proceeds from the bleeding surface of the deep layer of the posterior paravertebral muscles. These authors named this layer 'the laminectomy membrane'; it covers the defect created by the laminectomy, filling the empty space by forming fibrous tissue, which extends into the neural canal, in an attempt to reconstitute the resected lamina.

In the face of an established and diagnosed PF, there are few possible therapeutic measures. No pharmacological treatment is known that will cure PF<sup>3</sup>, and painkillers or non-steroidal anti-inflammatory drugs (NSAIDs) are prescribed or physiotherapy applied during painful periods. The literature shows that there are no uniform criteria for indicating surgery. Some authors systematically rule it out<sup>4</sup> and others admit it as a salvage option in patients with incapacitating pain<sup>5</sup>.

It is now accepted that the best way to avoid PF is to prevent its formation. Some intraoperative preventive measures have been described, such as a meticulous surgical procedure<sup>6</sup>, careful hemostasis and the placement of barriers between the paravertebral muscles and the dura mater, both physical<sup>7-9</sup> and chemical<sup>10-12</sup>. NSAIDs are an example of a chemical barrier. Chemical barriers have an advantage over physical barriers in that no foreign bodies are inserted that could, themselves, increase the secondary inflammatory response to surgical trauma. On the contrary, NSAIDs inhibit cyclooxygenase which is responsible for synthesizing prostaglandins (PG), biological mediators of great potency capable of causing vasodilation and chemotaxis. Furthermore, we must mention the known effect of NSAIDs in the prevention of calcifications, heterotopic ossifications and abdominal adhesions<sup>13</sup>.

Our aim is to determine whether aceclofenac, a commonly used NSAID, given from the moment of surgery, is capable of inhibiting fibroblastic proliferation after laminectomy in the rabbit.

## MATERIALS AND METHODS

This study, approved by the Ethics and Research Committee of our hospital, complies, in all its parts, with Royal Decree 223/1988 of March the 14th, the Order of October

1989 and the Directive of the Council of Europe of November 24<sup>th</sup>, 1986 (86/609/CEE).

We carried out an experimental study in 24 male New Zealand White (NZW) rabbits, carrying out a laminectomy in the L4-L5 intervertebral space. The rabbits were divided into 2 groups, killed at 2 and 4 weeks, respectively. They were all anesthetized with an intramuscular injection of ketamine (35 mg/kg), xylazine (5 mg/kg) and acepromazine (1 mg/kg). Antibiotic prophylaxis was carried out with cephalocine (50 mg/kg intramuscular) given in a preoperative dose. A 4 cm incision was made with a scalpel in the posterior mid-line between L3 and L5, since rabbits have 7 lumbar vertebrae and the height of the L5 vertebral body is 24 mm<sup>14</sup>. The fascia was incised to expose the tip of the spinous processes, which are short and oriented cranially. The paraspinous muscles were dissected subperiostally from the processes and the laminae and retracted with an autostatic laminectomy retractor. The laminectomy consisted in the resection of the spinous process of the caudal vertebra, resection of the ligamentum flavum and resection of lower articular processes of the cranial vertebra and of the distal third of the lamina of this vertebra (L4), until an exposure of the dura mater of 4 x 8 mm, approximately, was achieved. A meticulous technique was used so as not to damage the spinal cord. The rabbits were divided into 2 experimental groups according to whether they were killed in the second or the fourth week (G1 and G3, respectively) and their corresponding control groups (G2 and G4); thus there were 4 groups of 6 rabbits each. The rabbits in the control groups were injected, by the intramuscular route, with 1 cc of saline, from the day of surgery up to the seventh day post-surgery.

The rabbits in the experimental groups received 5mg/kg per day of aceclofenac, by the intramuscular route, from the day of surgery up to the seventh day post-surgery

The rabbits were killed at 2 or 4 weeks, according to the group they belonged to, by means of an overdose of pentobarbital (60 mg/kg) by the intravenous route. The spine was extracted in one block, from L3 to L5, for its pathological study. The specimen was fixed with formaldehyde at 10% for 24 hours and decalcified with formic acid for 3 weeks. Axial sections of 2 mm (Figure 1) were performed and included in paraffin. The preparations were stained with hematoxylin-eosin (H-E), which allowed a quantification of inflammatory cells: lymphocytes, macrophages and polymorphonuclear cells (PMN); with Masson trichromic stain, which allowed quantification of the area of the fibrous membrane; and by immuno-histochemical methods (IHC), which allowed quantification of the fibroblasts using an analytic system.

The following methodology was used for the immuno-histochemical techniques:

Antigens were unmasked using heat; immuno-staining was used to detect antigens using the streptavidin-biotin-




Figure 1. Axial spinal cord sections of 2 mm.

peroxidase complex; enzyme marking was performed using horse-radish peroxidase; diaminobenzidine (DAB); was used as a chromogen and rabbit monoclonal anti-vimentin (clona V9, Biogenex®) was used as a primary antibody. Vimentin is a protein formed by a single peptide of 57 kilodaltons that basically forms part of the cytoskeleton of fibroblasts and possesses antigenic expression.

The following measurements were made in each of the 4 histological sections obtained from each rabbit: area of the fibrous membrane in mm<sup>2</sup>, degree of adhesion to the dura mater, total number of fibroblasts per mm<sup>2</sup>, and density of inflammatory cells per mm<sup>2</sup>. The adhesions were scored as follows: grade 0 (no adhesion between the fibrosis and the dura mater) grade 1 (an adhesion of less than 1/3 of the area of the dura mater), grade 2 (between 1/3 and 2/3), grade 3 (greater than 2/3).

The detection of the area of fibrosis was performed based on the color-intensity of Masson's green stain, reflecting a false color for better visualization. Subsequently, a first selection was carried out using an optic pencil, marking the areas of fibrosis that were of interest, separating them from other areas with a similar depth of green color (for example, osteoid), and quantifying the area with fibrosis in mm<sup>2</sup>.

On the other hand, to quantify the number of fibroblasts, the immunochemical preparations were digitized using a Leica DC 100 (Leica, Solms, Germany) camera annexed to a microscope with an eyepiece with a magnification of 1.6 x, and an objective with a magnification of 10 x /0.25, and analyzed using a Leica QWIN (Leica, Solms, Germany) image processor.

Capture by means of digitization in the real color of the area of interest was carried out, thus establishing a color range. At that point automatic detection based on the color of all cell cytoskeletons (the immuno-histochemical reaction of vimentin stains all fibroblasts brown) was performed. In this way also quantification of the area measured was performed, and a determination of positive cells and positive cells/mm<sup>2</sup> carried out.

Table 1. Total fibrous area (in mm<sup>2</sup>)

Group	Area (mean, SD)	P
Group 1	2.9241 ± 2.0185	0.046
Group 2	6.2116 ± 3.2129	(between groups 1 and 2)
Group 3	1.3875 ± 1.0353	0.041
Group 4	3.2958 ± 1.8604	(between groups 3 and 4)

SD: Standard deviation.

Lastly, a quantification of inflammatory cells was performed (lymphocytes, PMNs and macrophages) after staining the histological preparations with H-E and Masson trichromic.

Descriptive statistics and inferential statistics were used for data analysis. As the size of the sample is small, the Mann-Whitney non parametric U test was applied to continuous quantitative variables and chi square to qualitative variables.

## RESULTS

No superficial or deep infections were seen. Drainage was similar in both groups, with a mean of 1 ml. Surgical sutures were removed at 7 days. In no case were there dehiscences or macroscopic alterations of the surgical wound.

The histological findings in the control group, at 2 weeks, were limited to a large hematoma that filled the site of the laminectomy and was in contact with the dura mater. In the group of cases, at 2 weeks, there was a minor adhesion of the hematoma to the dura mater, with similar types of cells. In the control group, at 4 weeks, it was possible to see how the hematoma had progressively been replaced by fibrous tissue, and how areas adjacent to the resected lamina had suffered a metaplasia to chondroid and bone tissue. In the group of cases, at 4 weeks, the hematoma had been progressively replaced by fibrous tissue. The total fibrous area, at 2 and 4 weeks, is shown in table 1. The degree of adhesion, at 2 and 4 weeks, is outlined in table 2. The number of fibroblasts and inflammatory cells, at 2 and 4 weeks, is can be seen in tables 3 and 4.

It is possible to see that the mean value of the fibrous area is always less in rabbits in the active groups in comparison with those in the control groups, both at 2 and at 4 weeks. The difference is statistically significant ( $p < 0.05$ ) only when all the sections are studied as a group. As to the degree of adhesion of PF to the dura mater, we have seen that adhesion is always present, since no cases of grade 0 were seen.

In more than 70% of the total of samples this adhesion was, in its minimum expression, of moderate size and at least in 1/3 of cases was of considerable size. It was also less in the group of rabbits that received aceclofenac (Fig-

**Table 2.** Degree of adhesion (in %)

Adhesion	Group 1	Group 2	p	Group 3	Group 4	p
Grade 0	—	—	—	—	—	—
Grade 1	29.16	12.50	0.15	25	8.33	0.24
Grade 2	41.66	29.17	0.36	41.67	50	0.56
Grade 3	29.16	58.33	0.04	33.33	41.67	0.55

**Table 3.** Fibroblast cell density (per mm<sup>2</sup>)

Time	Cases (mean, SD)	Controls (mean, SD)	p
2 weeks	2,693 ± 415	3,377 ± 802	0.08
4 weeks	1,536 ± 930	2,203 ± 1.012	0.25

SD: Standard deviation

**Table 4.** Inflammatory cell density (per mm<sup>2</sup>)

Time	Cases (mean, SD)	Controls (mean, SD)	p
2 weeks	465 ± 95	578 ± 87	0.04
4 weeks	205 ± 94	281 ± 73	0.14

SD: Standard deviation.

ure 2). Significant statistical differences were only seen in cases of grade 3 and in the group killed at 2 weeks.

With regard to the cell density of the fibrous scar, fewer fibroblasts were seen in the active groups and these decreased progressively over time, but this was not of statistic significance. Furthermore, there was a smaller number of total inflammatory cells, but the difference was only statistically significant in the group killed at 2 weeks. The types of inflammatory cells were similar in both groups.

## DISCUSSION

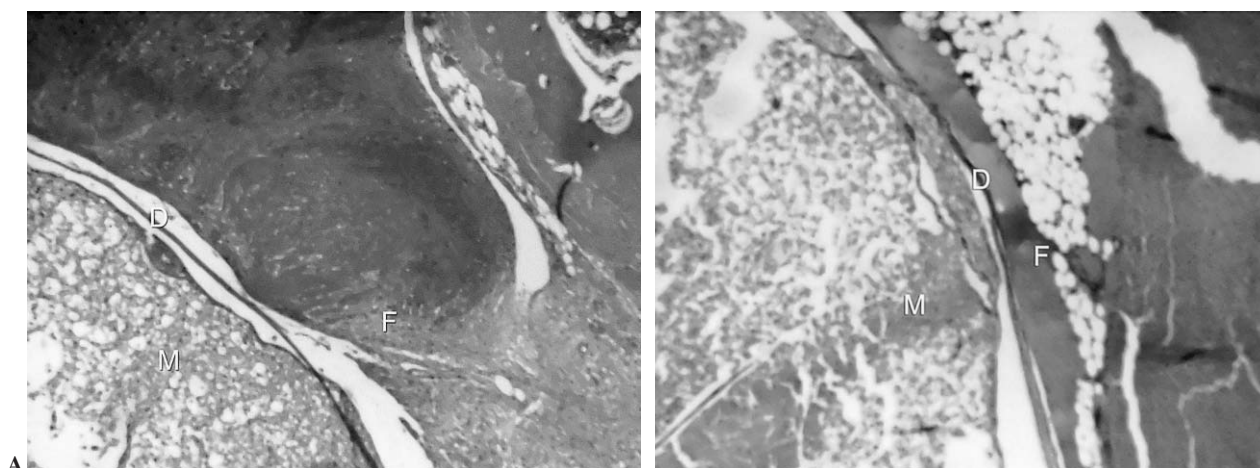
Different physical barriers have been used since the first studies carried out on PF by LaRocca and MacNab<sup>2</sup>. These barriers prevent fibroblast migration from the exposed muscles to the nerve structures. Many substances have been used with this purpose, both biological and inert, resorbable and non-resorbable, solid or liquid, and it has been proved that none is effective. Recently an expandable polytetrafluoroethylene (ePTFE)<sup>15</sup> and ADCONL (bioresorbable gelatin and polyglycan gel)<sup>16</sup> have been used.

Bagó et al<sup>17</sup> support the role of fat in place of fibrin which is hemostatic but stimulates the synthesis of fibroblasts. Beajeux et al<sup>18</sup> support the mechanical role of epidural fat, which protects and facilitates movement of the dural sac with regards to the osseous canal. The excision of this fat also favors the formation of PF. On the other hand, free fat grafts are not free of complications. Cabezudo et al<sup>19</sup> saw a compression of the fat graft on a root the third day after surgery, which made it necessary to re-operate. They consider it unadvisable to cut it too thickly because the muscles may push it into the canal.

Kuivila et al<sup>20</sup> in their review mention other more frequent problems of fat grafts such as necrosis, atrophy or even pressure on the cauda equina.

MacKay et al<sup>21</sup> studied other problems related to physical barriers. In a prospective clinical study they concluded that placing fat barriers on the roots and the dura after disc excision had no effect on resulting symptoms, functional status or MRi findings, since the interposed membrane offered no benefit.

Bellen<sup>22</sup> described a severe complication, one-root motor paralysis, caused by an intracranial hematoma on the third day after surgery, due to the use of a hemostatic sponge.



**Figure 2.** Fibrous adhesion to the dura mater at 4 weeks. A. Experimental group. B. Control group. H-E X 40. D: dura mater; F: peridural fibrosis; M: spinal cord.

Due to the poor results seen when physical or mechanical barriers were used, attempts have been made to use chemical barriers, such as steroids, tissue plasminogen activators, urokinase and elastase. They all have supporters and detractors, but currently their use is being abandoned<sup>10,12,20,22</sup>.

Steroids are potent anti-inflammatory drugs, but they have severe side effects such as extensive hemorrhages, formation of abscesses or delays in wound healing<sup>22</sup>.

As we know NSAIDs inhibit the synthesis of PG, and therefore decrease capillary permeability, inhibit inflammatory infiltration and control fibroblast hyperplasia and the formation of granulation tissue.

The choice of aceclofenac for this study is based on the fact that it is a widely used NSAID due to its analgesic and anti-inflammatory properties, and is a drug that is well tolerated when used for short periods of time. Aceclofenac is a derivative of fenilacetic acid, and has a structure similar to other NSAIDs; its mechanism of action is basically through inhibition of cyclooxygenase and, therefore, of the synthesis of PG<sup>11,23</sup>.

Kéller et al<sup>24</sup>, performing a local infusion of PGE2 in osteotomies in rabbits proved that it preferentially stimulated proliferation of connective tissue more than the multiplication of bone cells. NSAIDs, as they inhibit PGE2 production, decrease this connective tissue proliferation.

NSAIDs do not only inhibit PG synthesis, they also modify the synthesis of leukotrienes, the generation of superoxides, the release of enzymes from lysosomes, the aggregation and adhesion of neutrophils, the functions of the cell membrane (enzyme activity, anion transport across the membrane, oxidative phosphorylation, recapture of arachidonic acid), the function of lymphocytes, the production of rheumatoid factor and affect cartilage metabolism<sup>23</sup>.

As to the dose used in this study, the studies by Brogden and Wiseman<sup>23</sup> in rodents were considered. There is consensus that the appropriate dose is 5 mg/kg and that the route of administration is not of clinical relevance<sup>25</sup>. Aceclofenac was administered for only one week so as to assess the early inhibitory effect on fibrosis, and also to avoid possible adverse reactions.

Most of the studies mentioned previously, except for a few exceptions<sup>9,26</sup>, only performed qualitative analysis, which therefore makes it difficult to compare how effective the different drugs or materials were.

We wish to highlight that in our study the mean value of the fibrous area was always less in the rabbits in the active group than in those in the control group, both at 2 and at 4 weeks. This difference was statistically significant ( $p < 0.05$ ) only when sections were studied as a group.

As far as the cell density of the fibrous scar is concerned, fewer fibroblasts are seen in the active groups, but this is not statistically significant, and there is a progressive decrease over time. Fewer inflammatory cells are also seen, but this difference is only statistically significant in the ear-

ly stages. The types of inflammatory cells were similar in both groups, as was also confirmed by He et al<sup>26</sup> in the study they performed with ketoprofene in rats

This study has allowed us to demonstrate that peridural fibrosis can be developed experimentally in rabbits and that aceclofenac is capable of reducing the fibrous area. Furthermore, it is capable of inhibiting the presence of inflammatory cells in the fibrous scar during early stages. However, it is not possible to see a significant statistical difference with regards to the presence of fibroblasts in animals treated with aceclofenac in comparison with control animals. We can therefore conclude that there is no evidence that aceclofenac can prevent the experimental formation of peridural fibrosis.

## REFERENCES

1. Hernández Vaquero D, Rubio González A, Romo Contreras I, Amigo Fernández A, Domínguez Gil I. La fibrosis peridural como complicación de la discectomía quirúrgica. *Rev Ortop Traumatol.* 1990;34 IB:372-6.
2. LaRocca H, MacNab I. The laminectomy membrane. *J Bone Joint Surg Br.* 1974;56B:545-50.
3. de Tribolet N, Porchet F, Lutz TW, Gratzl O, Brotchi J, Van Alphen A, et al. Clinical assessment of a novel antiadhesion barrier gel: prospective, randomized, multicenter, clinical trial of ADCON-L to inhibit postoperative peridural fibrosis and related symptoms after lumbar discectomy. *Am J Orthop.* 1998;27:111-20.
4. Senegas J, Vital JM, Riojas A, Richard O, Caille JM. Diagnostic de récive de hernie discale par la discographie-scanner. *Rev Chir Orthop.* 1988;74Suppl2:91-4.
5. Escribá Roca I. Tratamiento de las secuelas posquirúrgicas en cirugía lumbosacra. En: Herrera Rodríguez A, director. *Actualizaciones SECOT 1.* Barcelona: Masson; 2000. p. 285-95.
6. Yamagami T, Matsui H, Tsuji H, Ichimura K, Sano A. Effects of laminectomy and retained extradural foreign body on cauda equina adhesion. *Spine.* 1993;18:1774-81.
7. Griffet J, Bastiani F, Hofman P, Argenson C. Prévention de l'épidurite par un treillis de polyglactine 910 après laminectomie lombaire chez le rat. *Rev Chir Orthop.* 1992;78:365-71.
8. Robertson JT, Meric AL, Dohan FC, Schweitzer JB, Wujek JR, Ahmad S. The reduction of postlaminectomy peridural fibrosis in rabbits by a carbohydrate polymer. *J Neurosurg.* 1993;79:89-95.
9. Songer MN, Rauschnig W, Carson EW, Pandit SM. Analysis of peridural scar formation and its prevention after lumbar laminotomy and discectomy in dogs. *Spine.* 1995;20: 571-80.
10. Ceviz A, Arslan A, Ak HE, Inalöz S. The effect of urokinase in preventing the formation of epidural fibrosis and/or leptomeningeal arachnoiditis. *Surg Neurol.* 1997;47:124-7.
11. Cima Suárez M. Influencia de los antiinflamatorios no esteroideos en los osificaciones heterotópicas de las prótesis de cadera. [Tesis doctoral]. Oviedo: Departamento de Cirugía y Especialidades Médico-Quirúrgicas, Universidad de Oviedo; 1995.
12. Henderson R, Weir B, Davis L, Mielke B, Grace M. Attempted experimental modification of the postlaminectomy membrane by local instillation of recombinant tissue-plasminogen activator gel. *Spine.* 1993;18:1268-72.

13. Golan A, Winograd I, Bukovsky I. Prevention of post-surgical adhesion formation using aspirin in a rodent model: a preliminary report. *Hum Reprod.* 1995;10:1797-800.
14. Toh E, Mochida J. Histologic analysis of the lumbosacral nerve roots after compression in young and aged rabbits. *Spine.* 1997;22:721-6.
15. DiFazio FA, Nichols JB, Pope MH, Frymoyer JW. The use of expanded polytetrafluoroethylene as an interpositional membrane after lumbar laminectomy. *Spine.* 1995;20:986-91.
16. Einhaus SL, Robertson JT, Dohan FC, Wujek JR, Ahmad S. Reduction of peridural fibrosis after lumbar laminotomy and discectomy in dogs by a resorbable gel (ADCON-L). *Spine.* 1997;22:1440-6.
17. Bagó Granell J, Navarro Quilis A. Estudio experimental sobre el efecto hemostático de un sistema adhesivo de fibrina en laminectomías lumbares. *Rev Ortop Traumatol.* 1992;36 IB:607-11.
18. Beaujeux R, Wolfram-Gabel R, Kehrli P, Fabre M, Dietemann JL, Maitrot D, et al. Posterior lumbar epidural fat as a functional structure? *Spine.* 1997;22:1264-8.
19. Cabezudo JM, López A, Bacci F. Symptomatic root compression by a free fat transplant after hemilaminectomy. *J Neurosurg.* 1985;63:633-5.
20. Kuivila TE, Berry JL, Bell GR, Steffee AD. Heparinized materials for control of the formation of the laminectomy membrane in experimental laminectomies in dogs. *Clin Orthop.* 1988;236:166-74.
21. MacKay MA, Fischgrund JS, Herkowitz HN, Kurz LT, Hecht B, Schwartz M. The effect of interposition membrane on the outcome of lumbar laminectomy and discectomy. *Spine.* 1995;20:1793-6.
22. Bellen P. La prévention de la fibrose péridurale après laminectomie. À propos d'un cas de paralysie monoradiculaire due à un hématome intracanalair sur gelfoam®. *Acta Orthop Belg.* 1992;58:236-9.
23. Brogden RN, Wiseman LR. Aceclofenaco. Revisión de sus propiedades farmacodinámicas y de su potencial terapéutico en el tratamiento de los trastornos reumáticos y en el control del dolor. *Drugs.* 1996;52:113-24.
24. Keller J, Schumacher B, Lind M. Effect of local prostaglandin E2 on periosteum and muscle in rabbits. *Acta Orthop Scand.* 1992;63:623-7.
25. Dimar JR, Ante WA, Zhang YP, Glassman SD. The effects of nonsteroidal anti-inflammatory drugs on posterior spinal fusions in the rat. *Spine.* 1996;21:1870-6.
26. He Y, Revel M, Loty B. A quantitative model of post-laminectomy scar formation. *Spine.* 1995;20:557-63.

### Conflict of interests

The authors have declared that they have no conflict of interests.