

Use of a vascularized osteochondral graft from the base of the third metatarsal to address intraarticular malunions of the distal radius

F. del Piñal^a, F.J. García-Bernal^a, J. Delgado^a, M. Sanmartín^a, J. Regalado^a and B. Igual Pérez^b

^aInstituto de Cirugía Plástica y de la Mano. Hospital Mutua Montañesa y Clínica Mompía. Santander.

^bServicio de COT. Hospital Universitario Nuestra Señora de la Candelaria. Santa Cruz de Tenerife.

Purpose. Post-traumatic joint defect reconstruction constitutes a significant challenge for any surgeon. We hereby present our experience of using vascularized osteochondral grafts from the base of the third metatarsal to reconstruct large defects on the distal articular surface of the radius.

Case reports. Surgery was performed on three adults with articular defects in their distal radius and massive cartilage loss who were not eligible for correction through articular osteotomy. In 2 cases, the semilunar notch, and sigmoid cavity, were reconstructed; the scaphoid fossa was reconstructed in the third. Time from fracture to surgery went from 3 to 18 months. In all cases, a transplant was made of a pediculated graft of the base of the third metatarsal pedicled on the dorsal foot veins and arteries with a skin island, revascularized through termino lateral anastomoses to the radial artery and to the veins of the anatomic snuffbox.

Results. No vascular complications were detected. The postoperative flexion-extension range improved by a mean of 65°, strength by 52 kg and the pain score, measured on a visual

analog scale, 9 to 1.16 points. As regards the donor site, neither metatarsalgia nor gait difficulties were observed. One patient reported discomfort on the dorsum of the foot when wearing tight footwear, resulting from a likely neuroma of the deep peroneal nerve, which improved after 12 months.

Conclusions. Transplanting a vascularized osteochondral graft from the base of the third metatarsal is a useful therapeutic alternative to treat massive defects of the distal articulation of the radial bone. Sequelae at the donor site have been minimal.

Key words: vascularized osteochondral graft, osteochondral defect, intraarticular malunion, intraarticular fracture of the distal radius, intraarticular osteotomy.

Injerto osteocondral vascularizado de la base del tercer metatarsiano para los callos viciosos intraarticulares del extremo distal del radio

Objetivo. La reconstrucción de defectos articulares postraumáticos constituye un difícil reto para el cirujano. Se presenta nuestra experiencia con injertos osteocondrales vascularizados tomados de la base del tercer metatarsiano para reconstruir grandes defectos en la superficie articular distal del radio.

Casos clínicos. Se han intervenido 3 adultos con defectos articulares en radio distal, con pérdidas masivas de cartílago no candidatos a corrección con osteotomía articular. En 2 casos se reconstruyó la fosa semilunar (y sigmoidea) y en el otro la escafoidea. El tiempo desde la fractura varió de 3 a 18 meses. En todos se trasplantó la base del tercer metatarsiano pediculado en la arteria y venas dorsales del pie con una isla cutánea de monitor, revascularizada mediante anastomosis terminolaterales a la arteria radial y venas de la tabaquera anatómica.

Resultados. No se presentaron complicaciones vasculares. Tras la intervención el rango de flexoextensión mejoró una

This paper has been presented, partially, at the 5th Course on New Trends in Hand Surgery, held in Santander, February 10-11, 2005; at the 17th Combined Congress of the Spanish Society of Hand Surgery and the British Society of Hand Surgery, held in Valladolid, April 14-16, 2005; at the 21st National Congress of the Italian Society of Micro-Surgery, held at Turin, Italy, May6-7, 2005; at the 40th National Congress of the Spanish Society of Plastic and Reconstructive Surgery, held in La Coruña, June 1-4, 2005; at the 10th Congress of the European Federation of Societies of Hand Surgery, held in Goteborg, Sweden, June 15-18, 2005; and at the Third Congress of the World Society of Reconstructive Micro-Surgery, held in Buenos Aires, Argentina, October 23-26, 2005.

Corresponding author:

F. del Piñal.
Instituto de Cirugía Plástica y de la Mano.
Hospital Mutua Montañesa y Clínica Mompía.
C/ Calderón de la Barca 16 entlo.
39002 Santander.
E-mail: drpinal@drpinal.com

Received: December 2005.

Accepted: July 2006.

media de 65°; la fuerza, 52 kg y el dolor medio medido por una escala visual analógica pasó de 9 a 1,16. Respecto a la zona donante, no hubo problemas de metatarsalgia, ni en la marcha. Un paciente refería molestias en el dorso del pie, con el calzado apretado, por un probable neuroma del nervio peroneo profundo, que mejoró a los doce meses.

Conclusiones. El trasplante de un injerto osteocondral vascularizado de la base del tercer metatarsiano constituye una alternativa terapéutica para el tratamiento de los defectos masivos de la carilla articular de radio distal. La secuela donante ha sido mínima.

Palabras clave: *injerto vascularizado osteocondral, defecto osteocondral, callo vicioso intraarticular, fractura intraarticular radio distal, osteotomía intraarticular.*

«*Cartilage once injured is incapable of healing*» (Hunter, 1743). When there is an osteochondral deficiency following radius fracture, the chosen treatment is partial or total arthrodesis¹⁻³. The literature presents numerous procedures for the successful reconstruction of joint defects, however, there is no agreement as to which of them is the best⁴⁻⁷. Surprisingly enough, we have found only one article in which the reconstruction of a post-trauma joint deficiency in the distal radius was attempted⁸ using an osteochondral non-vascularized graft of the fibula. Although the results that were published for two patients were satisfactory, the experience of other authors as well as our own, indicate that non-vascularized grafts are reabsorbed with time (at least those in the hand)⁹⁻¹¹. In order to solve this problem, we suggest using a vascularized osteochondral graft in this kind of transplant.

Is it necessary that the cartilage be vascularized? It is axiomatically believed that the hyaline cartilage feeds exclusively on synovial liquid^{12,13}. Nevertheless this axiom becomes weaker if we consider that there is hyaline cartilage in the outer ear. Moreover, the feeding role of blood becomes more evident if we consider that long-term studies have shown excellent results in cases of vascularized joint transfers^{14,15} and long-term joint collapses in non-vascularized transfers¹⁶⁻¹⁸. Finally, recent anatomic and physiological studies highlight the fundamental role of irrigation of the subchondral bone in the nourishment of the cartilage, at least in the bone-cartilage interface^{19,20}. These facts strengthen the idea that sustenance through blood is also important for the cartilage and for the integrity of the joint, and they would also explain, partially at least, the re-absorption of non-vascularized osteochondral grafts.

Basing ourselves on what we have stated above, we performed 8 vascularized osteochondral transplants with the aim of reconstructing different kinds of deficiencies in hand joints, and we obtained positive results. In this presentation

we describe our experience in the reconstruction of three cases of osteochondral defects in the distal radius with the base of the 3rd metatarsal.

Morphometric studies of the base of the 3rd metatarsal showed that the joint surface of this base is slightly concave or flat, and its size is large enough for reconstructing the scaphoid or lunate fossa of the radius. It also presented an extra facet in its fibular and dorsal aspect that was useful for reconstructing the dorsal region of the sigmoid fossa.

The nourishment of the base of the 3rd metatarsal depends on the laterodistal tarsal artery and on the arcuate artery, the former being dominant in 65% (13 out of 20) of the feet we studied²¹.

Surgical procedure

The radius is approached by means of an incision along the dorsal median line, between the long thumb extensor, which frees itself from its canal, and the 4th compartment, which rises subperiosteally. The joint is evaluated with an arthrotomy and, if the situation is favorable for reconstruction (as is explained in the section «Discussion»), a tridimensional defect is formed in the epiphysometaphyseal region, where the osteochondral graft will be inserted.

In an ischemic condition and by means of a dorsal zig-zagging approach the pedicle of the foot dorsal is localized. A perforating cutaneous vein is identified and isolated so as to include an island of skin that will be used as post-op monitor. The *hallucis brevis* extensor tendon that crosses the dorsal foot artery is sectioned. Displacing the *hallucis longus* medially and the long extensor tendons laterally, the vascularization of the back of the foot and of the bases of the metatarsals is exposed. The base of the 3rd metatarsal and the feeding arteries (arcuate, tarsal, laterodistal and/or small innominate periostic branches) are localized, and preserved and protected with a small periosteal cuff. A saw is used to section the 3rd metatarsal distally up to the arcuate, and all the capsuloligament structures are also sectioned, until the bone is pedicled in the dorsal vessels of the foot. The removal of the ischemia cuff enables the confirmation of the perfusion of the metatarsal base and of the cutaneous monitor (fig. 1).

The flap is transferred to the hand and the microvascular anastomoses are performed on the radial artery in the anatomic (terminolateral) snuff-box. Neighboring veins are used for the venous drainage: the subcutaneous veins of the forearm or the concomitant veins of the radial artery. In all the cases an island of skin was left as witness in order to monitor the vascularization of the graft.

The donor site is closed plane by plane and leaving a suction drainage in. No surgical maneuvers are made on the metatarsal. A protection splint is placed and walking is allowed with a rigid sole shoe (of the Tovipie kind). After the sixth day, walking without protection is allowed.

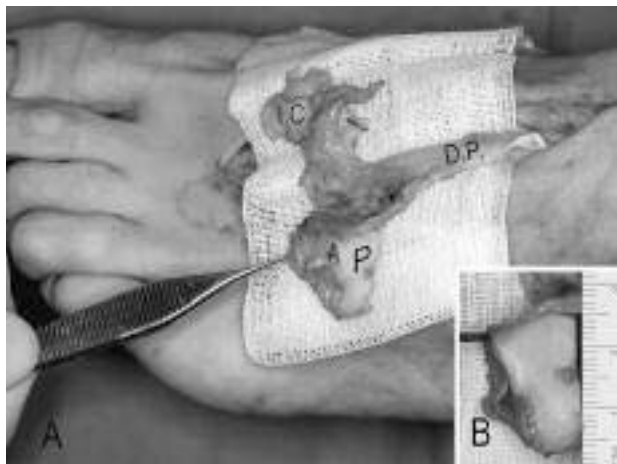


Figure 1. (A) Intraoperative view of case 2, with the osteochondral flap of the 3rd metatarsal pedicled in the dorsal artery and veins of the foot. (B) View of the main facet joint. A: accessory facet joint; DVF: dorsal vessels of the foot; CI: cutaneous island; MFJ: main facet joint.

Case 1

We receive a 33-year-old male with comminuted fracture of the distal radius, treated with osteosynthesis. After a 6-month rehabilitation period, the patient still manifested pain, stiffness and functional disability. The CT-scan revealed the destruction of 70% of the scaphoid fossa of the radius, which was reconstructed by means of the transfer of the base of the 3rd metatarsal, synthesized with two compression screws. Eight months after transfer, pain was minimum and joint balance was acceptable (20° active extension; 45° flexion), but the patient requested better mobility. Arthroscopic arthrolysis was carried out and osteosynthesis material was removed, confirming the satisfactory state of the cartilage and the presence of bleeding in the subchondral bone. In the last follow-up session (2 years later) the patient presents with a flexion of 50°, extension of 42°, radial deviation of 15°, ulnar deviation of 28°, contralateral hand strength of 78% (dominant hand), and pain according to the Visual Analog Scale (VAS) (0 = no pain; 10 = maximum pain) diminished from 9 to 1.5. The sequel in the donor site consisted in discomfort, with shoe pressure, on the back of the foot (*American Orthopaedic Foot and Ankle Society* [AOFAS] 85/100)²².

Case 2

A 55-year-old male is transferred from another center three months after comminuted ulna and radius fracture, both treated with an external fixator and plates. The patient complained of intense pain (10/10 by the VAS), a stiffness of the wrist (20° flexion-extension and 0° supination) and functional incapacity (strength could not be measured due to the impossibility of making a fist caused by stiffness of

the long fingers). The radiographic study revealed an ulnar impact due to the collapse of the radius, and the destruction of 60% of the dorsal of the lunate fossa, with affection of the sigmoid fossa (fig. 2). During intra-surgical exploration, we observed cartilage loss in more than half of the posteroulnar lunate fossa (fig. 3A). We dried the affected area of the lunate and the sigmoid fossa and placed the osteochondral graft in the defect (fig. 3B), achieving stabilization with two screws and revascularizing the anatomic snuff-box.

As in the previous cases, a cutaneous island was used as monitor. Concomitantly, the ulna was shortened by 5mm. Ten months later the patient presented with a flexoextension of 105°, a radial deviation of 12° and a deviation of 30°. Pronation was complete and supination was at 75°. Pain on the VAS was 1.5/10. There was no discomfort in the donor site (AOFAS 100) (figs. 4 and 5).

Case 3

We receive a 33-year-old male with comminuted intraarticular fracture of the distal radius and scapho-semilunar dissociation (with a 17-month evolution) who had been treated in another center with osteosynthesis and reattachment of the scapho-lunate ligament. The patient presented with pain, stiffness and functional incapacity. The CT-scan showed the destruction of the ulnar 70% of the lunate fossa of the radius and affection of the sigmoid fossa. This defect was reconstructed using a technique that was similar to the one used in the previous case. After a follow-up period of eight months, the patient had reached a flexion-extension of 45° and a 60% increase in strength compared to pre-op measurements. Pain in the VAS decreased from 8 to 0, and there was no discomfort in the donor site (AOFAS 100). Because of the short follow-up period and the positive evolution, the patient is expected to improve all the registered parameters.

DISCUSSION

Intraarticular malunions of the radius with residual steps of over 2mm bring about degenerative changes in the short term and very often incapacitating pain²³. In order to correct them, intraarticular osteotomy techniques that enabled the restoration of the joint surface were developed²⁴⁻²⁶. However, when there are more than three fragments, cartilaginous defects or when the joint degeneration has already occurred, joint osteotomies are not recommended. Instead, partial arthrodesis is considered the adequate treatment in these cases¹⁻³, since it relieves pain by restricting mobility.

In other fields of Orthopedics, the reconstruction of cartilaginous defects is subsidiary to multiple therapeutic options, with which it is possible to retain satisfactory

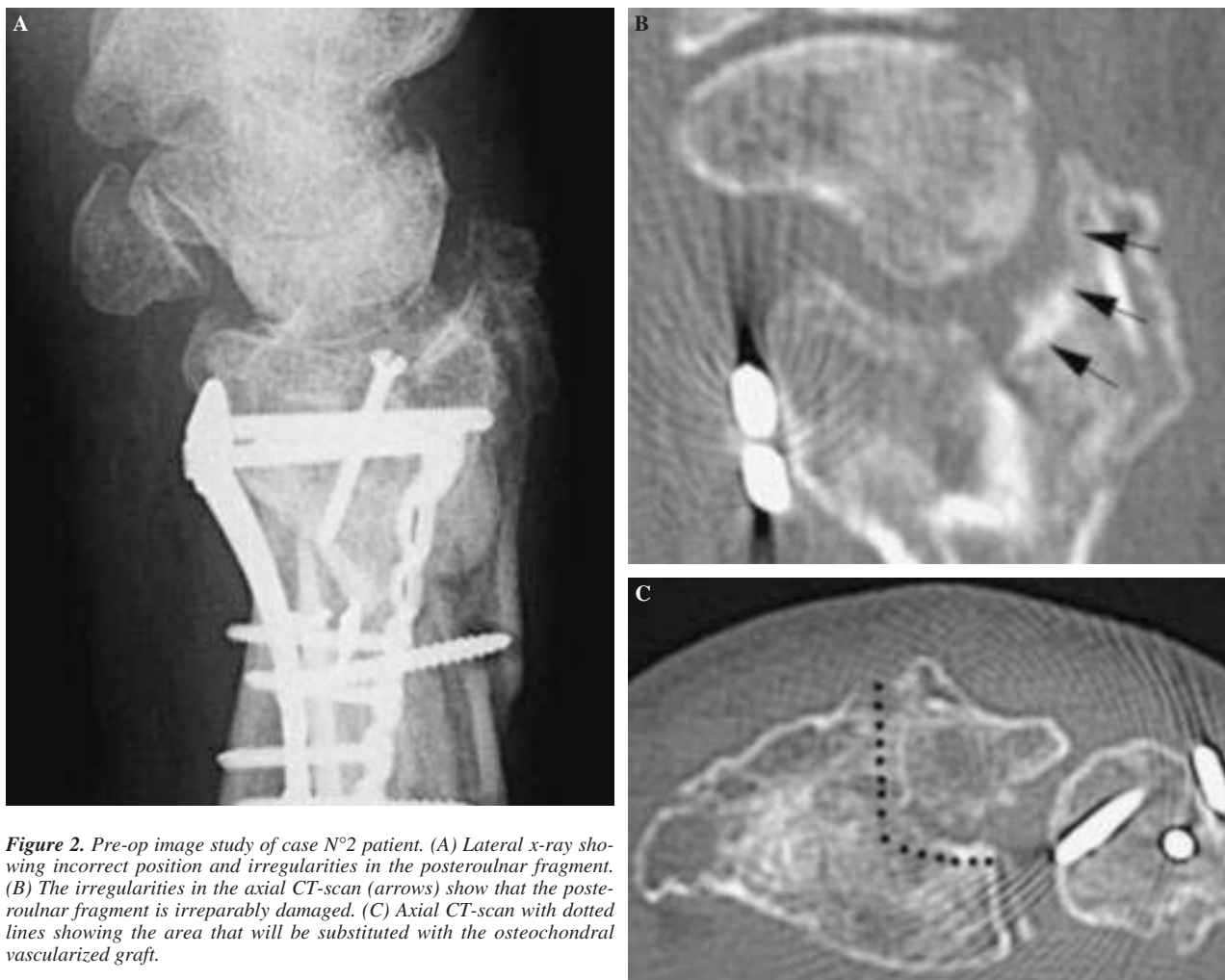

Figure 2. Pre-op image study of case N°2 patient. (A) Lateral x-ray showing incorrect position and irregularities in the posterolateral fragment. (B) The irregularities in the axial CT-scan (arrows) show that the posterolateral fragment is irreparably damaged. (C) Axial CT-scan with dotted lines showing the area that will be substituted with the osteochondral vascularized graft.

joint balance with minimum pain. It seems to be more sensible to reconstruct the defect on the joint surface using conventional techniques rather than with arthrodesis, even in the case of partial arthrodesis. However, subsidence with multiple fragmentation is the type of defect that most frequently found in the radius after trauma, the injuries very often being peripheral. For these cases, which are not surface defects, chondrocyte culture or microfracture techniques are not a solution. Moreover, both for autografts and allografts, the ideal situation is one characterized by central defects in a mortise where the graft can be placed^{4,27,28}.

For peripheral defects in other areas of the hand, autologous osteochondral non-vascularized grafts have been used, chiefly in post-trauma defects, obtaining satisfactory results in the short term^{9,10}. However, in the longer term, some grafts have been reabsorbed, especially if they were large (fig.6). In point of fact, one of the advocates of the technique, Ishida⁹, does not recommend the technique when defects are larger than half an interphalangeal (0.5 cm). The

size of the defects that have to be reconstructed in the radius is much greater than this measure. Mekhail²⁹ measured the surface that contained cartilage in the distal end of the radius: the lunate fossa was a quadrangular polygon of around 14mm, and the scaphoid fossa was a triangle with 15mm sides.

It was taking into account those studies that show that the nourishment of, at least, the deep layers of the cartilage depends on the vascularization of the subchondral bone^{14,15,19,20} and that large grafts are necessary, that we started the search for an appropriate donor site. After considering various sites we found a morphometric similarity between the base of the 3rd metatarsal and the distal end of the radius: the base of the metatarsal is roughly comparable to the lunate or scaphoid fossas. In all cases the study of vascularization showed the existence of periostic vessels in the base of the 3rd metatarsal that were dependent of the arcuate artery and/or the tarsal laterodistal, both of which in turn depended on the pedal artery, which could be used as donor vessel²¹.

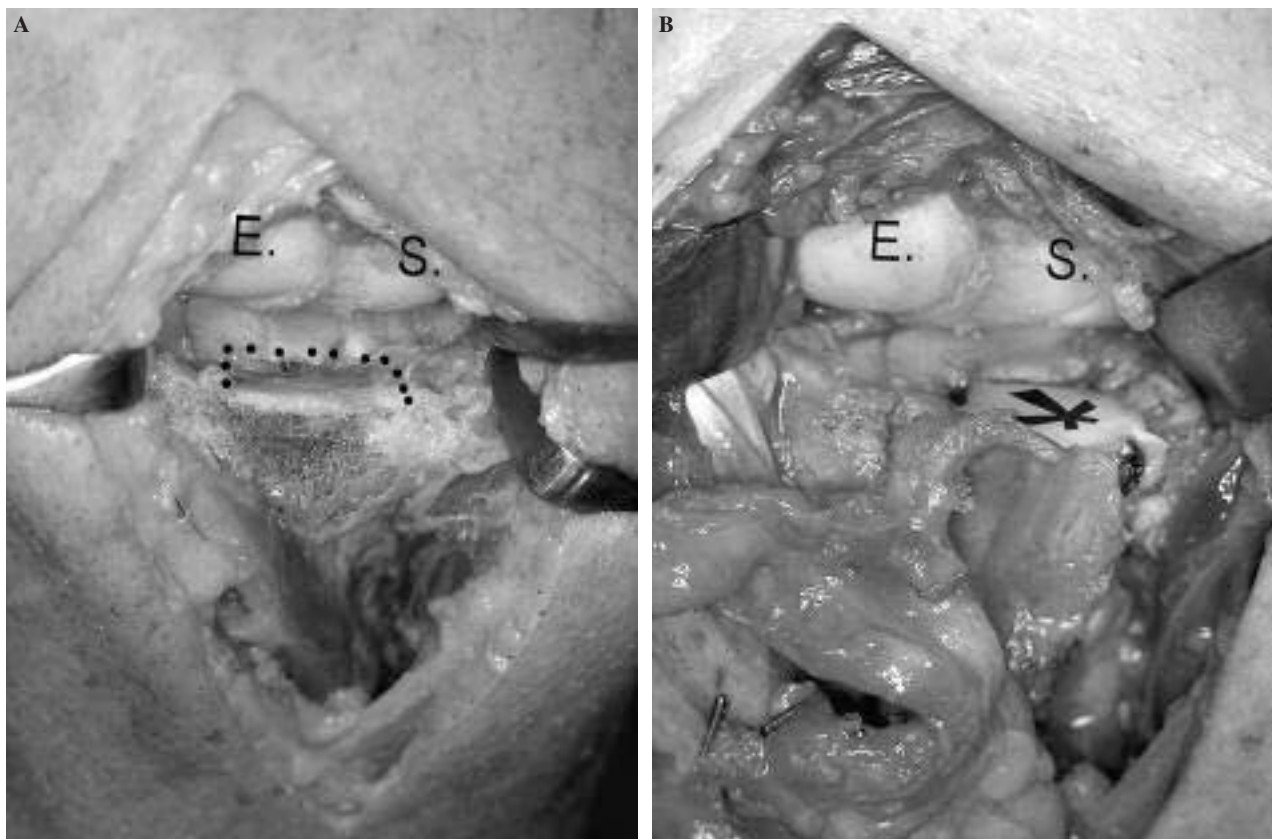


Figure 3. Intra-op detail of case N°2. Wrist has been approached dorsally, between the long thumb extensor, freed radially and the finger extensors, freed from the ulna. (A) The excision of the most distal portion of the posteroulnar fragment allows the view of the scar area that has no cartilage and that affects the two posterior thirds of the lunate fossa (bounded with dots); the cartilage nearest the volar region (anterior to dotted line) is normal. (B) The osteochondral flap of the 3rd metatarsal (asterisk) has been synthesized, replacing the affected area. E: scaphoid; S: lunate.

The results we obtained with the osteochondral vascularized graft were more satisfactory than those obtained with partial arthrodesis (radio-lunate or radio-scaphoid arthrodesis with excision of the scaphoid distal pole), and it had a minimum negative donor effect (fig. 7). Nevertheless, our series is small and follow-up is short, due to which, despite our optimism, we are aware that these results must be interpreted with caution. In our experience the vascularized osteochondral graft plays an important role when the joint injury lies within the facet joint of the radius.

If, instead, the scaphoid or lunate surface is eroded, this method is not advised, the chosen method in this case being modified radio-scapho-lunate arthrodesis³, radio-lunate¹, or even total arthrodesis. In those cases in which there is subsidence of an isolated fragment but the cartilage still remains, we prefer reposition of the fragment after osteotomy, be it inwards as is advocated by González del Pino²⁵ and Ring²⁶, or with direct arthroscopic view and outwards, as we ourselves prefer^{30,31}.

The flap elevation technique is not simple, due to anatomic variation and periostic vessel frailty, and it re-

quires experience in microsurgery, although donor vessels are large. In line with this approach, we have applied the concept of vascularized osteochondral graft in the reconstruction of partial defects in the finger joints, taking small vascularized fragments from foot phalanxes. Results as regards mobility and joint space have been favorable. It is possible that other anatomic areas may be reconstructed once more donor sites have been found.

In conclusion, our experience in the reconstruction of massive irreparable defects of the distal radio facet joint by means of an osteochondral graft has been functionally positive, yielding a reduction of pain and scanty negative donor effects. The presence of injuries in the joint facet of the scaphoid or lunate proximal pole, renders this technique unadvisable, however.

Since this work was sent we have performed two more reconstructions of the lunate fossa. The follow-up periods of all five cases vary between 1 and 4 years. Clinical results have remained unchanged without there appearing signs of degeneration in radiographic controls.

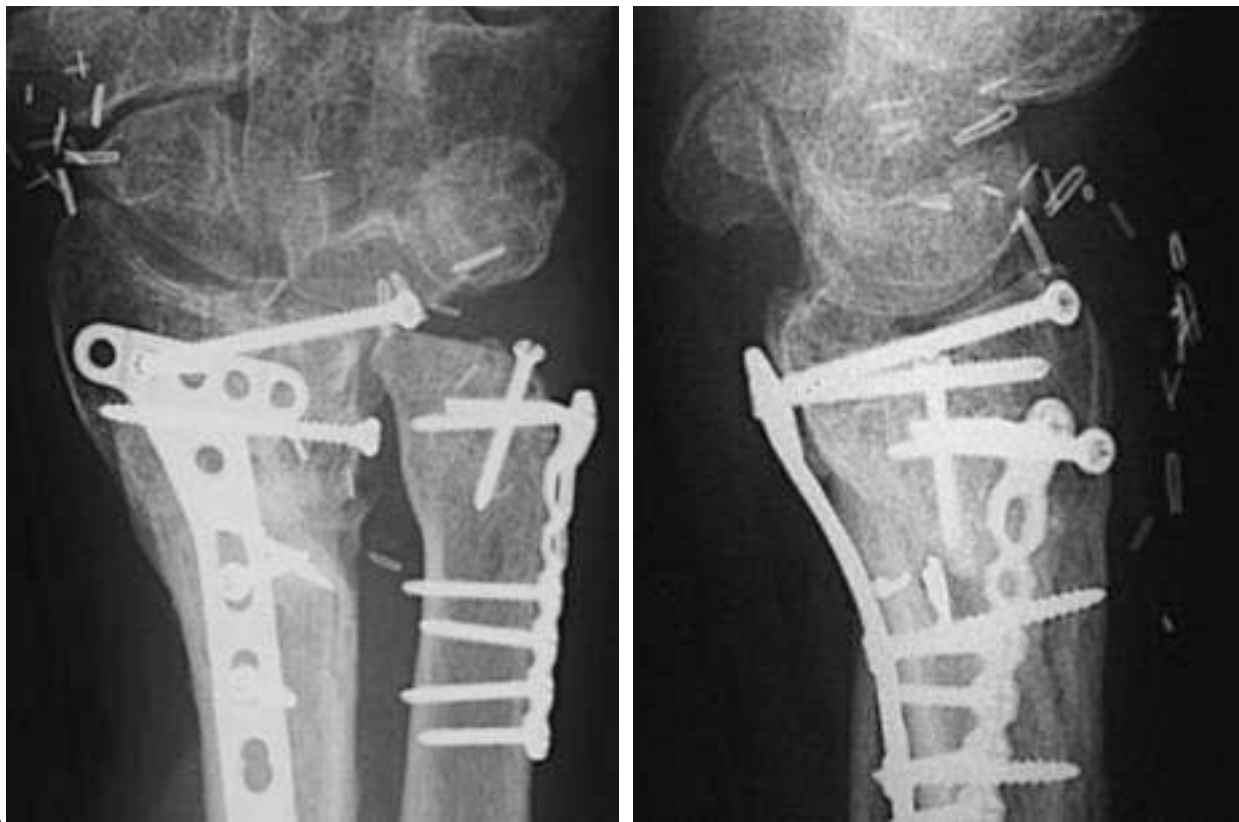


Figure 4. (A and B) Posteroanterior and lateral x-rays of case N°2 after a period of 8 months. Graft is fixed with two posteroulnar screws (the rest of the material corresponds to the first surgery). The ulna was shortened concomitantly to the transplant in the median third of the diaphysis (not shown in x-ray).

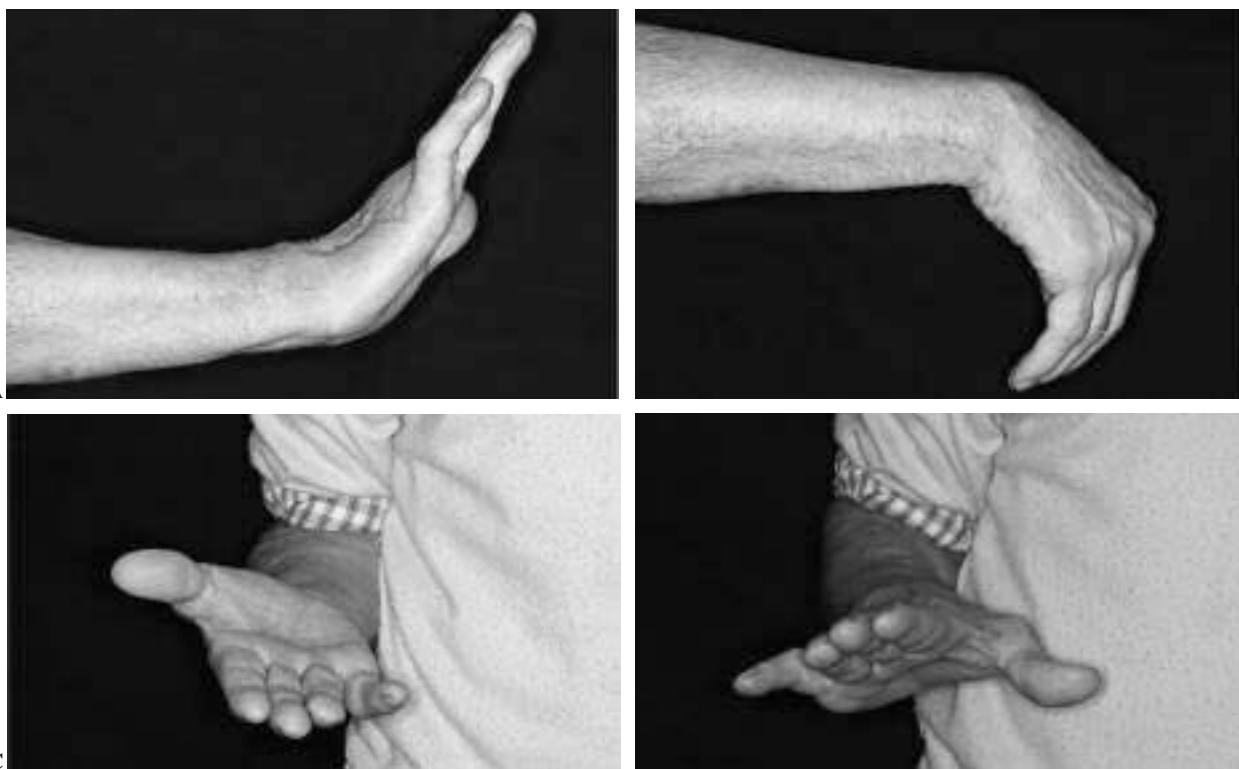


Figure 5. Same case as in figure 4. (A-D) Results after a period of 10 months.

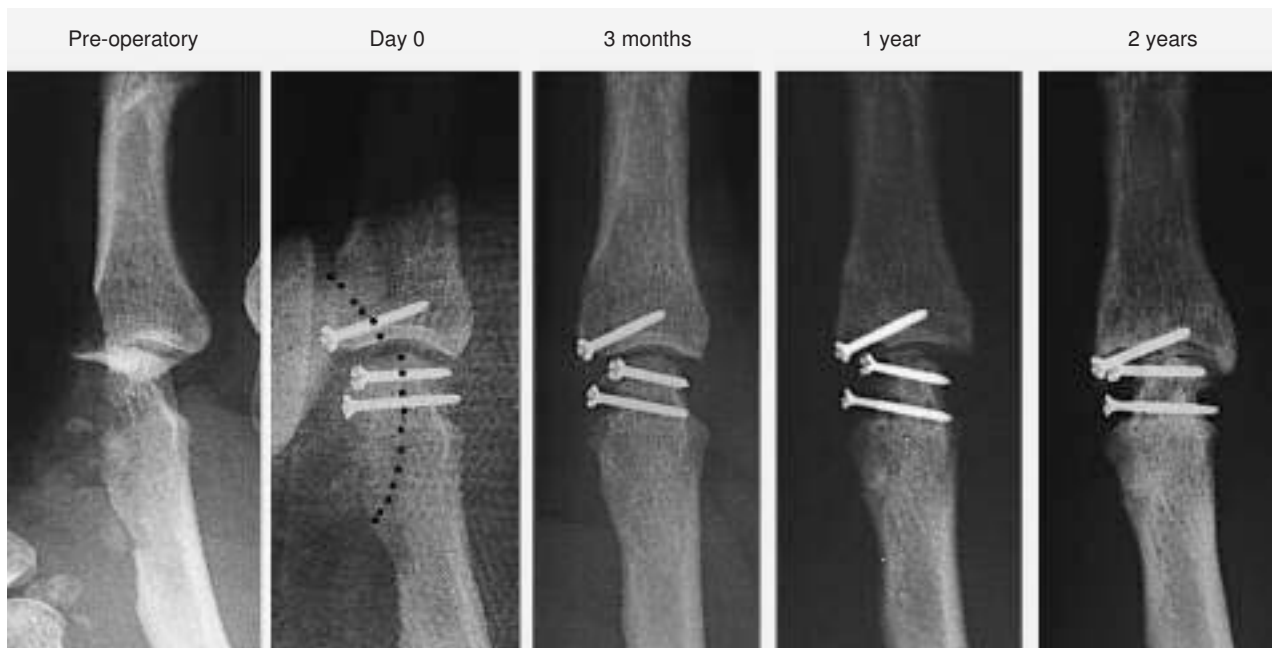

Figure 6. From left to right, re-absorption of small non-vascularized osteochondral bone graft, taken from foot metatarsal. Measurements went from 70° after three months, to 20° after a year, and 0° after 2 years.

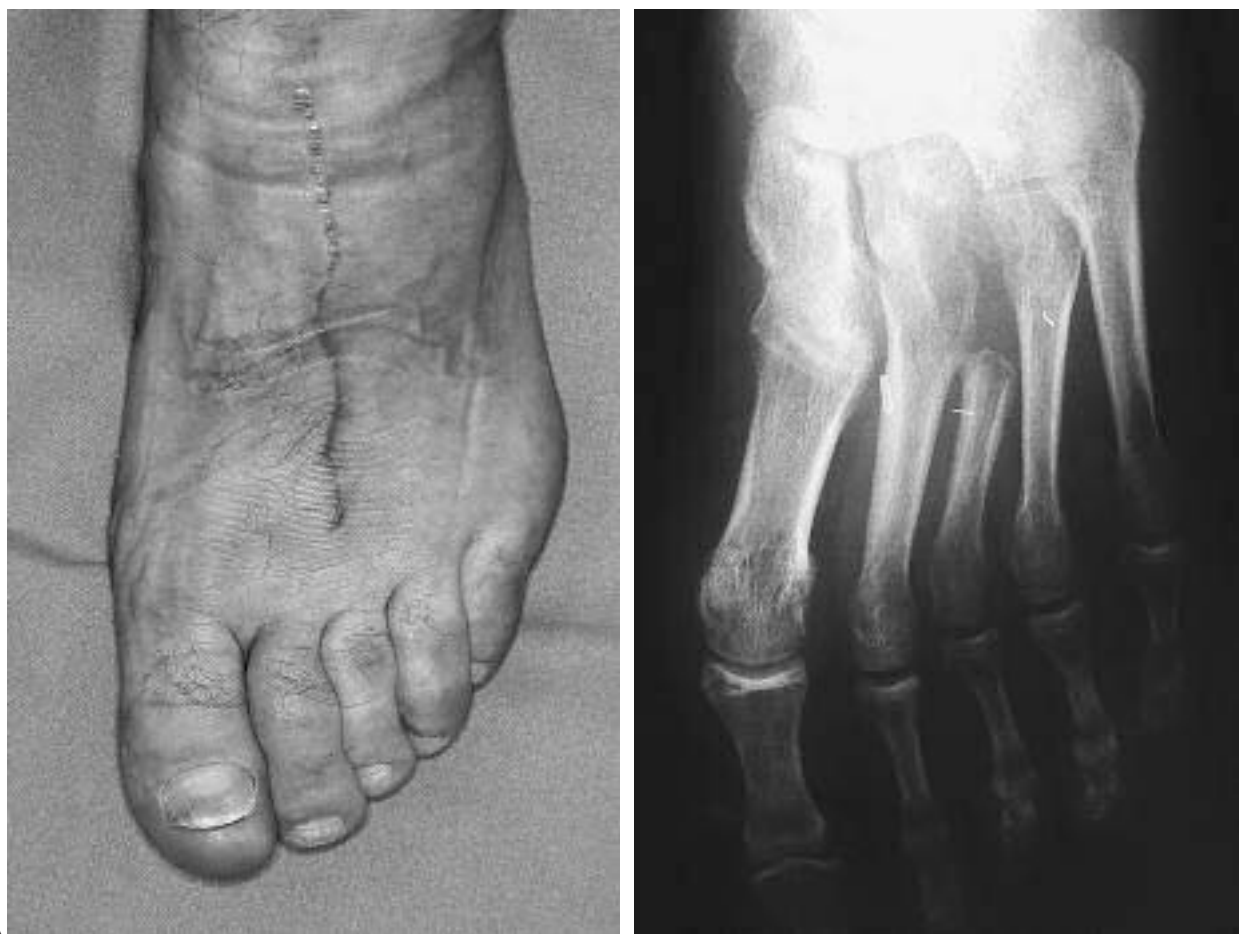

Figure 7. (A) Donor site of case N°2 patient. (B) X-ray showing excision of 3rd metatarsal.

REFERENCES

1. Saffar P. Radio-lunate arthrodesis for distal radial intraarticular malunion. *J Hand Surg (Br)*. 1996;21B:14-20.
2. Nagy L, Büchler U. Long-term results of radioscapholunate fusion following fractures of the distal radius. *J Hand Surg (Br)*. 1997;22B:705-10.
3. García-Elías M, Lluch A, Ferreres A, Papini-Zorli I, Rahimtoola ZO. Treatment of radiocarpal degenerative osteoarthritis by radioscapholunate arthrodesis and distal scaphoidectomy. *J Hand Surg (Am)*. 2005;30A:8-15.
4. Hangody L, Fules P. Autologous osteochondral mosaicplasty for the treatment of full-thickness defects of weight-bearing joints: ten years of experimental and clinical experience. *J Bone Joint Surg Am*. 2003;85A Suppl 2:25-32.
5. Brittberg M, Peterson L, Sjogren-Jansson E, Tallheden T, Lindahl A. Articular cartilage engineering with autologous chondrocyte transplantation. A review of recent developments. *J Bone Joint Surg Am*. 2003;85A Suppl 3:109-15.
6. Bentley G, Biant LC, Carrington RW, Akmal M, Goldberg A, Williams AM, et al. A prospective, randomised comparison of autologous chondrocyte implantation versus mosaicplasty for osteochondral defects in the knee. *J Bone Joint Surg Br*. 2003;85B:223-30.
7. Knutsen G, Engebretsen L, Ludvigsen TC, Drogset JO, Grøntvedt T, Solheim E, et al. Autologous chondrocyte implantation compared with microfracture in the knee. A randomized trial. *J Bone Joint Surg Am*. 2004;86A:455-64.
8. Mehini R, Giachino AA, Backman D, Grabowski J, Fazekas A. Autologous osteoarticular transfer from the proximal tibiofibular joint to the scaphoid and lunate facets in the treatment of severe distal radial fractures: a report of two cases. *J Hand Surg (Am)*. 2003;28A:332-41.
9. Ishida O, Ikuta Y, Kuroki H. Ipsilateral osteochondral grafting for finger joint repair. *J Hand Surg (Am)*. 1994;19A:372-7.
10. Boulas HJ. Autograft replacement of small joint defects in the hand. *Clin Orthop*. 1996;(327):63-71.
11. Ferracini R, Gino G, Battiston B, Linari A, Franz R, Bertolo S. Assessment of vascularized fibular graft one year after reconstruction of the wrist after excision of a giant-cell tumour. *J Hand Surg (Am)*. 1999;24B:497-500.
12. Sledge C, Reddi AH, Walsh DA, Blake DR. Biology of the normal joint. En: Ruddy S, Harris ED Jr, Sledge CB, editors. *Kelley's textbook of rheumatology*. 6th ed. Philadelphia: Saunders; 2001. p. 1-21.
13. Ulrich-Vinther M, Maloney MD, Schwarz EM, Rosier R, O'Keefe RJ. Articular cartilage biology. *J Am Acad Orthop Surg*. 2003;11:421-30.
14. Tsubokawa N, Yoshizu T, Maki Y. Long-term results of free vascularized second toe joint transfers to finger proximal interphalangeal joints. *J Hand Surg (Am)*. 2003;28A:443-7.
15. Dautel G, Gouzou S, Vialaneix J, Faivre S. PIP reconstruction with vascularized PIP joint from the second toe: minimizing the morbidity with the "dorsal approach and short-pedicle technique". *Tech Hand Upper Extrem Surg*. 2004;8:173-80.
16. Entin MA, Alger JR, Baird RM. Experimental and clinical transplantation of autogenous whole joints. *J Bone Joint Surg Am*. 1962;44A:1518-36.
17. Kettelkamp DB. Experimental autologous joint transplantation. *Clin Orthop*. 1972;(87):138-45.
18. Yoshizu T, Watanabe M, Tajima T. Étude expérimentale et applications cliniques des transferts libres d'articulation d'orteil avec anastomoses vasculaires. En: Tubiana R, éditeur. *Traité de chirurgie de la main*. Vol. 2. Paris: Masson; 1984. p. 539-51.
19. Poole AR. What type of cartilage repair are we attempting to attain? *J Bone Joint Surg Am*. 2003;85A Suppl 2:40-4.
20. Imhof H, Sulzbacher I, Grampp S, Czerny C, Youssefzadeh S, Kainberger F. Subchondral bone and cartilage disease: a rediscovered functional unit. *Invest Radiol*. 2000;35:581-8.
21. Piñal F, García-Bernal FJ, Delgado J, Sanmartín M, Regalado J. Reconstruction of the distal radius facet by a free vascularized osteochondral autograft: anatomic study and report of a patient. *J Hand Surg (Am)*. 2005;30A:1200-10.
22. Espinar Salom E. Sistemas de valoración de los resultados clínicos en la cirugía del pie. En: Núñez-Samper Pizarroso M, Llanos-Alcázar LF, Viladot Pericé R, editores. *Técnicas quirúrgicas de cirugía del pie*. Barcelona: Masson; 2003. p. 361-70.
23. Knirk JL, Jupiter JB. Intra-articular fractures of the distal end of the radius in young adults. *J Bone Joint Surg Am*. 1986;68A:647-59.
24. Marx RG, Axelrod TS. Intraarticular osteotomy of distal radius malunions. *Clin Orthop*. 1996;(327):152-7.
25. González del Pino J, Nagy L, González Hernández E, Bartolomé del Valle E. Osteotomías intraarticulares complejas del radio por fractura. Indicaciones y técnica quirúrgica. *Rev Ortop Traumatol*. 2000;44:406-17.
26. Ring D, Prommersberger KJ, González del Pino J, Capomassi M, Slullitel M, Jupiter JB. Corrective osteotomy for malunited articular fractures of the distal radius. *J Bone Joint Surg Am*. 2005;87A:1503-9.
27. Palazzi Coll S, Palazzi Coll C, Palazzi Duarte AS. Osteocartilaginous autograft of the knee. *Int Orthop*. 1977;1:48-52.
28. Shasha N, Krywulak S, Backstein D, Pressman A, Gross AE. Long-term follow-up of fresh tibial osteochondral allografts for failed tibial plateau fractures. *J Bone Joint Surg Am*. 2003;85A Suppl 2:33-9.
29. Mekhail AO, Ebraheim NA, McCreath WA, Jackson WT, Yeasting RA. Anatomic and X-ray film studies of the distal articular surface of the radius. *J Hand Surg (Am)*. 1996;21A:567-73.
30. Del Piñal F, García-Bernal FJ, Delgado J, Regalado J, Sanmartín M, Pisani D. Técnica para el tratamiento de la malunión intra-articular del radio mediante osteotomías con control artroscópico. *Rev Iberoamer Cir Mano*. 2005;33:38-43.
31. Del Piñal F, García-Bernal FJ, Delgado J, Sanmartín M, Regalado J, Cerezal L. Correction of malunited intra-articular distal radius fractures with an inside-out osteotomy technique. *J Hand Surg (Am)*. 2006;31:1029-34.

Conflict of interests

The authors have declared that they have no conflict of interests.