

## CASE REPORTS

# Spontaneous pneumomediastinum following a motorcycle accident. Report on a case and review of the literature

P.L. Esteban Navarro<sup>a,\*</sup>, A.M. Morales Codina<sup>a</sup> and M. Iglesias Sentís<sup>b</sup>

<sup>a</sup>Department of Orthopedic and Trauma Surgery, Sabadell Hospital, Corporació Sanitària Parc Taulí, Sabadell, Barcelona, Spain

<sup>b</sup>Department of Thoracic Surgery, Occupational Accidents Hospital, Terrassa, Barcelona, Spain

Received July 15, 2008; accepted October 21, 2008

Available on the internet from February 25, 2009

### KEYWORDS

Mediastinal emphysema;  
Neck pain;  
Motorcycle

### Abstract

*Introduction:* The spontaneous pneumomediastinum is an extremely rare condition. We hereby present a case of this pathology.

*Clinical case:* 17 year-old man who suffered a low-energy motorcycle accident and came into the emergency department complaining of headache and neck pain. Physical examination showed echolalia and retrograde amnesia and crepitation on the anterior and right lateral part of the neck. No other physical signs were found. Plain radiographs and a CT-scan showed air in the right jugular vein. With the diagnosis of spontaneous pneumomediastinum, the patient remained under observation. With rest and analgesia the patient improved within the next hours and was discharged without any complication. The case is presented and the literature is reviewed.

*Conclusions:* Spontaneous pneumomediastinum is a normally benign pathology that tends to resolve favorably without any treatment.

© 2008 SECOT. Published by Elsevier España, S.L. All rights reserved.

### PALABRAS CLAVE

Enfisema mediastínico;  
Dolor de cuello;  
Motocicleta

### Neumomediastino espontáneo tras accidente de motocicleta. Caso clínico y revisión de la literatura


### Resumen

*Introducción:* el neumomediastino espontáneo es una entidad muy rara. Presentamos un caso de esta enfermedad.

*Caso clínico:* varón de 17 años de edad que, tras sufrir un accidente de motocicleta de baja energía, acudió a urgencias por cefalea relacionada con dolor en el cuello. En la

\*Corresponding author.

E-mail: plesteban@tauli.cat (P.L. Esteban Navarro).



exploración física se apreciaba ecolalia, así como amnesia retrógrada del episodio. Destacaba una crepitación a la palpación en la región anterior y lateral derecha del cuello. El resto de la exploración física por aparatos fue normal. Las pruebas de imagen realizadas mostraron aire en el trayecto de la vena yugular derecha. Con el diagnóstico de neumomediastino espontáneo, el paciente quedó ingresado en observación. Con el reposo y la medicación analgésica mejoró en las horas siguientes y se pudo darle el alta sin incidencias. Se presenta el caso y se hace una revisión de la literatura.

*Conclusiones:* el neumomediastino espontáneo normalmente es una enfermedad benigna que suele resolverse favorablemente sin tratamiento.

© 2008 SECOT. Publicado por Elsevier España, S.L. Todos los derechos reservados.

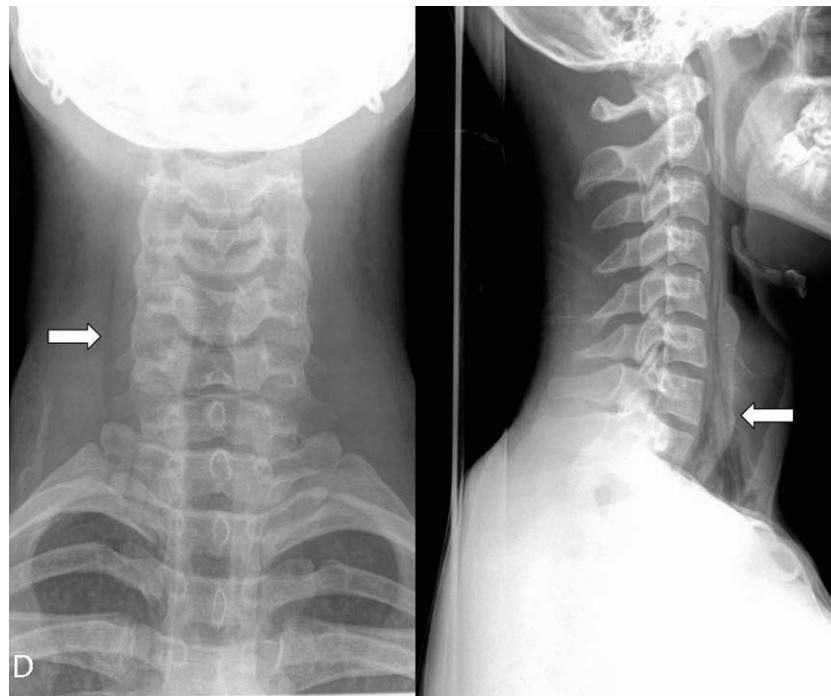
## Introduction

Spontaneous pneumomediastinum is defined as the appearance of air in the mediastinum. It is an unusual clinical entity, although its actual incidence remains unknown<sup>1</sup>.

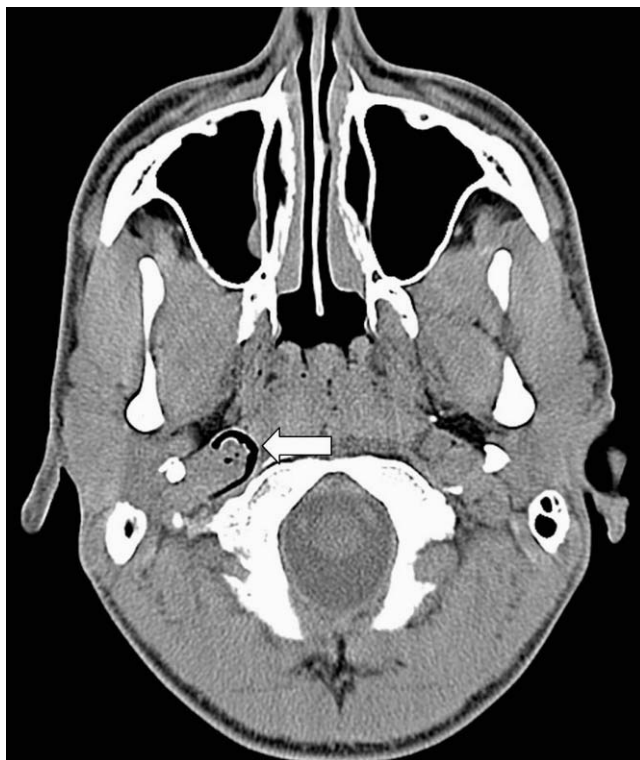## Clinical case

The patient is a 17-year-old male with no relevant past medical history who presented at the Emergency Department a few hours after being involved in a traffic accident (while driving a motorcycle he sustained a posterior collision with a stationary motorcycle). The patient complained of a right fronto-parietal headache with irradiation to the right anterolateral aspect of the neck, reaching the supraclavicular region. During physical examination, the patient was

conscious, oriented to time and place, echolalic and suffered from retrograde amnesia. Subcutaneous crepitation was observed on the right anterolateral aspect of the neck, medially to the sternocleidomastoid muscle. Neck mobility was complete and painless. He was able to move all 4 limbs. Respiratory auscultation was uneventful. A two-plane cervical spine radiograph was performed, which revealed the presence of air in the area previously described (fig. 1). Chest radiographs were not indicative of any pathology. A skull CT-scan was requested, which showed air in the right jugular foramen (fig. 2). Initial diagnosis was spontaneous pneumomediastinum caused by the rupture of an apical pulmonary vesicle, which dissected the sheath of the jugular vein. The patient was admitted for observation and was administered analgesic treatment (paracetamol and ibuprofen). In the next few hours, the patient recovered from echolalia and experienced an abatement of his headache and neck pain. At 12 hours from admission, new



**Figure 1** Anteroposterior and lateral cervical spine radiographs showing presence of air in the right anterior cervical region (arrows).



**Figure 2** Skull CT-scan showing air in the right jugular foramen (arrow).

cervical spine radiographs were performed that showed a reduction of the air-filled areas. Inspiration/exhalation chest radiographs did not show signs of pleuropulmonary invasion. The patient was discharged with no complications.

## Discussion

Spontaneous pneumomediastinum was first described in 1617 by Bourgeois. Hamman described the so-called "Hamman's crunch," a rasping sound, synchronous with heart beat, caused by the presence of air in the mediastinum. Subcutaneous emphysema and pneumomediastinum occur more commonly in patients that have sustained thoracic trauma (costal fracture) or neck trauma (open or closed), or in the context of soft tissue infection. Nevertheless, they may appear in connection with any condition that creates a gradient between intraalveolar and perivascular interstitial pressure. Macklin et al<sup>2</sup> suggested that a pressure gradient between the pulmonary periphery and the hilum could result in the rupture of terminal alveoli and the subsequent dissection of the air along the mediastinal vessels, the pleural cavity and the neck. It must be remembered that a continuation of fascial planes connects the soft tissues of the neck to the mediastinum and the retroperitoneum, and allows an abhorrent leakage of air from any of those areas to extend to any region of the body<sup>3</sup>. Diagnosis of subcutaneous emphysema is chiefly symptom-based (crepitation on palpation) and must be confirmed by a

radiologic study. The presence of air in the subcutaneous tissue or in the mediastinum is not dangerous in itself, but it is of essence to recognize its underlying cause. Spontaneous pneumomediastinum occurs most frequently in young males (mean age: 18 years)<sup>1,4</sup>. The risk factors related to this condition are: substance abuse (ecstasy<sup>5</sup>), sport activity (weight-lifting, related to the Valsalva maneuver<sup>6</sup>) and an acute episode of bronchial asthma<sup>7</sup>. The majority of authors agree that spontaneous pneumomediastinum is a benign condition that often resolves spontaneously within 3-10 days. Bed-rest, observation and analgesia are recommended. Antibiotics have been used in cases where mediastinitis is suspected<sup>4</sup>. The literature contains many clinical cases of subcutaneous emphysema in the neck originated in a dental procedure<sup>8</sup>; most of these are related to inadvertent introduction of air via a power-operated instrument. Other cases have been reported following minimal facial trauma. In some cases, the origin of the subcutaneous emphysema must be traced back to the chest<sup>9</sup>. In our literature review for this case, we found one case where a pseudomediastinum presented in the form of an isolated subcutaneous emphysema in the neck<sup>10</sup>. We believe that the case herein belongs in this same category: there was no thoracic trauma and the patient denied taking psychotropic substances; leakage of air was attributed the rupture of an apical pulmonary bulla, in all likelihood occurring as a result of a Valsalva maneuver that created a gradient between the intraalveolar and perivascular interstitial pressure. The connection of fascial planes between the soft tissues of the neck and the mediastinum permitted the appearance of subcutaneous emphysema. As the patient was young, and had no history of pulmonary involvement, the condition evolved favorably in a spontaneous way.

## Conflict of interests

The authors have declared that they have no conflict of interests.

## References

1. Mihos P, Potaris K, Gadikis I, Mazaris E, Sarras E, Montos Z. Sports-related spontaneous pneumomediastinum. *Ann Thorac Surg.* 2004;78:983-6.
2. Macklin MT, Macklin CC. Malignant interstitial emphysema of the lungs and mediastinum an important occult complication in many respiratory diseases and other conditions: an interpretation of the clinical literature in the light of laboratory experiment. *Medicine.* 1994;23:281-358.
3. Maunder RJ, Pierson DJ, Hudson LD. Subcutaneous and mediastinal emphysema. Pathophysiology, diagnosis, and management. *Arch Intern Med.* 1984;144:1117-53.
4. Koullias GJ, Dimitris KP, Wang XJ, Hammond GL. Current assessment and management of spontaneous pneumomediastinum: experience in 24 adult patients. *Eur J Cardiothorac Surg.* 2004; 25:852-5.
5. Harris R, Joseph A. Spontaneous pneumomediastinum ecstasy: a hard pill to swallow. *Aust N Z J Med.* 2000;30:401-3.
6. Asplund C, Howard T, O'Connor F. Spontaneous pneumomediastinum in a weightlifter. *Curr Sports Med.* 2003;2:63-4.

7. Macia I, Moya J, Ramos R, Morera R, Escobar I, Saumench J, et al. Spontaneous pneumomediastinum: 41 cases. *Eur J Cardiothorac Surg.* 2007;31:1110-4.
8. Monsour PA, Savage NW. Cervicofacial emphysema following dental procedures. *Aust Dent J.* 1989;34:403-6.
9. Hutchison RP, Burgess B. Spontaneous pneumomediastinum a right pain in the neck?. *Injury.* 2005;36:801-3.
10. Ramchandar K, Carr MM. Spontaneous facial subcutaneous emphysema. *Ear Nose Throat J.* 2006;85:744-6.