

ORIGINAL ARTICLE

Fresh bipolar osteochondral allograft of the ankle. Review of the literature and case report of a young patient with bilateral post-traumatic osteoarthritis[☆]

R. Pimenta^{a,b,*}, P. Carvalho^a, P. Amado^{a,b}

^a *Unidad de Tobillo-Pie, Instituto CUF, Porto, Portugal*

^b *Facultad de Ciencias de la Salud, Universidad Fernando Pessoa, Porto, Portugal*

Received 16 October 2011; accepted 8 November 2011

KEYWORDS

Post-traumatic arthritis;
Ankle;
Cartilage;
Osteochondral allograft

Abstract

Objectives: The treatment of severe post-traumatic ankle arthritis remains a challenge nowadays. Since patients suffering from this pathology are mainly young and active people, a correct reconstruction, if possible, of the articular cartilage defects of the tibiotalar joint is very important to achieve a good result. Fresh bipolar osteochondral allograft (FBOA) is a promising operative technique, as an alternative to arthrodesis and total ankle replacement, in pain relief, restoration of function and indefinite delay of arthritic disease progression.

Methods: The authors made a review of the literature and present a case report of a young 30-year-old man, with bilateral post-traumatic osteoarthritis of the ankle, treated with (FBOA). The patient was evaluated clinically and radiographically monthly.

Results: Pain relief and postoperative function was significantly improved reaching 94 points in the left ankle (preoperative of 40 points), and 92 points in the right ankle (preoperative 42 points) AOFAS score.

Conclusions: Fresh tibiotalar allografting seems to be a good alternative to arthrodesis and prosthetic replacement, in the treatment of ankle arthropathy and big articular cartilage defects mainly in young and active patients. This procedure achieves a good pain relief, maintaining functional joint motion and decreasing the risk of adjacent joint arthritis.

© 2011 SECOT. Published by Elsevier España, S.L. All rights reserved.

[☆] Please cite this article as: Pimenta R, et al. Aloinjerto osteocondral bipolar fresco del tobillo. Revisión de la literatura y presentación del caso de un paciente joven con artrosis bilateral postraumática. Rev Esp Cir Ortop Traumatol. 2012;56(2):120–6.

* Corresponding author.

E-mail addresses: ruipimentaribeiro@gmail.com, pamado@ufp.edu.pt (R. Pimenta).

PALABRAS CLAVE

Artrosis
postraumática;
Tobillo;
Cartílago;
Aloinjertos
osteocnrales

Aloinjerto osteocondral bipolar fresco del tobillo. Revisión de la literatura y presentación del caso de un paciente joven con artrosis bilateral postraumática

Resumen

Objetivo: El tratamiento de la artrosis postraumática grave del tobillo sigue siendo un reto en nuestros días. Dado que los pacientes afectados de esta afección son frecuentemente jóvenes y activos, la reconstrucción apropiada de los defectos articulares de la articulación tibio-astragalina, si es posible, es muy importante para obtener un buen resultado. Los aloinjertos osteocnrales bipolares frescos (ABOF) constituyen una técnica quirúrgica prometedora, como una alternativa a la artrodesis o a la artroplastia de tobillo en cuanto al alivio de dolor, recuperación funcional y retraso de la progresión a la artrosis.

Método: Se realiza una revisión de la literatura y se presenta el caso de un paciente varón de 30 años con artrosis bilateral postraumática del tobillo tratado con ABOF; el paciente fue revisado clínica y radiográficamente cada mes durante 15 meses.

Resultados: Tanto el dolor como la función post-operatoria mejoraron de forma significativa, alcanzando 94 puntos en el tobillo izquierdo (puntuación preoperatoria de 40 puntos) y 92 puntos en el tobillo derecho (puntuación preoperatoria de 42 puntos).

Conclusiones: El aloinjerto tibio-astragalino fresco parece ser una buena alternativa a la artrodesis o a la artroplastia en el tratamiento de la artropatía degenerativa del tobillo y de los defectos condrales articulares, principalmente en pacientes jóvenes y activos. Esta técnica consigue un buen alivio del dolor, mantiene buena movilidad articular y disminuye el riesgo de artrosis de las articulaciones adyacentes.

© 2011 SECOT. Publicado por Elsevier España, S.L. Todos los derechos reservados.

Introduction

Osteoarthritis of the ankle can be secondary to any number of causes, including idiopathic osteoarthritis, systemic polyarthritis, such as rheumatoid arthritis and other polyarthritides, and post-traumatic osteoarthritis. Post-traumatic osteoarthritis is the most common form, accounting for more than 70% of all cases of osteoarthritis of the ankle.¹ Together with that, there are several reasons that make osteoarthritis of the ankle a different disease from osteoarthritis of the hip or knee: patients are generally younger and the weight-bearing articular surface is significantly smaller, causing greater pressure per unit of surface area; the ankle is surrounded by a fine layer of soft tissue, which can lead to serious complications in skin healing.²

Lesions of the articular cartilage of the tibio-astragaline joint and secondary osteoarthritis of the ankle often cause pain, limited mobility, and functional disability. The surgical options when conservative treatment fails are limited. For a long time, arthrodesis has been considered to be the standard for comparison due to its ability to achieve satisfactory relief of pain,³ although it does entail inherent functional limitations,⁴ affects overall gait efficiency, and leads to predictable, progressive osteoarthritis of the ipsilateral hindfoot.⁵ Total arthroplasty of the ankle conserves joint mobility, with improvement in the gait, decreasing the overloading affecting neighboring joints, although it does not appear to achieve the same level of success and survival rate as other arthroplasties of the lower limb,^{6,7} especially in young, active patients,⁸ thanks to a high rate of mobilization of the components. These issues provoke the search for a method to repair the osteoarthritic joint. The use of frozen allografts as a salvage procedure in the treatment

of malignant bone tumors, on their own or in combination with prostheses, has also been well documented.⁹

Material and method

We present the case of a 30-year-old male patient with bilateral post-traumatic osteoarthritis of the ankle. At 18 years of age, the patient fell from a height of some 15m while jumping from one balcony to another, suffering several limb fractures. His left ankle presented a fracture of the medial malleolus and astragalus, and his right ankle suffered bimalleolar and astragalus fractures. All the fractures were treated surgically: on the left ankle, osteotaxis was performed in association with osteosynthesis of the medial malleolus and the astragalus, whereas on the right ankle, osteosynthesis of the astragalus and both malleoli was carried out. All fractures consolidated and the osteosynthesis material was removed three years later.

However, the patient developed serious post-traumatic osteoarthritis of both ankles (Figs. 1 and 2), with significant functional limitation that forced him to use insoles on the outer edge of both feet to improve support, as well as the formation of hyperkeratosis on the lateral edges of his feet.

At the age of 29, he requested surgery to treat his serious disorder and limited gait. The physical examination revealed mobility that was all but absent, with occasional pain that got worse when he walked, above all in his left ankle (40 points on the scale of the American Orthopedic Foot and Ankle Surgeons [AOFAS]).

As a result, in June 2010 the patient underwent a transplant with fresh bipolar allograft of the left ankle.

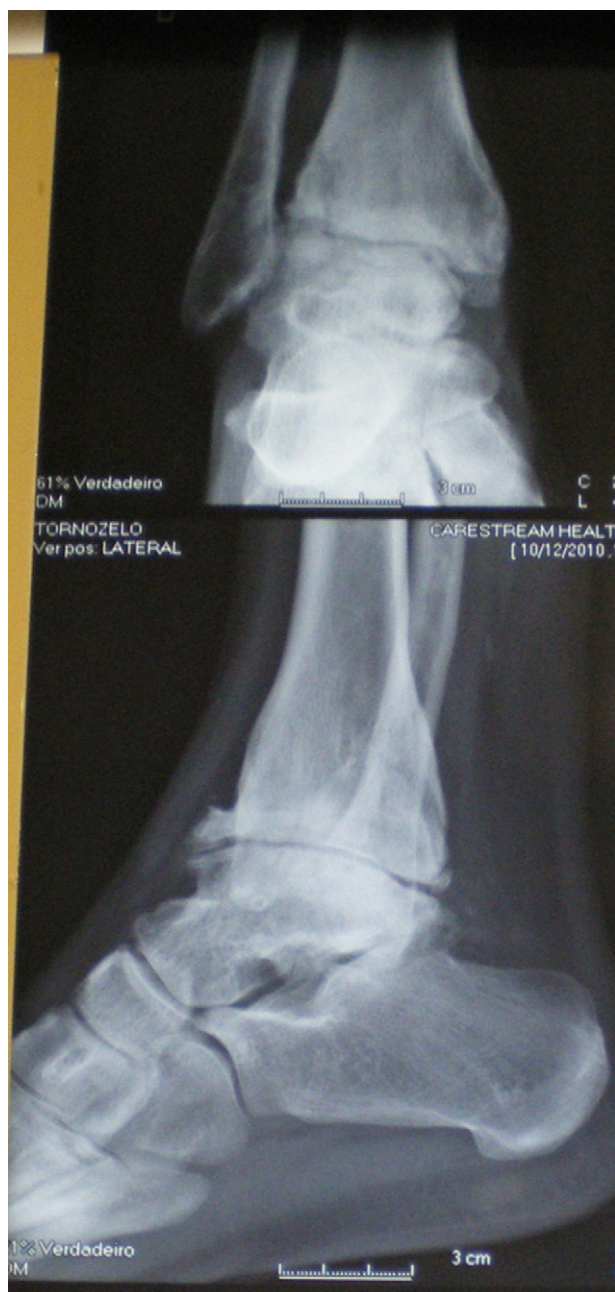

Figure 1 X-ray of the right ankle.

Surgical protocol

The pre-operative evaluation included a complete clinical history and examination, weight-bearing anteroposterior and lateral X-rays of both ankles, and a computed tomography (CT) of the left ankle. An appropriate donor was chosen based on joint size and the transplant was performed 7 days after the donor's death. Blood work was done to detect HIV, syphilis, and hepatitis B and C. The extraction of the donor's ankle consisted of resecting the entire joint, including the capsule and synovial membrane. The implant was carried out through an anterior approach of the ankle, between the anterior tibial and the *extensor hallucis longus* tendons; the neurovascular pedicle was mobilized and

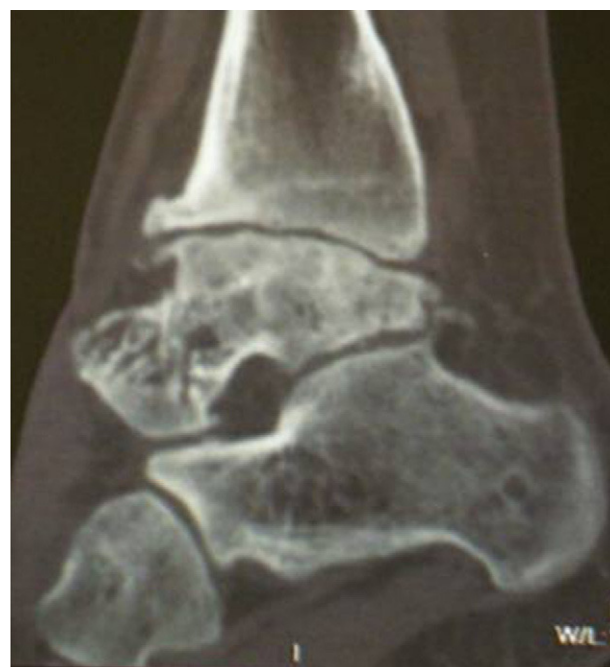

Figure 2 Computed tomography of the left ankle.

displaced laterally, severing the retinaculum longitudinally to approach the articular capsule. The cutting guide of the Agility[®] prosthesis (DePuy, Johnson & Johnson, NJ, USA) was used to perform the osteotomies of the tibia and astragalus (Fig. 3).² The medial aspect of the medial malleolus was also severed using the same guide, leaving the articular aspect of the fibular malleolus intact. The allografts were press fitted into the host bone and fixed with compression screws.

The patient remained hospitalized for one week; his foot was immobilized with a plaster boot for 4 weeks and he was not allowed to put weight on it. Beginning in the fifth week, he began to use a walking orthosis for 24 h, until the fifth post-operative month. Starting in the sixth month, the orthosis was removed and full weight-bearing was allowed.

In June 2011, one year following surgery on the left ankle, the same technique was carried out on the right ankle that presented a score of 42 on the AOFAS scale.

Results

Fifteen months following the surgery on his left ankle (Fig. 4) and three months after the intervention on his right ankle (Figs. 5 and 6), the patient is asymptomatic, walking with plantigrade support, without pain, wearing a boot-type walking orthosis 24h a day on his right leg. The physical examination shows very good mobility in the left ankle (45° plantar flexion and 25° dorsal flexion), with a score of 94 on the AOFAS scale. The right ankle presents 40° dorsal flexion and 20° plantar flexion (92 points on the AOFAS scale).

Radiographically, the host/graft bone interface is consolidated in the left ankle (Fig. 4); the weight-bearing X-ray reveals a certain narrowing of the joint interline. In the right ankle, a radio-transparent image is seen in the host bone/implant transition and the astragalus presents a

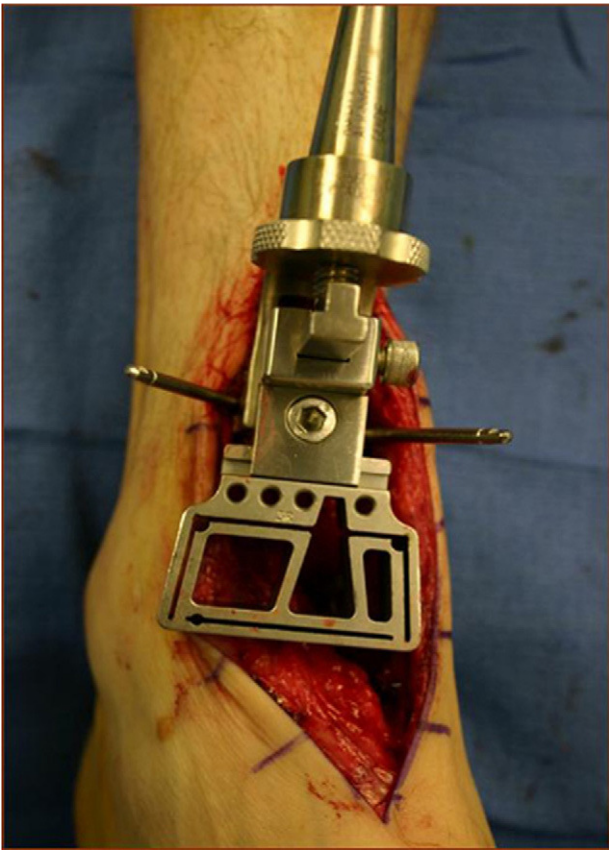


Figure 3 Cutting guide of the Agility® (DePuy, Johnson & Johnson, NJ, USA) prosthesis placed on the distal tibia in Jeng CL.²

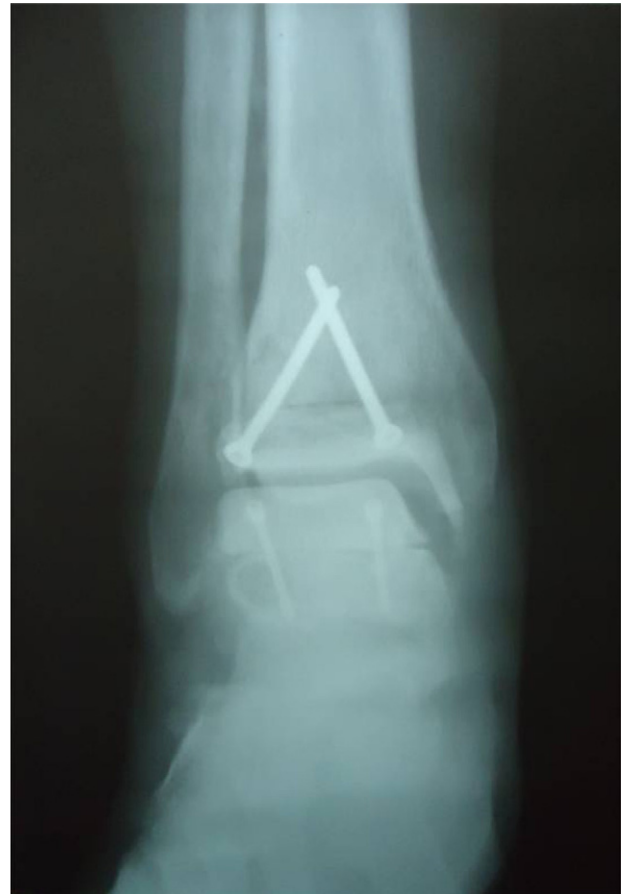

Figure 5 X-ray of the right ankle three months after surgery.

certain degree of osteocondensation (Figs. 5 and 6) three months after surgery, which could generate complications in the future, such as collapse of the graft, osteolysis, and osteonecrosis, previously described in the literature. However, for the time being, the patient is satisfied, asymptomatic, pain-free, and has good mobility in both ankles.

Discussion

Ankle joint transplants using fresh osteochondral allografts of both surfaces have been sporadically reported in the literature. The concept of biological reconstruction using osteochondral grafts represents an alternative in the treatment of degenerative articular injury. Although the

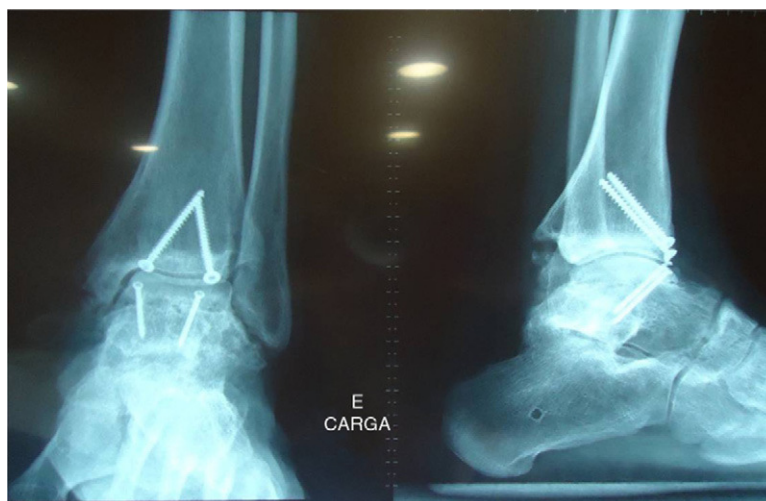

Figure 4 Weight-bearing X-ray of the left ankle 15 months after surgery.

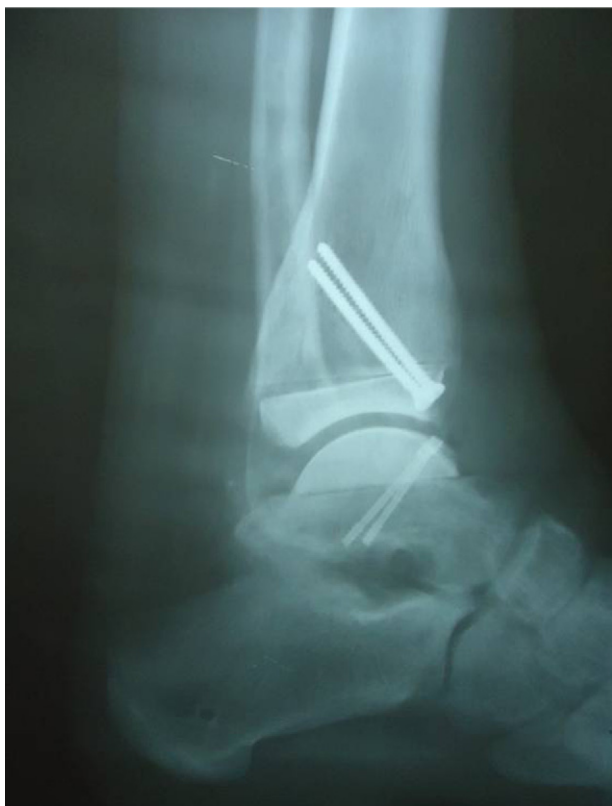

Figure 6 X-ray of the right ankle three months after surgery.

clinical use of allografts in the knee has been more widely reported, their use in other joints, such as the ankle, is still in the pipeline.⁸ Fresh osteochondral allografts are compounds consisting of viable, mature hyaline cartilage, anatomically and architecturally appropriate, anchored in acellular subchondral scaffolding, practically forming a structurally and functionally intact unit to replace the impaired or absent components corresponding to the host joint. A high percentage of chondrocytes have been shown to survive for several years after being transplanted.^{10,11} The support bone eventually consolidates with the host bone through progressive replacement.¹¹ Studies of recovered pieces have shown that the chondrocytes survive, both when stored at low temperatures^{12,13} as well as when transplanted, and they maintain their metabolic activity¹⁴ and the surrounding extracellular matrix,^{15,16} thus protecting them from host immunosurveillance.¹⁷ Nonetheless, a certain risk of disease transmission does persist.⁸

Proper patient selection is essential. The pre-operative evaluation includes a complete clinical history and full physical examination. The history must document prior trauma, surgical interventions, and co-morbidities. Furthermore, it is important to understand the patient's functional and occupational needs, as well as their expectations insofar as the outcome of the intervention is concerned. A good result of the ankle transplant depends on proper selection of the size of the allograft with respect to the host, on a meticulous preparation of the implant and of the receptor bed, maintaining proper thickness of the transplanted pieces and adequate stabilization by means of osteosynthesis.²

The ankle transplant can be performed through an anterior approach, as in this case, or through a transfibular lateral approach.^{2,9} A meticulous rehabilitation protocol is essential to achieving an adequate amplitude of movements. Our patient followed the protocol described by Giannini et al.¹⁸: two weeks with plaster, beginning continuous passive mobility immediately after removing the plaster; non-weight-bearing walking with crutches for the three first months; on the fourth month, start partial support once early signs of consolidation become apparent, allowing full support between 6 and 8 months after the surgery. At this time, the patient can be allowed to cycle and swim, with all high-impact sports prohibited for the first year.⁹

These same authors¹⁸ have conducted a post-operative evaluation of their patients by means of arthroscopy and biopsy; one year after implantation, the histological study showed few proteoglycans with disorganized collagenous fibers, but with more than 90% of the chondrocytes being viable.^{9,18} If failure is defined as having to remove the allograft from the ankle, Kim et al.²⁰ obtained a 100% survival rate at 21 months; Meehan et al.²³ achieved a survival rate of 54% at two years; Giannini et al.¹⁹, at 31 months, attained 81% survival.

In the case we report, the screws were placed from anterior and obliquely, instead of perpendicular and more posterior in the joint. This may account for a certain degree of collapse in the posterior part of the allograft (Fig. 6). Together with this, the patient began to use a walking orthosis (boot) 24h a day on week five, although partial weight-bearing was not allowed until the fifth month. Total support, with normal footwear, began around the sixth month following surgery.

In the review of the literature, we have found different modes of failure of the implant: non-union to the host bone, osteoarthritis, fracture, and collapse. The early failures were attributed to a suboptimal adaptation of the implant size and to technical mistakes, which tended to lead to fragmentation and collapse in this biomechanically highly demanding environment.^{18,19} There are other complications associated with the technique, such as intra-operative fractures (of the graft or of the fibula), poor implant fixation, sub-luxation, infection, and osteolysis. Structural failures usually occur in the first 6–12 months.⁸ The evolutive radiographic study showed joint impingement, osteophytosis, and sclerosis, even in cases with excellent clinical outcomes. If these complications appear, the surgeon must be prepared to treat them by means of articular debridement, repetition of the graft, or removal of the material. When the procedure fails, the solutions are replacement arthroplasty or arthrodesis.²⁰

Improvements in surgical technique and graft selection have yielded better short-term outcomes, but graft survival is as yet unknown. The clinical results of ankle transplants appear to be quite good initially, but deteriorate over time. Experience lowers complication rates, due to better soft tissue treatment, adequate exposure, the use of correct size grafts, cleaning of the medial and lateral outlets, avoiding impaction and better graft alignment. Giannini et al.¹⁸ consider that an accurate graft size, good adaptation and stable fixation, and delaying support are key success factors. Our patient achieved an outstanding outcome as regards pain and mobility, with 94 points on the AOFAS scale for the left

ankle and 92 for the right, although short-term results are similar to those of other authors.^{18,20,21}

Some authors believe ankle transplantation to be the primary treatment in osteochondral lesions of the astragalus and as an intervention to gain some time in salvage situations for post-traumatic osteoarthritis, secondary to arthritis, to osteonecrosis, or to haemophilic joint disease in young patients. Jeng et al.²² suggest that transplant candidates should be patients who are too young for a replacement arthroplasty, with a low body mass index, and normal limb alignment. Giannini et al.^{18,19} put forth more specific inclusion and exclusion criteria: patients under the age of 55 years; grade III unilateral osteoarthritis of the ankle; unaltered ankle anatomy; no osteopenia, rheumatoid arthritis, infection or vascular or neurological disease. Poor alignment of the limb or instability would constitute relative contraindications. Görtz et al.⁸ consider inflammatory arthritis to be a relative contraindication for the procedure; they had worse outcomes in young patients with a high body mass index, and significant pre-operative angular alteration.

The bipolar fresh osteochondral allograft (BFOA) appears to be a good alternative to arthrodesis and arthroplasty in post-traumatic osteoarthritis of the ankle. It provides pain relief and recovery of ankle joint mobility, aspects that are very important in young, active patients, who are not good candidates for arthrodesis or total arthroplasty. The distinctive advantages of the articular allograft are conservation of the bony substrate and prevention of osteoarthritis of nearby joints. The procedure entails various technical difficulties that require a long learning curve. Proper graft size selection, adaptation and stable fixation and deferring support appear to be essential factors in obtaining a good result.

With the limited number of ankle transplants published and the relatively high rate of failure, it is difficult to determine who is the best patient for this technique. Although the preliminary results are promising, with very good results and more than half of the patients achieving pain relief in several published series, controlled comparative studies, against both arthrodesis and ankle arthroplasties and with longer follow-up periods, are needed to confirm better cartilage survival and the validity of this technique.

Level of evidence

Level of evidence II.

Ethical responsibilities

Protection of people and animals. The authors state that no experiments have been carried out on humans or animals.

Confidentiality of the data. The authors state that this article contains no patient data.

Right to privacy and informed consent. The authors state that this article contains no patient data.

Conflict of interests

The authors have no conflict of interests to declare.

Acknowledgements

We would like to express our special thanks to Professor S. Giannini, Rizzoli Orthopaedic Institute, Bologna University, Italy.

References

- Hubbard TJ, Hicks-Little C, Cordova M. Mechanical and sensorimotor implications with ankle osteoarthritis. *Arch Phys Med Rehabil.* 2009;90:1136–41.
- Jeng CL. The current status of fresh osteochondral allograft transplantation for ankle arthritis. *Semin Arthro.* 2010; 21:253–8.
- Coester LM, Saltzman CL, Leupold J, Pontarelli W. Long-term results following ankle arthrodesis for post-traumatic arthritis. *J Bone Joint Surg Am.* 2001;83-A:219–28.
- Thomas R, Daniels TR, Parker K. Gait analysis and functional outcomes following ankle arthrodesis for isolated ankle arthritis. *J Bone Joint Surg Am.* 2006;88:526–35.
- Sheridan BD, Robinson DE, Hubble MJ, Winson IG. Ankle arthrodesis and its relationship to ipsilateral arthritis of the hind- and mid-foot. *J Bone Joint Surg Br.* 2006;88: 206–7.
- Anderson T, Montgomery F, Carlsson A. Uncemented STAR total ankle prostheses. Three to eight-year follow-up of fifty-one consecutive ankles. *J Bone Joint Surg Am.* 2003;85-A: 1321–9.
- Knecht SI, Estin M, Callaghan JJ, Zimmerman MB, Alliman KJ, Alvine FG, et al. The agility total ankle arthroplasty. Seven to sixteen-year follow-up. *J Bone Joint Surg Am.* 2004;86-A:1161–71.
- Görtz S, Bugbee WD. Fresh osteochondral allograft resurfacing of the ankle. *Oper Tech Orthop.* 2006;16:244–9.
- Giannini S, Buda R, Vannini F, Bevoni R, Grogolo B. Total joint reconstruction of the arthritic ankle joint using bipolar shell allograft. *Osteoarthritis Cartilage.* 2007;15:B34.
- McGovern BM, Pritzker KP, Shasha N, Price J, Gross AE. Long-term chondrocyte viability in a fresh osteochondral allograft. *J Knee Surg.* 2002;15:97–100.
- Oakeshott RD, Farine I, Pritzker KP, Langer F, Gross AE. A clinical and histologic analysis of failed fresh osteochondral allografts. *Clin Orthop Relat Res.* 1998:283–94.
- Allen RT, Robertson CM, Pennock AT, Bugbee WD, Harwood FL, Wong VW, et al. Analysis of stored osteochondral allografts at the time of surgical implantation. *Am J Sports Med.* 2005;33:1479–84.
- Williams RJ, Dreese JC, Chen CT. Chondrocyte survival and material properties of hypothermically stored cartilage: an evaluation of tissue used for osteochondral allograft transplantation. *Am J Sports Med.* 2004;32:132–9.
- Gross AE, Aubin P, Cheah HK, Davis AM, Ghazavi MT. A fresh osteochondral allograft alternative. *J Arthroplasty.* 2002;17 Suppl 1:50–3.
- Convery FR, Akeson WH, Amiel D, Meyers MH, Monosov A. Long-term survival of chondrocytes in an osteochondral articular cartilage allograft. A case report. *J Bone Joint Surg Am.* 1996;78:1082–8.
- Czitrom AA, Keating S, Gross AE. The viability of articular cartilage in fresh osteochondral allografts after clinical transplantation. *J Bone Joint Surg Am.* 1990;72:574–81.
- Langer F, Gross AE. Immunogenicity of allograft articular cartilage. *J Bone Joint Surg Am.* 1974;56:297–304.
- Giannini S, Buda R, Grogolo B, Bevoni R, Di Caprio F, Ruffilli A, et al. Bipolar fresh osteochondral allograft of the ankle. *Foot Ankle Int.* 2010;31:38–46.

19. Giannini S, Buda R, Faldini C, Vannini F, Romagnoli M, Grandi G, et al. The treatment of severe posttraumatic arthritis of the ankle joint. *J Bone Joint Surg Am.* 2007;89A Suppl 3:15–28.
20. Kim CW, Jamali A, Tontz WJr, Convery FR, Brage ME, Bugbee W. Treatment of post-traumatic ankle arthrosis with bipolar tibiotalar osteochondral shell allografts. *Foot Ankle Int.* 2002;23:1091–102.
21. Meehan R, McFarlin S, Bugbee W, Brage M. Fresh ankle osteochondral allograft transplantation for tibiotalar joint arthritis. *Foot Ankle Int.* 2005;26:793–802.
22. Jeng CL, Kadakia A, White KL, Myerson M. Fresh osteochondral total ankle allograft transplantation for the treatment of ankle arthritis. *Foot Ankle Int.* 2008;29:554–60.