



## ORIGINAL ARTICLE

# Evaluation of intraoperative anterior cruciate ligament laxity using a navigation system in the anatomical single bundle reconstruction<sup>☆</sup>

R. García-Bógalo\*, R. Larraínzar-Garijo, A.D. Murillo-Vizuete, J. Montoya-Adárraga, O. Marín-Peña, M. Pérez-España Muniesa, L. Horna-Castañeira

Servicio de Cirugía Ortopédica y Traumatología, Hospital Universitario Infanta Leonor, Madrid, Spain

Received 18 September 2011; accepted 21 December 2011

### KEYWORDS

Anterior cruciate ligament reconstruction (ACL); Anteromedial portal technique; Navigation; Computer assisted

### Abstract

**Purpose:** The anatomical anterior cruciate ligament (ACL) reconstruction attempts to, by reproducing the natural orientation of its fibres, achieve a better rotational stability of the knee. The aim of this paper is to quantify the anteroposterior and rotational laxity of the knee before and after an anatomic ligamentoplasty using the Orthopilot® navigation system as a supporting tool.

**Material and method:** We describe the distinctive steps of Orthopilot® navigation as well as conducting a retrospective cross-sectional study on a cohort of 20 patients operated in our hospital for chronic primary ACL rupture from January 2010 to May 2011. The precise location of the tunnels was defined with the help of the navigator and the intra-articular landmarks and stability tests were performed in both the sagittal and axial planes.

**Results:** In our technique for anatomical ACL reconstruction placed the tibial tunnel at a mean distance of  $16.8 \pm 4.92$  mm from the posterior cruciate ligament in a position that represented  $44.1 \pm 4.35\%$  of the total width of the tibial plateau. The average distance from the centre of the femoral tunnel to the posterior cortex of the lateral condyle was  $7.89 \pm 2.78$  mm. Intraoperatively and before ACL reconstruction, the mean ( $\pm$ SD) anteroposterior movement, internal rotation and external rotation of the tibia at 30° position were 15.5 mm ( $\pm 5.11$ ), 19° ( $\pm 3.62$ ) and 19.65° ( $\pm 3.26$ ), respectively. After reconstruction these values decreased to 5.6 mm ( $\pm 1.72^\circ$ ), 12.17° ( $\pm 3.76$ ) and 16.9° ( $\pm 4.42$ ), respectively.

**Conclusions:** The use of navigation systems supporting the surgery allows the systematic positioning of bone tunnels and standardises the procedures for the desired reconstruction. ACL reconstruction using the technique described, improves the anteroposterior and rotational stability compared to preoperative status, to a stability state that could be considered physiological according to current scientific knowledge.

© 2011 SECOT. Published by Elsevier España, S.L. All rights reserved.

<sup>☆</sup> Please cite this article as: García-Bógalo R, et al. Evaluación mediante navegación intraoperatoria de la laxitud del ligamento cruzado anterior en su reconstrucción anatómica monofascicular. Rev Esp Cir Ortop Traumatol. 2012; 56:267–73.

\* Corresponding author.

E-mail address: [rgbogalo@hotmail.com](mailto:rgbogalo@hotmail.com) (R. García-Bógalo).

**PALABRAS CLAVE**

Reconstrucción del ligamento cruzado anterior (LCA);  
Técnica portal anteromedial;  
Navegación;  
Cirugía asistida por ordenador

## Evaluación mediante navegación intraoperatoria de la laxitud del ligamento cruzado anterior en su reconstrucción anatómica monofascicular

**Resumen**

**Objetivo:** La técnica de reconstrucción anatómica del ligamento cruzado anterior (LCA) persigue, reproduciendo la orientación nativa de sus fibras, alcanzar una mejor estabilidad rotacional en la rodilla. El objetivo principal del presente trabajo es la evaluación cuantitativa intraoperatoria, mediante el uso del sistema de navegación de Orthopilot®, de la laxitud anteroposterior y rotacional de la rodilla antes y después de una ligamentoplastia anatómica.

**Material y método:** Descripción de la técnica de navegación y estudio transversal sobre una cohorte de 20 pacientes intervenidos en nuestro centro por rotura primaria crónica del LCA desde enero de 2010 hasta mayo de 2011. Con la ayuda del navegador se definió la posición exacta de los túneles en base a referencias anatómicas intraarticulares y se realizaron pruebas de estabilidad, tanto en el plano sagital como en el axial.

**Resultados:** Nuestra técnica de reconstrucción anatómica del LCA situó el túnel tibial a una distancia media de  $16,8 \pm 4,92$  mm del ligamento cruzado posterior y a un  $44,1\% \pm 4,35\%$  de la anchura total del platillo tibial. La distancia media del centro del túnel femoral a la cortical posterior del cóndilo lateral fue de  $7,89 \pm 2,78$  mm. Intraoperatoriamente y antes de la reconstrucción, los valores medios ( $\pm$ DE) de traslación anteroposterior, rotación interna y rotación externa de la tibia a  $30^\circ$  fueron de  $15,5$  mm ( $\pm 5,11$ );  $19^\circ$  ( $\pm 3,62$ ) y  $19,65^\circ$  ( $\pm 3,26$ ) respectivamente. Tras la reconstrucción dichos valores disminuyeron a  $5,6$  mm ( $\pm 1,72$ );  $12,17^\circ$  ( $\pm 3,76$ ) y  $16,9^\circ$  ( $\pm 4,42$ ).

**Conclusiones:** El empleo de sistemas de navegación como apoyo al cirujano permite sistematizar la posición de los túneles óseos y estandarizar el procedimiento en relación a la reconstrucción deseada. La reconstrucción del LCA según la técnica descrita, mejora la estabilidad anteroposterior y rotacional monoplanar respecto al estado preoperatorio pudiendo restablecer los valores de laxitud a los considerados como fisiológicos acorde al conocimiento científico actual.

© 2011 SECOT. Publicado por Elsevier España, S.L. Todos los derechos reservados.

**Introduction**

Computer-assisted surgery was first used in the reconstruction of the anterior cruciate ligament (ACL) in the year 1990.<sup>1</sup> Since then, different navigation software has been developed in an attempt to make ACL surgery more reproducible and quantifiable. While early navigators focused on locating and making bony tunnels,<sup>2-4</sup> current software includes tools capable of measuring the stability of the knee in different planes, before and after ligament reconstruction, behaving as highly reliable intraoperative arthrometers.<sup>5,6</sup>

Recent biomechanical studies have indicated that reconstruction of a single bundle (or fascicle) and anatomical tunnels restore knee stability to levels similar to those of double bundle reconstruction.<sup>7</sup>

The aim of this work was to quantify anteroposterior and rotational stability pre- and postreconstruction using a monofascicular anatomical reconstruction technique, with the help of a navigator. A second aim was to describe the exact position of the tibial and femoral tunnels according to data collected by the navigator. The study hypothesis was to assume that the help of the navigator would improve the final intraoperative stability of the intervened knees.

**Material and method****Clinical series**

This was a cross-sectional study on a cohort of 20 patients undergoing primary reconstruction of the anterior cruciate ligament between January 2010 and May 2011. All patients were diagnosed with chronic tears and the following inclusion criteria were established: patients with closed physis and no more than 50 years old, primary ligamentoplasties, use of any type of graft and use of navigator during surgery. The exclusion criterion established was the presence of associated lesions diagnosed by MRI or exploratory arthroscopy prior to reconstruction.

The series consisted of 15 males and 5 females with a mean age of  $33.5 \pm 9.03$  years. The mean period elapsed between injury and surgery was  $185 \pm 34.35$  days.

The operations were performed by the same surgeon in all cases. The predominant type of graft was the quadruple semitendinous plasty/gracilis muscle, which was used in 13 cases (males and females >35 years who did not practice pivoting sports), the bone-tendon-bone technique was employed in 4 males who were usual soccer players and allografts were used in 3 cases (2 males and 1 female >40

years), with the personal choice of each patient being the sole selection criterion.

Femoral tunnels were performed in all cases through the standard medial portal or an accessory medial portal, and fixation techniques used were the Retrobutton® system (Arthrex, Naples, Florida, USA) as cortical fixation in the fibula and PLLA Bio-interference Screws® (Arthrex, Naples, Florida, USA) in the tibia. We used screws which were 1 mm larger than the diameter of the tunnel in the case of tendon plasties and of the same diameter in the case of bone–tendon–bone plasties.

For the collection of data, we used the documentation recorded by the navigator software during the surgery of each patient. We studied the position of the tunnels in relation to intraarticular anatomical landmarks and the kinematic data concerning anterior tibial translation, external tibial rotation and internal tibial rotation at 30° flexion. Navigation of the tibial and femoral tunnels was not possible in 2 patients (11 and 13) due to errors in data collection of intraarticular anatomical landmarks. The anatomical position of these tunnels was visually verified based on previously marked bone landmarks. In these 2 patients it was possible to conduct navigator-assisted stability tests (Table 1).

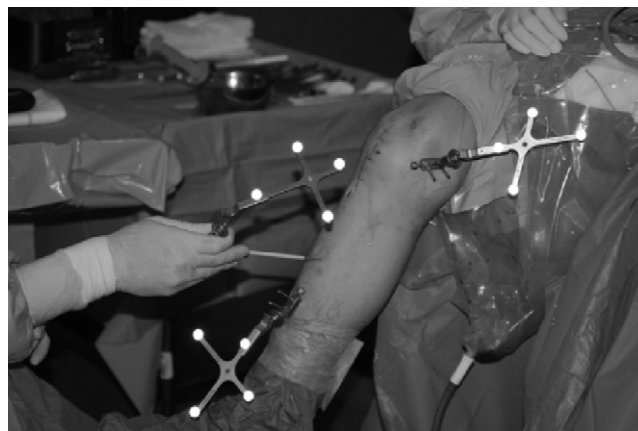
### Navigation technique

The Orthopilot® navigation system (v.2.1, B. Braun-Aesculap, Tuttlingen, Germany) for ACL reconstruction can be used with any type of graft and fixation technique as the software does not require preoperative radiological data input. This is a passive navigation system using infrared sensors and emitters, of which 2 are fixed to the fibula and tibia using Kirschner wires and 1 is used freely in the various hand tools. Navigation in ACL reconstruction consisted of 4 phases:

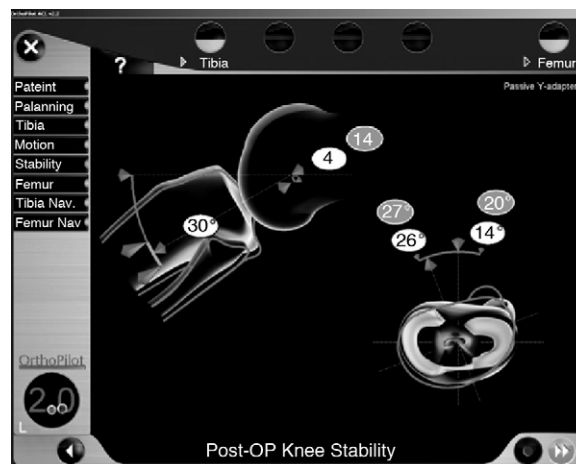
**Marking of extraarticular anatomical landmarks:** the anterior tibial tuberosity, the anterior tibial crest in its middle-distal third and the medial and lateral edges of the tibial plate were located with a straight pointer and its corresponding emitter. Subsequently, a kinematic registry of the knee between 0° and 90° was carried out (Fig. 1).

**Preligamentoplasty stability test:** the anterior and rotational displacements of the tibia at 30° flexion were recorded in the computer under maximum manual force.

**Marking of intraarticular anatomical landmarks and location of tunnels:** the anterior edge of the posterior cruciate ligament, anterior horn of the lateral meniscus, medial tibial spine, anterior edge of the notch, the insertion area of the cruciate in the medial wall of the lateral condyle, the “over the top” position at 12 O’clock on the posterior edge of the notch (time reference provided by the software taking into account the position of the knee at 90° flexion and a frontal plane cutting transversally across the distal fibula) and the posterior cortex in the time zone selected for the femoral tunnel were palpated with different types of pointers and visualised through the arthroscope. Once the intraarticular references had been marked, the tibial tunnel was made with a special guide on which the mobile emitter was placed. The exit point of the guide wire from the tibial tunnel was located according to the data provided previously. Similarly,



**Figure 1** Femoral and tibial emitters anchored with 2 Kirschner wires. Straight pointer with a mobile emitter identifying extraarticular anatomical landmarks.



**Figure 2** Examination of the stability at 30° knee flexion. Pre-operative values are shown in grey and postoperative values are shown in white.

with the aid of the pointer, we located the centre of the femoral tunnel in the wall of the condyle.

**Postligamentoplasty stability test:** after the plasty was introduced and fixed we assessed the quality of reconstruction by quantifying anteroposterior and rotational stability of the tibia at 30° knee flexion once again (Fig. 2).

### Statistical study

Data regarding the position of the tunnels, as well as the results of stability tests before and after reconstruction were collected using a database created for this purpose. All results are shown as mean ± standard deviation. This documentation was processed by the Department of Clinical Research at our centre, using the nonparametric Wilcoxon test for the comparison of pre–post values in the different stability tests. Statistical significance was considered at  $P < .05$ .

**Table 1** Type of plasty and location of tunnels.

Patient	Plasty-diameter (mm)	Distance PCL-TT <sup>a</sup> (mm)	Plate width TT <sup>b</sup> (%)	Cortical distance post-FT <sup>c</sup> (mm)	Hour area in 90° flexion <sup>d</sup>
1	ST/GM 8	8	51	3	L 14:30
2	ST/GM 8	22	49	8	R 11:00
3	ST/GM 9	12	43	10	L 13:30
4	ST/GM 9	22	40	3	R 10:00
5	ST/GM 10	21	46	8	R 10:00
6	ST/GM 9	20	39	3	L 13:30
7	ALO 8	14	34	8	L 14:00
8	BTB 9	26	44	9	R 9:30
9	BTB 9	24	43	9	R 10:3
10	ST/GM 9	19	39	7	R 10:30
11	ST/GM 8				R
12	ST/GM 8	13	47	9	L 13:00
13	ST/GM 9				R
14	ST/GM 8	19	48	9	R 10:30
15	ST/GM 8	12	51	13	R 10:00
16	BTB 9	15	44	12	L 14:00
17	BTB 9	14	47	10	R 13:30
18	ALO 9	20	45	6	R 10:30
19	ALO 8	11	53	8	L 14:00
20	ST/GM 9	12	44	8	R 10:30

ALO: allograft; BTB: bone-tendon-bone; FT: femoral tunnel; L: left; PCL: posterior cruciate ligament; R: right; ST/GM: semitendinous/gracilis muscle; TT: tibial tunnel.

<sup>a</sup> Distance in mm from the anterior edge of the posterior cruciate ligament-centre of tibial tunnel.

<sup>b</sup> Centre location of tibial tunnel in relation to width of proximal tibia.

<sup>c</sup> Distance in mm of point referenced by navigator in the posterior cortical of the lateral condyle-centre of femoral tunnel.

<sup>d</sup> Knee at 90° flexion, frontal hour view in coronal plane.

## Results

The results are shown in Table 2. The mean value of anteroposterior displacement of the tibia at 30° before reconstruction was  $15.5 \pm 5.11$  mm. After fixation of the plasty, this value was reduced to  $5.6 \pm 1.72$  mm ( $P < .001$ ). Starting from a neutral rotation to 30° flexion, the maximum displacement in internal rotation preligamentoplasty was  $19 \pm 3.62^\circ$  and in external rotation it was  $19.65 \pm 3.26^\circ$ . After anatomical reconstruction, rotational laxity was fundamentally reduced at the expense of internal rotation with values of  $12.17 \pm 3.76^\circ$  versus  $16.9 \pm 4.42^\circ$  external rotation ( $P < .001$  for both values).

Regarding the position of the tunnels, the tibial tunnel was located at a mean distance of  $16.8 \pm 4.92$  mm from the posterior cruciate ligament and  $44.1 \pm 4.35\%$  (medial) of the total width of the plate. The femoral tunnel was located at a mean distance of  $7.89 \pm 2.78$  mm from the posterior femoral cortex of the lateral condyle. Considering the time

reference of the software with the knee at 90° flexion, the femoral tunnels in right knees were placed at 09:30 and in left knees at 14:30.

There were 2 complications related to the navigation technique described: 1 first-degree burn in the middle third of the anterior tibial region due to the heat produced by the Kirschner wire of the emitter and 1 breakage of the threaded needle tip during extraction, which became included within the tibia.

## Discussion

In the present study we noted mean values of anterior translation, internal rotation and external rotation at 30° flexion after reconstruction of 5.6 mm, 12.2 and 16.9°, respectively, compared to 15.5 mm, 19 and 19.6°, as mean preoperative values in knees without ACL. Quantification of the final stability of the knee after ligamentoplasty enables us to compare these values with those previously reported in

**Table 2** Pre- and postreconstruction laxity of the anterior cruciate ligament.

Test	Preoperative	Postoperative	Percentage of reduction	P value
Anteroposterior displacement 30° (mm)	$15.5^\circ (\pm 5.11)$	$5.6^\circ (\pm 1.72)$	63.87	<.001
External rotation 30°	$19.6^\circ (\pm 3.26)$	$16.9^\circ (\pm 4.42)$	13.77	<.001
Internal rotation 30°	$19^\circ (\pm 3.62)$	$12.2^\circ (\pm 3.76)$	35.78	<.001

healthy and stable knees. Using the Orthopilot® navigator and the same software version, Song et al. performed stability tests in knees with ACL injury before and after reconstruction and compared them with the same test performed in healthy contralateral knees. Regarding anterior tibial translation at 30° in healthy knees, they obtained values of 6.7 mm vs 14.7 mm in injured knees.<sup>8</sup> These findings were similar to those observed by Daniel MD et al. in 1985 using different measuring instruments, but obtaining anterior displacements at 30° of 7.5 mm in healthy knees compared to 13 mm in ACL deficient knees under loads of 89 newtons.<sup>9</sup> In our work, we obtained a reduction of internal rotation of 36% versus 14% external rotation compared to preoperative values. The correction of rotational instability (kinematic function of ACL, along with AP translational control) observed was in accordance with the current work of Miura et al. and Song et al.<sup>8,10</sup> Both studies compared stability test results with the healthy contralateral knee. The overall rotation (internal rotation + external rotation) in healthy knees in both studies was  $36.4 \pm 2.7^\circ$  and  $31.4 \pm 4.2^\circ$ , respectively. In our study, the mean overall rotational stability after reconstruction was  $29.1 \pm 2.6^\circ$ , a value similar to those observed earlier in healthy knees.

The anatomical monofascicular technique achieves a more horizontal, superficial and lower placement of the plasty than that obtained with conventional techniques, in which the femoral tunnel is created through the tibial tunnel, thus obtaining central and more vertical plasties. Recent biomechanical studies have shown that the monofascicular anatomical reconstruction technique restores anteroposterior and rotational stability to the same levels as the bifascicular technique.<sup>7,11,12</sup> The residual rotational instability after ACL reconstructive surgery is a subject of debate. Several authors have shown how single bundle reconstructions with kinematically lower femoral insertions perform better than traditional plasties placed in a higher position in the intercondyle. Loh et al. compared various plasty sites with femoral tunnels at 11 h versus tunnels at 10 h. The latter resisted anterior translation better in response to rotatory loads.<sup>13</sup> Similarly, Scopop et al. compared kinematic measurements in bone-tendon-bone (BTB) reconstructions and traditional femoral tunnels (high) versus lower tunnels and found that, at 30° flexion, knees with lower femoral tunnels presented a correction of tibial internal rotation to near normal values, compared with the traditional technique.<sup>14</sup>

New software from different manufacturers allows us to perform stability tests including translational and rotational measurements, thus enabling us to assess the effect of different surgical procedures on knee stability and better describe specific laxity in each patient. There have been comparative studies with other kinematic measurement systems, such as the KT-1000 (MEDmetric Corp, San Diego, California), Rolimetro (Aircast Europe, Neubeuern, Germany), etc., which have demonstrated the reliability, accuracy and inter- and intraobserver reproducibility of measurements obtained with the different navigators.<sup>15,16</sup> In a series of 79 patients, Martelli et al. have shown an intra-surgeon variability of kinematic measurements navigated in knees before and after ACL reconstruction below 1 mm for

anteroposterior translations and below 1.6° for external and internal rotations.<sup>17</sup>

In our study we used a vaporiser to mark the area of insertion for the creation of tunnels. However, in the medial wall of the femoral condyle and after cleaning the ligament remains from the anatomical insertion, we often navigated based on the bone ridges described in the work of Fu et al.<sup>18,19</sup> The navigator only recorded the position of the centre of these tunnels (guide needles) in relation to intraarticular anatomical landmarks marked previously with the pointer. That is, in our work we did not use navigation as an aid in the location of the tibial and femoral tunnels, but only as a way to record them. However, the navigator quantified the exact distance from the centre of the femoral tunnel to the posterior cortex with more precision, thus offering greater safety for the drilling of tunnels. As an interesting fact, the tibial tunnel was located about 16 mm from the edge of the posterior cruciate ligament (PCL), a more anterior point than that obtained with most of the guides that rely on this ligament. The femoral tunnel always respected 3–4 mm of the posterior cortex, with a tendency to get closer to the condylar insertion of the anteromedial bundle. In agreement with current works, we believe that in experienced hands navigation does not provide benefits for the performance of the tibial tunnel,<sup>20,21</sup> but its use may represent an effective support tool for surgeons lacking sufficient experience. Most articles report a better positioning of the femoral tunnel in reconstructions assisted by navigation compared to standard ones.<sup>22,23</sup> Navigation of the tunnels in our study was only a secondary objective, aimed at quantifying their position with the future objective of systematising our surgical technique.

It must be noted that navigators require an invasive technique with fixation of the emitters to the bone through the use of Kirschner wires, thus involving potential complications. In our series, we only noted 2 complications: 1 first-degree burn in the tibial region caused by the heat transmitted by the Kirschner needle upon entry (this was easily resolved with local cures in consultation) and 1 patient in whom the threaded tip of the needle broke during its removal, becoming included within the tibia, and without complications during the postoperative or follow-up periods. In the future, the development of less invasive techniques will enable intraoperative kinematic comparison with the healthy knee and even the possibility of using navigators in consultation for follow-up.

Our work presents 2 types of constraints: some linked to the navigation tool itself and others related to the study design. The Orthopilot® navigator uses software which allows us to perform uniplanar stability tests: either anterior translation of the tibia in the sagittal plane or rotational manoeuvres in an axial plane. Recently, Bull et al.<sup>24</sup> published how these clinical tests assess 2 types of joint instability: static and dynamic. Static measurements are generally associated with uniplanar laxity tests, whereas patients with symptoms refer dynamic knee instability. We attempted to reproduce the latter through multiplanar exploratory tests with pivot shift. At present, various navigation software for ACL surgery are working on quantifying the pivot shift manoeuvre intraoperatively, with promising results and potential future application in knee surgery.<sup>25–27</sup>

Another limitation of the navigator is the use of manual forces to carry out stability tests, decreasing the reproducibility of such measurements and generating a source of bias. In our study, examinations were performed by the same surgeon in all cases, attempting to simulate the manoeuvres performed in consultation. Future studies should use quantitative systems to ensure a constant external force, in order to improve the reproducibility of laxity measurements. As for the limitations of study design, these include its descriptive character, the small sample size, the use of different types of plasties and the absence of comparisons with the healthy contralateral knee. Future prospective and comparative studies may demonstrate how navigation could make anterior cruciate ligament surgery a more reproducible and individualised technique, tailored to the anatomical and kinematic characteristics of each patient. Similarly, future comparative studies will be needed to demonstrate, firstly, the better kinematic control of plasties placed with computer-assisted surgery and, secondly, its clinical usefulness, obtaining better functional results in the medium and long term.

## Conclusions

ACL reconstruction using the technique described improves monoplane anteroposterior and rotational stability with respect to the preoperative condition and may restore these values to those observed in healthy knees.

## Level of evidence

Level of evidence IV.

## Ethical disclosures

**Protection of human and animal subjects.** The authors declare that no experiments were performed on humans or animals for this investigation.

**Confidentiality of Data.** The authors declare that no patient data appears in this article.

**Right to privacy and informed consent.** The authors declare that no patient data appears in this article.

## Conflict of interests

The authors have no conflicts of interest to declare.

## References

- Dessenne V, Lavallée S, Julliard R, Orti R, Martelli S, Cinquin P. Computer-assisted knee anterior cruciate ligament reconstruction: first clinical tests. *J Image Guid Surg.* 1995;1:59–64.
- Plaweski S, Cazal J, Rosell P, Merloz P. Anterior cruciate ligament reconstruction using navigation: a comparative study on 60 patients. *Am J Sports Med.* 2006;34:542–52.
- Picard F, DiGioglia AM, Moody J, Martinek V, Fu FH, Rytel M, et al. Accuracy in tunnel replacement for ACL reconstruction. Comparison of traditional arthroscopic and computer-assisted navigation techniques. *Comput Aided Surg.* 2001;6: 279–89.
- Klos T, Habets R, Banks A, Banks SA, Devillees RJ, Cook FF. Computer assistance in arthroscopic anterior cruciate ligament reconstruction. *Clin Orthop Relat Res.* 1998;354: 65–9.
- Pearle AD, Kendoff D, Musahl V, Warren RF. The pivot-shift phenomenon during computer-assisted anterior cruciate ligament reconstruction. *J Bone Joint Surg Am.* 2009;91 Suppl 1:S115–8.
- Ishibashi Y, Tsuda E, Tazawa K, Sato H, Toh S. Intraoperative evaluation of the anatomical double-bundle anterior cruciate ligament reconstruction with the OrthoPilot® navigation system. *Orthopedics.* 2005;28 Suppl:S1277–82.
- Meredick RB, Vance KJ, Appleby D, Lubowitz JH. Outcome of single-bundle versus double-bundle reconstruction of the anterior cruciate ligament: a meta-analysis. *Am J Sports Med.* 2008;36:1414–21.
- Song EK, Seon JK, Park SJ, Hur CL, Lee DS. In vivo laxity of stable versus anterior cruciate ligament-injured knees using a navigation system: a comparative study. *Knee Surg Sports Traumatol Arthrosc.* 2009;17:941–5.
- Daniel DM, Malcom LL, Losse G, Stone ML, Sachs R, Burks R. Instrumented measurement of anterior laxity of the knee. *J Bone Joint Surg Am.* 1985;67:720–6.
- Miura K, Ishibashi Y, Tsuda E, Fukuda A, Tsukada H, Toh S. Intraoperative comparison of knee laxity between anterior cruciate ligament-reconstructed knee and contralateral stable knee using navigation system. *Arthroscopy.* 2010;26: 1203–11.
- Ferreti A, Monaco E, Labianca L, De Carli A, Maestri B, Conteduca F. Double-bundle anterior cruciate ligament reconstruction: a computer-assisted orthopaedic surgery study. *Am J Sports Med.* 2008;36:760–6.
- Albuquerque RF, Ssaki SU, Amatuzzi MM, Angelini FJ. Anterior cruciate ligament reconstruction with double bundle versus single bundle: experimental study. *Clinics.* 2007;62: 335–44.
- Loh JC, Fukua Y, Tsuda E, Steadman RJ, Fu FH, Woo SLY. Knee stability and graft function following anterior cruciate ligament reconstruction: comparison between 11 O'clock and 10 O'clock femoral tunnel placement. *Arthroscopy.* 2003;19:297–304.
- Scopop JM, Jasper LE, Belkoff SM, Moorman CT. The effect of oblique femoral tunnel placement on rotational constraint of the knee reconstructed using patellar tendon autografts. *Arthroscopy.* 2004;20:294–9.
- Kendoff D, Meler R, Citak M, Pearle A, Marquardt S, Krettek C, et al. Navigation in ACL reconstruction – comparison with conventional measurement tools. *Technol Health Care.* 2007;15:221–30.
- Pearle AD, Shannon FJ, Granchi C, Wizkiewicz TL, Warren RF. Comparison of 3-dimensional obliquity and isometric characteristics of anterior cruciate ligament graft positions using surgical navigation. *Am J Sports Med.* 2008;36:1534–41.
- Martelli S, Zaffagnini S, Bignozzi S, Lopomo N, Marcacci M. Description and validation of a navigation system for intraoperative evaluation of knee laxity. *Comput Aided Surg.* 2007;12:181–8.
- Martins CA, Kropf EF, Wei Shen Fu FH. The concept of anatomic anterior cruciate ligament reconstruction. *Oper Tech Sports Med.* 2008;16:104–15.
- Ferreti M, Ekdhal M, Shen W, Fu FH. Osseous landmarks of the femoral attachment of the anterior cruciate ligament: an anatomic study. *Arthroscopy.* 2007;23:1218–25.
- Mauch F, Apic G, Becker U, Bauer G. Differences in the placement of the tibial tunnel during reconstruction of the anterior cruciate ligament with and without computer-assisted navigation. *Am J Sports Med.* 2007;35:1824–32.
- Valentin P, Hofbauer M, Aldrian S. Clinical results of computer-navigated anterior cruciate ligament reconstruction. *Orthopedics.* 2005;28 Suppl:S1289–91.

22. Sati M, Stäubli H, Bourquin Y, Kunz M, Nolte LP. Real-time computerized in situ guidance system for ACL graft placement. *Comput Aided Surg.* 2002;7:25–40.
23. Picard F, DiGioia AM, Moody J, Martinek V, Fu FH, Rytel M, et al. Accuracy in tunnel placement for ACL reconstruction. Comparison of traditional arthroscopic and computer-assisted navigation techniques. *Comput Aided Surg.* 2001;6: 279–89.
24. Bull AN, Andersen HN, Baso O, Targett J, Amis AA. Incidence and mechanism of the pivot shift. An in vitro study. *Clin Orthop Relat Res.* 1999;21:9–23.
25. Lopomo N, Zaffagnini S, Bignozzi S, Visani A, Marcacci M. Pivot-Shift Test: analysis and quantification of knee laxity parameters using a navigation system. *J Orthop Res.* 2009;28:164–9.
26. Citak M, Suero EM, Pearle AD, Rozell JC, Bosscher MR, Kuestermeyer J. A mechanized and standardized pivot shifter: technical description and first evaluation. *Knee Surg Sports Traumatol Arthrosc.* 2010;19:707–11.
27. Ishibashi Y, Tsuda E, Yamamoto Y, Tsukuada H, Toh S. Navigation evaluation of the pivot-shift phenomenon during double-bundle anterior cruciate ligament reconstruction: is the posterolateral bundle more important. *Arthroscopy.* 2009;25:488–95.