



ORIGINAL ARTICLE

Results of polyurethane implant for persistent knee pain after partial meniscectomy with a minimum of two years follow-up[☆]



C. Martín-Hernández*, M. Ranera-García, J.V. Díaz-Martínez, M.P. Muniesa-Herrero, L.J. Floría-Arnal, M. Osca-Guadalajara, D. García-Aguilera

Servicio de Cirugía Ortopédica y Traumatología, Hospital Obispo Polanco, Teruel, Spain

Received 12 May 2014; accepted 7 July 2014

KEYWORDS

Meniscus scaffold;
Polyurethane;
Post-meniscectomy
pain

Abstract

Purpose: To present the results of a polyurethane meniscal scaffold implant in 10 patients with persistent pain after meniscectomy.

Methods: Prospective, descriptive study of ten patients who underwent arthroscopic implantation of a polyurethane meniscal scaffold. Functional, MRI, and radiography assessments were performed pre-operatively and at 6 months, 1 year, and a final follow-up at a minimum of two years. Clinical evaluation included Lysholm score, KOOS and VAS. The MRI morphology and signal intensity of the implant were evaluated according to the criteria of Genovese et al.

Results: Statistically significant differences were found between the mean Lysholm score before surgery (63.5 points) and that at 6 months (76.8 points) ($p = .001$), one year (83.3 points) ($p < .001$) and final follow-up (84.4 points) ($p < .001$).

KOOS showed significant differences before surgery (64.23 points), 6 months (73.66 points) ($p = .001$), one year (81.39 points) ($p < .001$) and final follow-up (83.34 points) ($p < .001$).

The mean values for VAS were 5.7 points in the pre-operative evaluation, 3.6 points at 6 months follow-up ($p < .001$), 1.9 points at one year ($p < .001$), and 1.9 points at final follow-up ($p < .001$).

Radiology showed degenerative changes in one case.

In MRI, the size of the implant and the intensity of the MRI signal gradually decreased, but it never changed to that of a normal meniscus.

Conclusion: A significant improvement was found in all the clinical parameters 24 months after the surgery, except in one patient who underwent further surgery. The scaffold reduced its size and but never achieved an MRI image similar to that of a normal meniscus.

[☆] Please cite this article as: Martín-Hernández C, Ranera-García M, Díaz-Martínez JV, Muniesa-Herrero MP, Floría-Arnal LJ, Osca-Guadalajara M, et al. Resultados de un implante de poliuretano para el tratamiento del dolor persistente de rodilla tras meniscectomía parcial con un mínimo de dos años de seguimiento. Rev Esp Cir Ortop Traumatol. 2015;59:44–51.

* Corresponding author.

E-mail address: cmartinh@me.com (C. Martín-Hernández).

The procedure proved to be safe and useful for the treatment of persistent pain after meniscectomy.

© 2014 SECOT. Published by Elsevier España, S.L.U. All rights reserved.

PALABRAS CLAVE

Implante meniscal;
Poliuretano;
Síndrome
postmeniscectomía

Resultados de un implante de poliuretano para el tratamiento del dolor persistente de rodilla tras meniscectomía parcial con un mínimo de dos años de seguimiento

Resumen

Objetivo: Evaluar los resultados de un implante de poliuretano en 10 pacientes con dolor persistente tras meniscectomía parcial.

Material y métodos: Estudio prospectivo descriptivo de 10 pacientes que fueron intervenidos para colocación artroscópica de un implante meniscal de poliuretano.

Se realizó evaluación funcional, de resonancia magnética y radiología simple antes de la intervención, a los 6 meses, un año, y en el seguimiento final con un mínimo de dos años. La evaluación clínica incluyó las escalas de Lysholm, KOOS y EVA. En resonancia magnética (RM) se evaluó la morfología y la intensidad de la señal del implante según los criterios de Genovese et al.

Resultados: Se encontraron diferencias significativas entre la media de puntuación de Lysholm antes de la cirugía (63,5 puntos), a los 6 meses (76,8 puntos) ($p=0,001$), al año (83,3 puntos) ($p<0,001$) y al final del seguimiento (84,4 puntos) ($p<0,001$).

En la puntuación del KOOS se hallaron diferencias significativas entre las medias en el preoperatorio (64,23 puntos) y 6 meses (73,66 puntos) ($p=0,001$), un año (81,39 puntos) ($p<0,001$) y el seguimiento final (83,34 puntos) ($p<0,001$).

Los valores promedio de la EVA fueron de 5,7 puntos en el preoperatorio, 3,6 puntos a los 6 meses ($p<0,001$), 1,9 puntos al año ($p<0,001$) y 1,9 puntos al final del seguimiento ($p<0,001$).

La radiología mostró cambios degenerativos en un caso.

En la RM, el tamaño del implante y la intensidad de la señal de RM disminuyeron progresivamente, no llegando a alcanzar nunca los de un menisco normal.

Conclusiones: Veinticuatro meses después de la cirugía se ha encontrado una mejora significativa en todos los parámetros clínicos, salvo en un paciente que precisó reintervención. El tamaño del implante se redujo y en ningún caso se alcanzó una imagen de RM similar a la de un menisco normal.

El procedimiento demostró ser seguro y útil para el tratamiento del dolor persistente tras meniscectomía.

© 2014 SECOT. Publicado por Elsevier España, S.L.U. Todos los derechos reservados.

Introduction

The association between meniscectomy and the onset of arthrosic phenomena in the knee joint cartilage was first described by Fairbanks¹ in 1948. Several meniscal replacement techniques have been developed to prevent these phenomena, among which allografts have been extensively used with promising results.²

In recent years, meniscal implants have been used to prevent degenerative changes in the knee following partial meniscectomy. These implants have been designed as scaffolds to house native cellular proliferation with the aim of regenerating meniscal tissue.³⁻⁵

Meniscal collagen implants (CMI®; Ivy Sports Medicine, Gräfelfing, Germany) have been used in patients with medial and lateral meniscectomy and have shown promising medium-term⁶⁻⁸ and long-term⁹ results.

Actifit® (Orteq Ltd, London, UK) is a synthetic, acellular, biodegradable implant made of aliphatic polyurethane

designed to fill the defect generated by a meniscectomy, as irreparable partial lesions. The objective of treatment with this implant is to provide pain relief and, potentially, restore the functionality of the lost meniscus. This implant offers 80% porosity, is made of a polymer with segments of polycaprolactone and urethane which biodegrades slowly and has shown good results in previous series.^{10,11}

The purpose of this study is to publish the medium-term clinical and radiographic results of the Actifit® meniscal implant in a group of 10 patients with persistent postmeniscectomy pain and a minimum follow-up of 24 months.

The hypothesis of this work is that patients would report improvements in pain and functionality following implantation and that these would persist over time.

Materials and methods

Between January 2009 and November 2010, 10 patients who fulfilled the inclusion criteria underwent arthroscopic

placement of a meniscal Actifit® implant, and were included in the prospective study.

The inclusion criteria were:

1. Persistent knee pain after partial medial or lateral meniscectomy.
2. Loss of over 50% of meniscal tissue.
3. Intact anterior and posterior wall and horns of the meniscus.
4. Age between 16 and 50 years.
5. Stable joint.
6. Classification of the joint cartilage according to the International Cartilage Repair Society (ICRS) ≤ 2 in both the medial and lateral compartments.
7. Normal alignment of the limb (mechanical axis = $0 \pm 3^\circ$).

Criteria 2, 3 and 6 were confirmed in all patients at the time of the arthroscopic meniscectomy and then reassessed after the implantation, using magnetic resonance imaging (MRI).

All patients gave their informed consent prior to the intervention.

Surgical technique

All patients underwent arthroscopy conducted by the same surgeon. After a full diagnostic exploration through standard anteromedial and anterolateral portals, the remaining meniscal tissue was regularized until the healthy tissue was reached. Next, punctures were made from the outside to the inside of the meniscal wall using an 18-caliber needle over and under the meniscus with a motorized drill in order to obtain an adequate blood supply.¹² Next, the defect was measured using the ruler and rigid cannula provided so the implant could be adapted to the size of the meniscal bed, and then it was placed within the joint through the portal of the affected compartment. The corresponding portal was widened using an atraumatic peg to facilitate passage of the implant. The implant was then sutured using Ultra Fast-Fix® (Smith and Nephew Endoscopy, Andover, MA, USA) implants and, when necessary, with outside-inside sutures for the anterior end of the implant (Fig. 1). The sutures were placed in a vertical pattern every 4–5 mm throughout the edge of the meniscus and in a horizontal pattern in the anterior and posterior ends of the implant. The stability of the grafts was tested with a probe hook.

Postoperative rehabilitation

Isometric quadriceps exercises and active mobilization between 0° and 60° using an orthosis were started immediately after the intervention. The range of movement was increased up to 90° after 3 weeks and free movement was allowed after 6 weeks. The orthosis was also removed at this point. Partial load was allowed after 4 weeks, with a gradual increase up to 100% at 9 weeks after implantation. Physical activity without restrictions was allowed after 6 months, but contact sports activities were only allowed after 9 months.

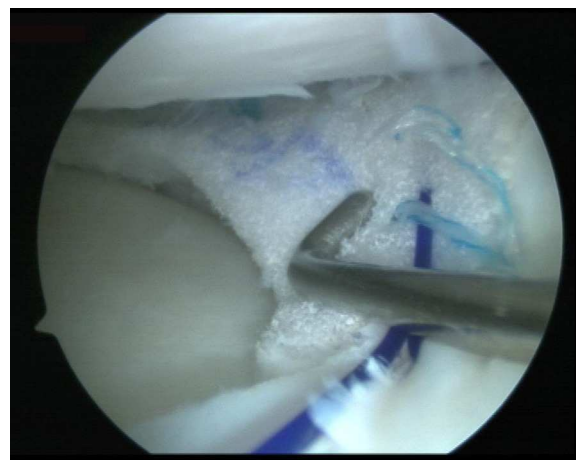


Figure 1 Arthroscopic view from the anterolateral portal of the polyurethane implant sutured to the medial meniscal tissue remaining in the right knee.

Radiographic assessment

All patients underwent functional and radiographic assessment preoperatively and after 6 months, 1 year and at the time of the final control. We obtained a telemetric radiograph of the lower limbs whilst standing and a posteroanterior radiograph with the knees at 45° flexion (Rösenberg radiograph) in order to assess the alignment of the lower limbs, as well as the condition of the joint interline according to the Ahlbäck criteria.¹³

The MRI assessment was conducted with a 1.5T device using axial T2-weighted sequences and spin-echo T1-weighted sequences, and fat suppression and fast spin-echo in the coronal, sagittal and transversal planes to assess the size, morphology and intensity of the signal from the implant following the criteria described by Genovese et al.¹⁴ (Table 1).

Functional assessment

The clinical assessment, conducted in person by an independent evaluator at each point in the follow-up period, included the Lysholm scale with 100 points,¹⁵ the Knee injury and Osteoarthritis Outcome Score (KOOS) and a visual analog scale (VAS) to measure knee pain.

Statistical analysis

Due to the limited sample size, we opted for the use of non-parametric tests to analyze the data obtained. We used the Mann-Whitney statistical test to analyze scales measured with the gender of patients, the Wilcoxon test to analyze the different results of functional scales in the follow-up period, and the Spearman correlation coefficient to detect possible correlations between quantitative variables. In all cases, we considered a level of statistical significance of $P \leq .05$. The data were analyzed using the statistics software package SPSS version 15.0 (SPSS Inc., Chicago, USA).

Table 1 Demographic data and clinical results for each patient.

Patient	Gender	Side	Time until surgery (months)	Age	Weight (kg)	Height (m)	BMI (kg/m ²)	Follow-up (months)	KOOS (preoperative)	KOOS (6 months)
1	M	R	18	32	90	1.81	27.4	46	64.3	74.4
2	M	L	25	50	75	1.72	25.3	42	39.9	54.2
3	F	R	36	16	54	1.61	20.8	40	69.0	75.0
4	M	R	13	41	85	1.76	27.4	37	78.0	82.1
5	F	R	20	23	57	1.60	22.2	24	29.2	41.1
6	F	L	12	28	72	1.75	23.5	34	73.2	91.1
7	M	R	16	31	78	1.68	27.6	32	82.1	87.5
8	M	R	22	25	80	1.73	26.7	29	65.5	72.0
9	F	L	18	27	52	1.58	20.8	27	68.5	69.0
10	M	R	20	33	73	1.75	23.8	36	72.6	89.9
Mean			20	30.6	71.6	1.69	24.5	34.7	64.2	73.6

Patient	KOOS (1 year)	KOOS (final)	Lysholm (pre-operative)	Lysholm (6 months)	Lysholm (1 year)	Lysholm (Final)	VAS (pre-operative)	VAS (6 months)	VAS (1 year)	VAS (Final)
1	78.0	80.4	64	76	80	85	5	3	1	1
2	54.8	55.4	39	60	60	60	8	5	5	5
3	89.9	94.0	67	76	91	95	5	3	1	0
4	88.1	91.1	77	82	91	91	6	3	0	1
5	48.2	49.4	36	52	56	56	9	7	4	4
6	92.9	92.9	72	90	91	91	5	2	1	0
7	90.5	99.4	84	88	93	100	3	2	2	2
8	91.7	92.3	60	90	90	90	7	5	3	3
9	88.1	82.1	64	64	86	81	5	4	1	2
10	91.7	96.4	72	90	95	95	4	2	1	1
Media	81.3	83.3	63.5	76.8	83.3	84.4	5.7	3.6	1.9	1.9

BMI: body mass index; F: female; KOOS: knee injury and osteoarthritis outcome score; M: male; VAS: visual analog scale.

Results

The series included 6 male and 4 female patients, with a mean age of 30.6 years (range: 16–50 years). The intervened knee was the right in 7 cases (70%) and the left in 3 cases (30%). We recorded 9 cases of medial meniscectomy and 1 lateral. The mean body mass index was 24.5 kg/m² (range: 20.8–27.6 kg/m²). The mean time elapsed between previous meniscectomy and placement of the implant was 20 months (range: 12–36 months). The mean follow-up period was 34.7 months (range: 24–46 months).

Surgical findings

Assessment of the cartilage showed an ICRS classification of 0 in all compartments and in all patients except for 1 case, the eldest in the sample, who had chondral changes of grade 2 in the medial femoral condyle.

Clinical results

The functional results are summarized in [Table 2](#).

We found differences between the results of the Lysholm scale measured in the preoperative period (mean 63.5 points) compared to the results obtained after 1 year (mean 83.3 points) ($p = .005$) and at the end of the follow-up period

(mean 84.4 points) ($p = .005$), but not between the results obtained 1 year after the surgery and those obtained at the end of the follow-up period ($p = .350$).

We observed statistically significant differences between the mean KOOS score obtained in the preoperative period (64.23 points) and the mean value obtained after 6 months follow-up (73.66 points) ($p = .001$), 1 year after the surgery (81.39 points) ($p < .001$) and at the end of the follow-up period (83.34 points) ($p < .001$).

Regarding the VAS data, we found statistical differences between the preoperative period (mean value of 5.7 points), 6 months after the intervention (mean value of 3.6 points) ($p = .040$), 1 year after the intervention (1.9 points) ($p = .040$) and the end of the follow-up period (1.9 points) ($p = .050$). There were no differences between the results 1 year after the surgery and those obtained at the end of the follow-up period ($p = 1$).

The period before the surgery did not seem to notably influence the final results, as it did not present any correlation with the Lysholm scale ($p = .430$), KOOS scale ($p = .530$) and final VAS scale ($p = .890$) recorded at the end of the study. The BMI of the patients did not show any correlation with the other variables.

Radiographic results

The radiographic results are summarized in [Table 3](#).

Table 2 Morphological criteria and MRI signal intensity based on the work of Genovese et al.¹⁴

Characteristic	Type 1	Type 2	Type 3
Morphology and size	Fully reabsorbed implant	Small implant with regular and/or irregular morphology	Implant with identical shape and size to a normal meniscus
Signal intensity	Markedly hyperintense	Moderately hyperintense	Isointense compared to a normal meniscus

Table 3 Magnetic resonance imaging: morphological characteristics and signal intensity of the implant/meniscus complex at 1 year and at the end of the follow-up period.

Characteristic	Type 1			Type 2			Type 3		
		1 year	Final		1 year	Final		1 year	Final
Morphology and size	Fully reabsorbed implant			Small implant with regular and/or irregular morphology			Implant with identical shape and size to a normal meniscus		
Signal intensity	Markedly hyperintense	0 1 year	0 Final	Moderately hyperintense	5 1 year	10 Final	Isointense compared to normal meniscus	5 1 year	0 Final
		6	4		4	6		0	0

The simple radiographic study did not show any degenerative changes or narrowing of the joint interline (Ahlbäck grade 0), except in the case with the worst evolution, which progressed to grade 1 at the end of the follow-up period.

In the MRI scan, the meniscal implant was of the same size as the normal meniscus (type 3) in 5 patients 1 year after the surgery (Fig. 2), but at the end of the follow-up period the size had decreased in all patients. None of the cases had a morphology classified as type 1, either at 6 months, 1 year or at the final follow-up. The intensity of the MRI signal decreased progressively but did not reach that of a normal meniscus in any case.

Complications

The only complications observed initially were the onset of hemorrhage in the immediate postoperative stage in 3 of the patients (30%), all treated by arthrocentesis. Four months after the intervention the problem had been resolved in all patients.

In 1 patient, the eldest and with the worst evolution, an MRI scan obtained 2 years after the surgery showed extrusion of the implant with a type 2 morphology and type 1 signal (Fig. 3). We conducted an arthroscopy due to the persistence of pain and observed a progression of the degenerative changes of the cartilage of the medial condyle (ICRS 3). The implant was fully integrated into the anterior horn of the meniscus, with a similar morphology to a normal meniscus in this area (Fig. 4A), but showed fibrillation and tear in

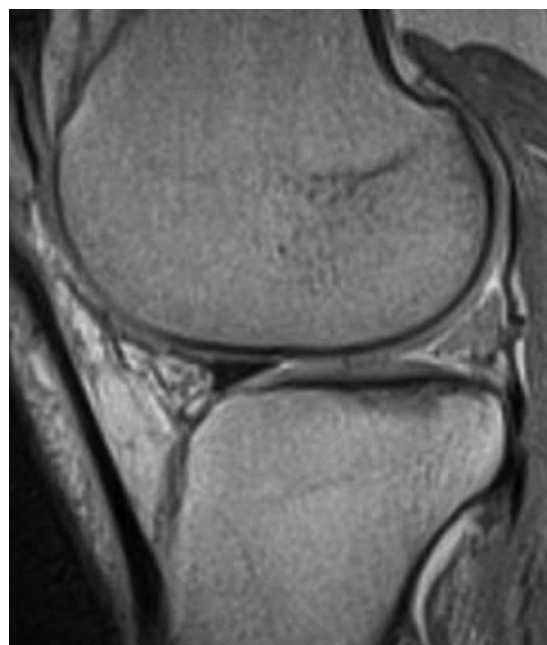


Figure 2 Sagittal T1-weighted spin-echo MRI at 1.5T after 1 year. The size of the implant in this case is the same as the normal meniscus (type 3). Signal intensity remains increased (type 1).

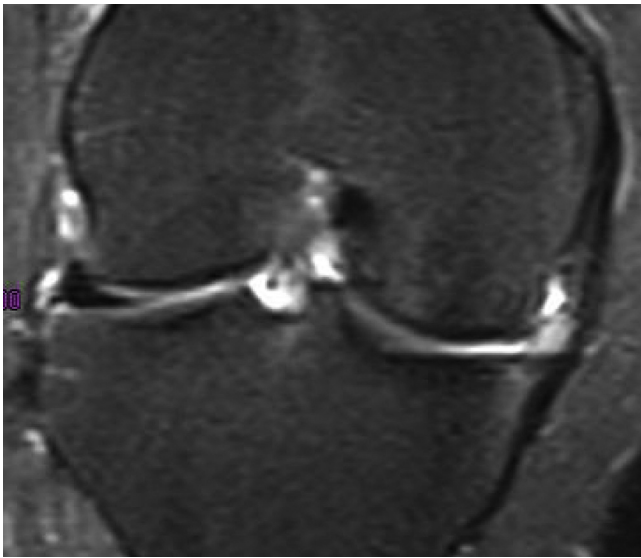


Figure 3 Coronal T2-enhanced image 2 years after the failed implant. The size of the implant is type 2 and the intensity of the signal is type 1. The image shows extrusion of the implant and degenerative changes in the medial compartment.

its posterior part, with a yellowish color (Fig. 4B). A biopsy from the medial part of the implant showed the presence of fibrocartilage with similar characteristics to those of a normal meniscus in hematoxylin and eosin staining (Fig. 5). The implant was left *in situ* and the sutures were removed.

Discussion

All the results of the clinical assessment scales employed showed a significant improvement. This improvement was progressive until 1 year after the surgery, when all the scores stabilized. In a series of 10 patients, Efe et al.¹⁶ showed that, in the short-term, the Actifit® implant could be safely used to treat segmental defects of the medial meniscus which caused pain and functional limitation, enabling a clinical improvement which manifested after 6 months and increased progressively until 12 months. The series of

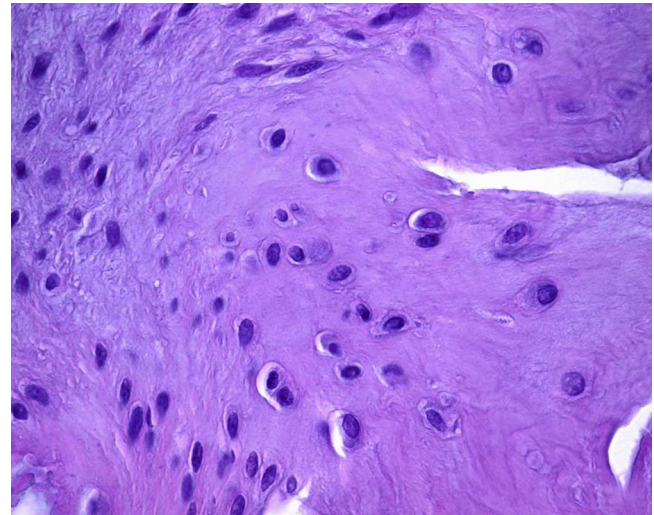


Figure 5 Hematoxylin and eosin (400×) staining of the biopsy taken from the central part of the implant showing the growth of the fibrocartilage.

De Coninck et al.¹⁷ also showed improvement in VAS, IKDC, Lysholm and KOOS.

Unlike the series of Verdonk et al.,¹² in which the improvement of all the clinical indicators progressed until 24 months, in our series, despite being significant at 6 months in all patients except for 1, it increased only up to 1 year, whereupon it reached its maximum value and did not vary after that point.

Condition of the cartilage and meniscus

In a multicenter study with 52 patients, Verdonk et al.¹¹ observed the growth of tissue within the meniscus implants through histological results and MRI in 81.4% of cases. Of these, 44 underwent a second arthroscopy 1 year later and the biopsies showed the presence of fibrocartilaginous tissue similar to the normal meniscus and integration of the implant with the native meniscus.

In the only case in our series to undergo a second arthroscopy, the histological data obtained showed the

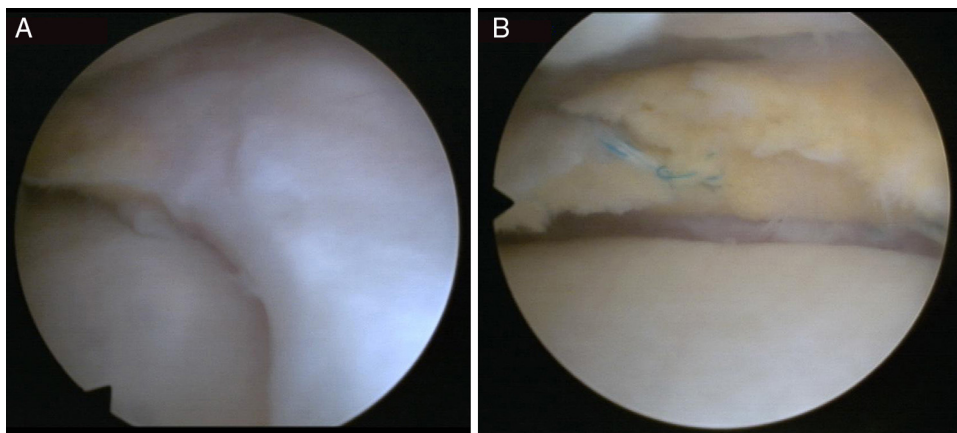


Figure 4 Arthroscopic view of the second exploration of the failed meniscal implant. (A) Complete union with the native meniscus in its anterior horn. (B) The posterior area of the implant shows fibrillation and rupture.

presence of chondral tissue with similar characteristics to those of the native meniscus and full integration within it in the anterior horn.

Unlike the series of Efe¹⁶ and Verdonk,¹¹ in which an improvement of the characteristics of the cartilage after 12 months was observed in 20% and 17.5% of cases, respectively, in our study the only patient who already suffered a basal cartilage alteration at the time of the surgery experienced a progression of degenerative changes.

Radiography

In our series, like in that of Verdonk et al.,¹¹ the MRI showed that the implant did not produce an inflammatory reaction, synovitis or adverse effects in the remaining compartments of the knee.

Spencer et al.¹⁸ assessed the images obtained from a group of patients treated with Actifit® with a follow-up period of up to 36 months and did not observe a progression of the arthrosic changes. The implants showed adequate structural integrity. However, the MRI signal of the tissue regenerated in the implant did not show a differentiation into fibrocartilage, but rather a signal corresponding to edema which persisted until 19 months after the intervention. Efe et al.¹⁶ did not observe reabsorption of the implants and after 1 year all of them showed a hyperintense signal (Genovese type 2). In our study we observed similar results, but with a longer follow-up period, with a reduction in the size of the implants in 100% of the knees, without being reabsorbed, but without showing an MRI signal resembling that of a normal meniscus in any case. However, these findings did not prevent improvement of the clinical parameters of the patients. This lack of correlation between the clinical results and the appearance and the size of the resulting meniscus has been reported previously in other works, with both polyurethane¹⁷ and collagen^{9,14} implants.

Limitations

The main limitations of this study are the small sample size and the lack of a control group. One possibility would be to compare the results obtained in this group with a control group which followed a conservative treatment or arthroscopic lavage.

Further studies with a larger number of cases, preferably randomized and with a longer time of evolution, are required to assess whether the implant is effective in providing a chondroprotective effect.

Conclusions

In this series of cases we found a significant improvement in the short term in all the clinical parameters. The procedure failed in one of the patients. The size of the implant was reduced and none of the cases achieved a similar MRI signal to that of a normal meniscus.

The procedure proved to be safe and useful to treat persistent pain after meniscectomy.

Level of evidence

Level of evidence IV.

Ethical disclosures

Protection of human and animal subjects. The authors declare that no experiments were performed on humans or animals for this study.

Confidentiality of data. The authors declare that no patient data appear in this article.

Right to privacy and informed consent. The authors declare that no patient data appear in this article.

Conflict of interests

The authors have no conflict of interests to declare.

References

1. Fairbanks TJ. Knee joint changes after meniscectomy. *J Bone Joint Surg Br.* 1948;30:664–70.
2. Lee AS, Kang RW, Kroin E, Verma NN, Cole BJ. Allograft meniscus transplantation. *Sports Med Arthrosc.* 2012;20:106–14.
3. Brophy RH, Matava MJ. Surgical options for meniscal replacement. *J Am Acad Orthop Surg.* 2012;20:265–72.
4. Harston A, Nyland J, Brand E, McGinnis M, Caborn DN. Collagen meniscus implantation: a systematic review including rehabilitation and return to sports activity. *Knee Surg Sports Traumatol Arthrosc.* 2012;20:135–46.
5. Pereira H, Frias AM, Oliveira JM, Espregueira-Mendes J, Reis RL. Tissue engineering and regenerative medicine strategies in meniscus lesions. *Arthroscopy.* 2011;27:1706–19.
6. Rodkey WG, DeHaven KE, Montgomery WH III, Baker CL Jr, Beck CL Jr, Hormel SE, et al. Comparison of the collagen meniscus implant with partial meniscectomy. A prospective randomized trial. *J Bone Joint Surg Am.* 2008;90:1413–26.
7. Zaffagnini S, Giordano G, Vascellari A, Bruni D, Neri MP, Iacono F, et al. Arthroscopic collagen meniscus implant results at 6 to 8 years follow up. *Knee Surg Sports Traumatol Arthrosc.* 2007;15:175–83.
8. Bulgheroni P, Murena L, Ratti C, Bulgheroni E, Ronga M, Cherubino P. Follow-up of collagen meniscus implant patients: clinical, radiological, and magnetic resonance imaging results at 5 years. *Knee.* 2010;17:224–9.
9. Monllau JC, Gelber PE, Abat F, Pelfort X, Abad R, Hinarejos P, et al. Outcome after partial medial meniscus substitution with the collagen meniscal implant at a minimum of 10 years' follow-up. *Arthroscopy.* 2011;27:933–43.
10. Verdonk R, Verdonk P, Huisse W, Forsyth R, Heinrichs EL. Tissue ingrowth after implantation of a novel, biodegradable polyurethane scaffold for treatment of partial meniscal lesions. *Am J Sports Med.* 2011;39:774–82.
11. Verdonk P, Beaufils P, Bellemans J, Djian P, Heinrichs EL, Huisse W, et al., Actifit Study Group. Successful treatment of painful irreparable partial meniscal defects with a polyurethane scaffold: two-year safety and clinical outcomes. *Am J Sports Med.* 2012;40:844–53.
12. Sethi PM, Cooper A, Jokl P. Technical tips in orthopaedics: meniscal repair with use of an in situ fibrin clot. *Arthroscopy.* 2003;19:E44.

13. Ahlbäck S, Rydberg J. X-ray classification and examination techniques in gonarthrosis. *Lakartidningen*. 1980;77:2091–3.
14. Genovese E, Angeretti MG, Ronga M, Leonardi A, Novario R, Callegari L, et al. Follow-up of collagen meniscus implants by MRI. *Radiol Med*. 2007;112:1036–48.
15. Lysholm J, Gillquist J. Evaluation of knee ligament surgery results with special emphasis on use of a scoring scale. *Am J Sports Med*. 1982;10:150–4.
16. Efe T, Getgood A, Schofer MD, Fuchs-Winkelmann S, Mann D, Paletta JR, et al. The safety and short-term efficacy of a novel polyurethane meniscal scaffold for the treatment of segmental medial meniscus deficiency. *Knee Surg Sports Traumatol Arthrosc*. 2012;20:1822–30.
17. De Coninck T, Huysse W, Willemot L, Verdonk R, Verstraete K, Verdonk P. Two-year follow-up study on clinical and radiological outcomes of polyurethane meniscal scaffolds. *Am J Sports Med*. 2013;41:64–72.
18. Spencer SJ, Saithna A, Carmont MR, Dhillon MS, Thompson P, Spalding T. Meniscal scaffolds: early experience and review of the literature. *Knee*. 2012;19:760–5.