

ORIGINAL ARTICLE

**Superior capsular reconstruction of irreparable rotator
cuff tear using autologous hamstring graft** ☆



A.P. Rosales-Varo^{a,*}, M. Zafra^b, M.A. García-Espona^c, M.A. Flores-Ruiz^d, O. Roda^e

^a Área de Traumatología, Hospital de Torrecárdenas, Almería, Spain

^b Instituto Traumatológico de Córdoba, Córdoba, Spain

^c Área de Radiodiagnóstico, Hospital de Torrecárdenas, Almería, Spain

^d Área de Traumatología, Hospital del Mar, Cádiz, Spain

^e Departamento de Anatomía Humana y Embriología, Facultad de Medicina, Universidad de Granada, Granada, Spain

Received 24 December 2017; accepted 19 August 2018

KEYWORDS

Superior capsule;
Irreparable;
Rotator cuff;
Autograft;
Hamstring

Abstract

Objective: The aim of this study was to investigate the clinical results and radiographic findings after superior capsular reconstruction (SCR) of postero-superior symptomatic irreparable rotator cuff tears (PSIRCT) using a new SCR technique using autologous hamstring graft.

Material and methods: From 2014 to 2016, 8 shoulders of 8 patients (mean age 59.6 years) with PSIRCT underwent SCR using autologous hamstring graft.

Physical examination, X-ray and MRI were performed before the surgery and 12 months after it. A descriptive analysis was performed of the variables, and the non-parametric test of signs comparing the measurements taken before the operation and 12 months after it.

Results: We found an improvement in the Constant test from 49 before the SCR to 77.25 one year after the operation. The mean active flexion significantly increased from 99.3° to 142.5°. The mean preoperative AH distance increased from 5.25 (range from 3 to 7) before surgery to 8.18 (range from 6 to 10.5) after the SCR. There were no tears of the graft during follow-up.

Conclusion: SCR with a hamstring graft improves the function of the shoulder in PSIRCT, and is an alternative technique for treating these injuries without closing the door to other types of surgery.

© 2018 SECOT. Published by Elsevier España, S.L.U. All rights reserved.

☆ Please cite this article as: Rosales-Varo AP, Zafra M, García-Espona MA, Flores-Ruiz MA, Roda O. Reconstrucción de la cápsula superior en las roturas irreparables del manguito mediante injerto autógeno de isquiotibiales. Rev Esp Cir Ortop Traumatol. 2019;63:1–6.

* Corresponding author.

E-mail address: aprosalesv@gmail.com (A.P. Rosales-Varo).

PALABRAS CLAVE

Cápsula superior;
Irreparable;
Manguito de los
rotadores;
Autoinjerto;
Isquiotibiales

Reconstrucción de la cápsula superior en las roturas irreparables del manguito mediante injerto autógeno de isquiotibiales

Resumen

Objetivo: El objetivo de este estudio es investigar los resultados clínicos y los hallazgos radiográficos tras la reconstrucción de la cápsula superior (RCS) en las roturas irreparables posterosuperiores sintomáticas (RIPS) del manguito de los rotadores mediante una nueva técnica de RCS utilizando injerto autógeno de isquiotibiales.

Material y métodos: Desde 2014 hasta 2016, 8 hombros en 8 pacientes (edad media de 59,6 años) con RIPS fueron tratados con la RCS utilizando injerto autógeno de isquiotibiales. El examen físico, Rx y RM fueron realizados antes de la cirugía y a los 12 meses. Se ha realizado un análisis descriptivo de las variables y se ha utilizado test no paramétrico de los signos para comparar las medidas tomadas antes de la cirugía y a los 12 meses.

Resultados: Encontramos una mejoría en el test de Constant: de 49 antes de ser intervenido a 77,25 al año de la RCS. La media de flexión activa aumentó de forma significativa de 99,3° a 142,5°. La distancia media HA preoperatoria aumentó de 5,25 mm (rango de 3 a 7 mm) antes de la cirugía a 8,18 mm (rango de 6 a 10,5) tras la RCS. No hubo roturas del injerto durante el seguimiento.

Conclusión: La RCS con injerto de isquiotibiales mejora la función del hombro en las RIPS. Es una técnica alternativa al tratamiento de dichas lesiones sin cerrar las puertas a otras cirugías. © 2018 SECOT. Publicado por Elsevier España, S.L.U. Todos los derechos reservados.

Introduction

Treating patients with irreparable rotator cuff tear remains a challenge for orthopaedic surgeons. Several surgical treatments have been used, such as: debridement with or without biceps tenotomy,¹⁻⁴ partial repair,⁵⁻¹⁰ tendon transfer,^{11,12} interposition grafting¹³⁻¹⁵ or reverse prosthesis.¹⁶ However, the results of these techniques are not optimal for treating young patients.

There is now a new option, originally developed by Dr. Mihata,¹⁷ who demonstrated the importance of the superior capsule of the shoulder as a stabilising structure, so that in the event of a postero-superior irreparable symptomatic tear (PSIRCT) the capsule at least, should be reconstructed in an attempt to restore the shoulder's normal fulcrum, and thus enable shoulder stability and function. In the original description, superior capsule reconstruction (SCR) was performed with fascia lata. There is no information on this reconstruction using an autologous graft other than fascia lata.

The aim of this study was to research the clinical results and radiographic findings after SCR for PSIRCT using a new SCR technique using autologous hamstring graft.

Our hypothesis was that SCR using the hamstring could increase the acromiohumeral (AH) distance and improve the functional results of PSIRCT.

Materials and methods

A clinical, prospective study, on a pilot sample of 8 patients to evaluate the clinical results and radiographic findings of an SCR using autologous hamstring graft.

The subjects included in the study were patients on the waiting list from our hospital's clinics, who were admitted between 2015 and 2016 with a PSIRCT, and who met the following inclusion criteria: complete irreparable tear of the supraspinatus or infraspinatus; conservative treatment failure; no or minimal joint degeneration; aged between 40 and 65 years at the time of first consultation, and having given their written consent for intervention.

A tendon was considered irreparable when it could not be repaired to its original footprint at the major tuberosity and, although the final decision was intraoperative, we were guided by various signs of irreparability such as: upper migration of the humerus with an AH distance of less than 7 mm, Patte stage 3 tendon retraction, Goutallier grade 3 and 4 fatty infiltration, and Thomazeau's stage 3 muscle atrophy.

The exclusion criteria were: joint degeneration (Hamada¹⁸ stages 3, 4 or 5), severe upper migration of the humeral head that did not descend with arm traction, deltoid deficiency, irreparable injury to the subscapularis or shoulder rigidity.

The patients were assessed by the same surgeon in the clinic, with a standard history and physical examination that included the Constant and SST test, before the operation, and at 12 months following it. Forward flexion was measured at the patient's side, with the axis of the goniometer arm over the arm axis, and the other goniometer arm following the trunk axis, supported on the ribcage. We measured external rotation in front of the patient asking them to perform active and non-painful external rotation manoeuvres; we measured internal rotation from behind the patient, and asked them to perform active, non-painful internal rotation manoeuvres; we observed the point that they could reach with the tip of the thumb. We assessed strength with a

dynamometer: the patient's spine supported by the back of a chair, they lifted their arm on the plane of the scapula, with their hand in pronation and palm facing towards the floor. Tying the strap to the proximal hook of the dynamometer supported by the wrist, we pulled the distal hook downwards exerting constant force, and the cursor showed us on the scale the kg that the patient managed to bear. We took 3 measurements, and took the maximum score achieved as the benchmark.

An imaging study was performed using plain X-rays in 2 views (true AP and Y). Glenohumeral degeneration was also measured by the Hamada scale, and AH distance by the method described by Ellman.¹⁹ MR images were taken on the coronal, sagittal and axial planes, enabling us to assess the type of tear, its size, its retraction, enabling us to assess the quality of the tendons affected, and to gain an idea of its repair capacity. We assessed fatty degeneration using Goutallier's system.²⁰ The plain X-rays and MRI were undertaken preoperatively, and at one year's follow-up.

All the interventions were performed under general anaesthesia, with the patient in the deckchair position, and by the same surgeon. After the superior approach, the irreparability was assessed of the tendon tear and of the tendons involved. Only one patient underwent subacromial decompression due to a type 3 acromion. Once the injury had been assessed, the SCR was performed with a hamstring allograft. After gentle debridement of the upper area of the glenoid and the footprint of the greater tuberosity, medial fixation was obtained to the glenoid bone in its upper area, at 12 o'clock, from the central area of the graft (with metallic screw 5 with 4 strands). Lateral fixation was also obtained (with the same type of screw as in the glenoid cavity) of the 2 ends of the graft in the humeral head at two points: one antero-superior, next to the entry area of the bicipital groove and to the area of the interval and subscapularis; and a second fixed behind, in the postero-superior area near the infraspinatus, which was also sutured to the plasty (Figs. 1–3). The lateral fixation was performed under tension and in an arm position at about 30° abduction, neutral rotation, and 20–30° flexion.

All the subjects followed the same protocolised rehabilitation regimen, using a sling for 2 weeks, starting passive

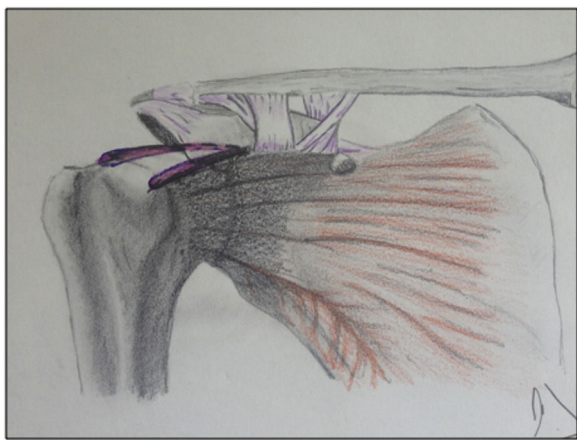


Figure 1 Drawing of the superior capsule reconstruction with hamstring allograft.

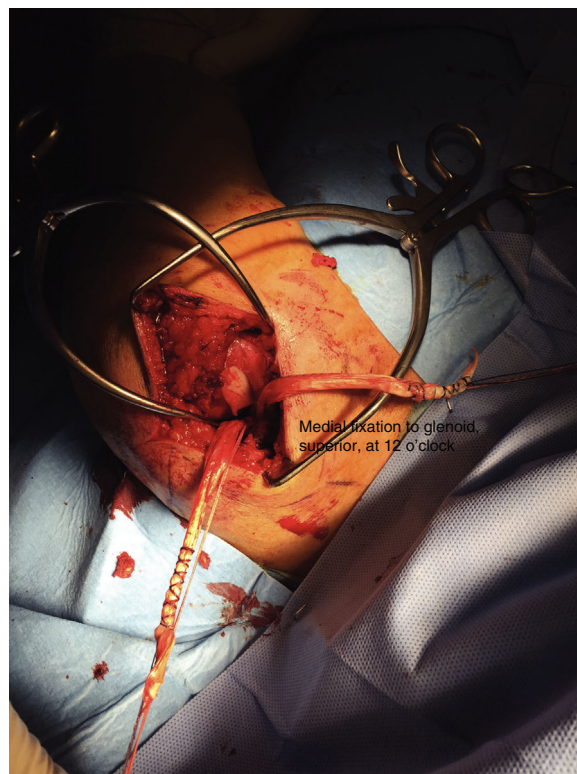


Figure 2 Intraoperative image with graft anchor in the glenoid at 12 o'clock.

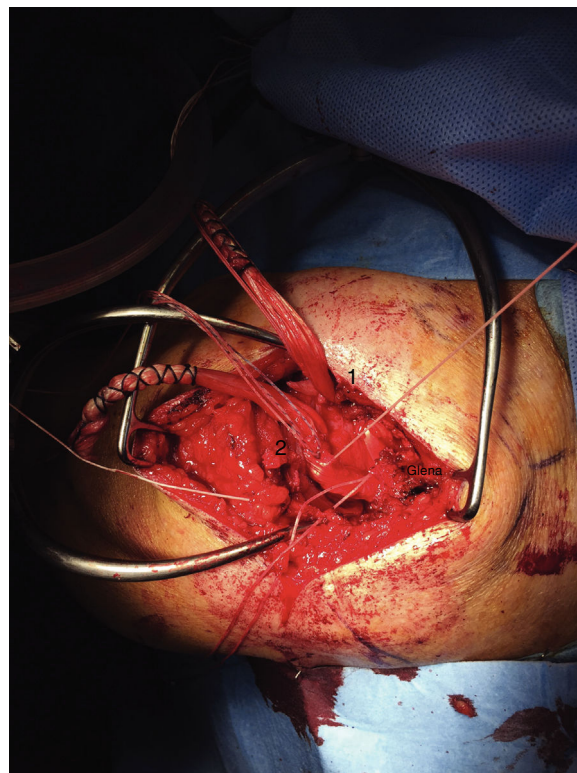


Figure 3 Intraoperative image of lateral fixation in the humeral head at 2 points: (1) antero-superior, next to the entry area to the bicipital groove, tenodesis with the biceps; (2) behind, fixation in the postero-superior area near the infraspinatus, which must be fixed to the plasty.

Table 1 Summary of the patients.

Shoulder	Age	Sex	Work	Duration of symptoms	Surgery	Tendon	Hamada
1	58	M	Manual	24	1st	SS	1
2	62	M	Manual	12	2nd	SS/IS	2
3	60	F	Housewife	60	1st	SS/IS	2
4	63	F	Manual	48	1st	SS/IS	2
5	55	F	Manual	24	1st	SS	1
6	58	M	Manual	12	1st	SS	2
7	50	M	Manual	12	1st	SS/IS	2
8	60	F	Housewife	12	1st	SS	1
<i>Mean</i>	<i>58.25</i>	<i>25</i>					

exercises at 2 weeks, active exercises at 6–8 weeks, and strengthening exercises for the cuff and scapula stabilisers from 10 to 12 weeks.

A descriptive analysis of the variables was performed, and the non-parametric sign test was used, comparing the measurements taken before the operation, and at 12 months after it.

Results

Four males and four females were operated, with a mean age of 59.66 years (range from 55 to 63 years) at the time of the surgery. The mean duration of symptoms (pain and functional) before the operation was 25.3 months (from 12 to 60 months). The stage of arthrosis prior to surgery was classified using the Hamad system²¹: we found 3 shoulders in stage 1, and 5 in stage 2 (Table 1).

The non-parametric signs test was used, with statistically significant differences in the Constant test ($p < .01$). We observed an improvement from 49 before the SCR to 77.25 one year after it.

The range of active motion significantly improved after the SCR until the end of follow-up (12 months). Mean active flexion increased from 99.3° preoperatively to 142.5° ($p < .01$); mean external rotation increased from 32.5° to 43.7° ($p < .01$) (Table 2, Fig. 4).

There were no surgical, intraoperative or postoperative complications in the year of follow-up.

Table 2 Summary of the patients' range of motion.

Shoulder	Flexion		Active ext. rot.	
	Preop.	Postop.	Preop.	Postop.
1	135	180	30	50
2	90	150	30	50
3	45	90	20	30
4	45	80	30	40
5	135	160	50	50
6	120	180	40	50
7	45	180	30	30
8	135	180	30	50
<i>Median</i>	<i>105</i>	<i>160</i>	<i>30</i>	<i>50</i>

The mean preoperative AH distance was 5.25 mm (range from 3 to 7 mm), in 5 shoulders it was less than 7 mm. After the SCR, the mean AH distance increased significantly to 8.18 (range from 6 to 10.5) (Table 3).

No tears were observed on MRI during follow-up of the implanted hamstring plasty.

Discussion

The results in this paper show a functional improvement in patients with irreparable rotator cuff tear. In those who underwent a SCR with autologous hamstring graft, we observed, at one year's follow-up, an increased AH distance, and improved active flexion.

Patients with PSIRCT have a defect of the superior joint capsule. SCR for PSIRCT restores superior glenohumeral stability and improves shoulder function.^{22,23}

Because most rotator cuff tears are reparable, the treatment of patients with PSIRCT remains a challenge for orthopaedic surgeons. The available treatments include traditional patch grafts using different materials inserted in the injured tendon, but they have shown a high re-tear rate²⁴⁻²⁶ without significantly altering the AH distance.

Audenaert et al.²⁷ published that the AH distance was not significantly modified after conventional patch grafts placed medially to the tendon, and laterally to the greater tuberosity for massive rotator cuff tears.

Clithrow et al.²⁸ described an autologous hamstring graft reconstruction to augment retracted rotator cuff tendons, attempting to restore the length of the musculotendinous unit, but without performing an SCR.

Despite the interest in this technique, current knowledge on SCR is based essentially on biomechanical studies²⁹⁻³¹: there are few clinical studies on SCR for irreparable rotator cuff tears. In addition to Mihata's classical clinical study with autogenous fascia, with 24 shoulders in 23 patients, we only found one multicentre study with dermal allograft by Denard.³² We saw clear differences between both studies: there was a low rate of graft healing with the dermal allograft (45%), and they found no increase in AH distance one year afterwards, which is different to Mihata's results with autogenous fascia lata. However, 100% of the patients with a healthy graft had successful results, which makes us believe that it is important to prevent the graft tearing after an SCR, and that we must define the type of graft to be used to achieve this outcome.

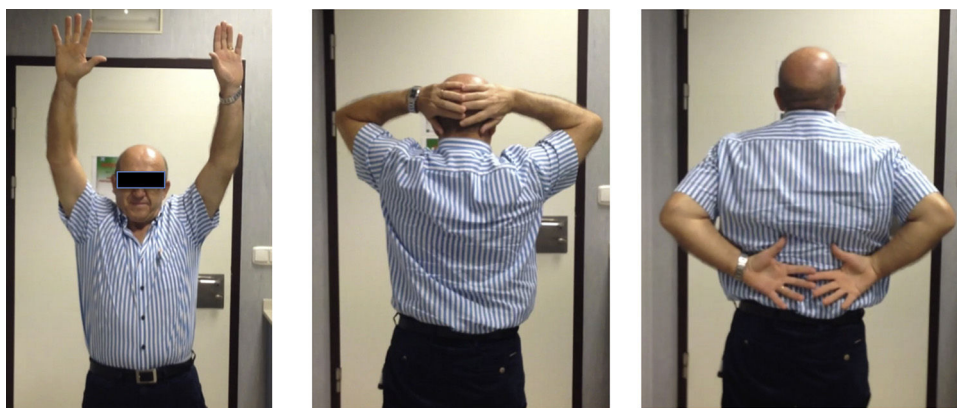


Figure 4 Patient 1, one year after the SCR, the range of motion in flexion, external rotation and internal rotation has been completely restored.

Table 3 Acromiohumeral distance and MRI findings.

Shoulder	AH distance (mm)	
	Preop.	Postop.
1	7	9.5
2	6	8
3	3	7
4	3	6
5	7	8.5
6	5	8.5
7	4	7.5
8	7	10.5
<i>Median</i>	5.5	8.25

Our data indicate that SCR, using the described hamstring graft technique, results in an increased mean AH distance of 5.25–8.18 mm. This is in line with the data published by Mihata²¹ where the SCR, using fascia lata graft, obtained an increased mean AH distance of .46–8.7 mm (significant increase of 4.1 ± 1.7 mm after SCR). We, like this author, had no tears of the graft we used.

The functional results of PSIRCT repair with fatty degeneration of the infraspinatus have been traditionally disappointing. Our results with SCR using hamstring allograft, like those of Mihata, provided improvement, despite fatty infiltration of the infraspinatus.

These data confirm the stabilising role of the superior shoulder capsule, so the rotator cuff is neither the only nor the main stabiliser of the shoulder. It undertakes dynamic action, reinforces stabilisation of the capsule, and restores the strength of the shoulder. This fact explains how when faced with an PSIRCT we can, at least, reconstruct the capsule restoring the normal fulcrum of the shoulder, and thus enable it to become stable and functioning.

This study's limitations are the small number of patients, the lack of a control group, and the short follow-up time. The statistically significant differences, despite the small sample size, are because the effect size (pre- and postoperative difference) is very large.

We believe that it is important to show the preliminary results of this new technique given the current interest

and debate surrounding it, and because there are so few published clinical studies. We are aware that there are important aspects that we do not know, such as the most appropriate graft, the indications or the time it might last, and that we must approach all new techniques with due care.

Conclusions

SCR with hamstring allograft improves the function of the shoulder in PSIRCT: it is an alternative treatment technique for these injuries without closing the door to other surgery.

Level of evidence

Level of evidence III.

Conflict of interests

The authors have no conflict of interests to declare.

References

- Burkhart SS. Arthroscopic debridement and decompression for selected rotator cuff tears. Clinical results, pathomechanics, and patient selection based on biomechanical parameters. *Orthop Clin North Am.* 1993;24:111–23.
- Rockwood CA, Williams GR, Burkhead WZ. Débridement of degenerative, irreparable lesions of the rotator cuff. *J Bone Joint Surg Am.* 1995;77:857–66 [PMID: 7782358].
- Kempf JF, Gleyze P, Bonomet F, Walch G, Mole D, Frank A, et al. A multicenter study of 210 rotator cuff tears treated by arthroscopic acromioplasty. *Arthroscopy.* 1999;15:56–66 [PMID: 10024034].
- Lee B, Cho N, Rhee Y. Results of arthroscopic decompression and tuberopecty for irreparable massive rotator cuff tears. *Arthroscopy.* 2011;27:1341–50.
- Burkhart SS. Fluoroscopic comparison of kinematic patterns in massive rotator cuff tears. A suspension bridge model. *Clin Orthop Relat Res.* 1992:144–52.
- Burkhart SS, Nottage WM, Ogilvie-Harris DJ, Kohn HS, Pachelli A. Partial repair of irreparable rotator cuff tears. *Arthroscopy.* 1994;10:363–70.

7. Duralde XA, Bair B. Massive rotator cuff tears: the result of partial rotator cuff repair. *J Shoulder Elbow Surg.* 2005;14:121–7.
8. Berth A, Neumann W, Awizus F, Pap G. Massive rotator cuff tears: functional outcome after debridement or arthroscopic partial repair. *J Orthop Traumatol.* 2010;11:13–20, <http://dx.doi.org/10.1007/s10195-010-0084-0> [PMID: 20198404].
9. Wellmann M, Lichtenberg S, da Silva G, Magosch P, Habermeyer P. Results of arthroscopic partial repair of large retracted rotator cuff tears. *Arthroscopy.* 2013;29:1275–82.
10. Cuff DJ, Pupello DR, Santoni BG. Partial rotator cuff repair and biceps tenotomy for the treatment of patients with massive cuff tears and retained overhead elevation: Midterm outcomes with a minimum 5 years of follow-up. *J Shoulder Elbow Surg.* 2016;25:1803–9.
11. Gerber C. Latissimus dorsi transfer for the treatment of irreparable tears of the rotator cuff. *Clin Orthop Relat Res.* 1992;152–60.
12. Warner JJ, Parsons IM. Latissimus dorsi tendon transfer: a comparative analysis of primary and salvage reconstruction of massive, irreparable rotator cuff tears. *J Shoulder Elbow Surg.* 2001;10:514–21.
13. Neviaser JS, Neviaser RJ, Neviaser TJ. The repair of chronic massive ruptures of the rotator cuff of the shoulder by use of a freeze-dried rotator cuff. *J Bone Joint Surg Am.* 1978;60:681–4 [PMID: 681390].
14. Bond JL, Dopirak RM, Higgins J, Burns J, Snyder SJ. Arthroscopic replacement of massive, irreparable rotator cuff tears using a GraftJacket allograft: technique and preliminary results. *Arthroscopy.* 2008;24, <http://dx.doi.org/10.1016/j.arthro.2007.07.033>, 403–409.e1 [PMID: 18375271].
15. Mori D, Funakoshi N, Yamashita F. Arthroscopic surgery of irreparable large or massive rotator cuff tears with low-grade fatty degeneration of the infraspinatus: patch autograft procedure versus partial repair procedure. *Arthroscopy.* 2013;29:1911–21 [PMID: 24169146].
16. Farshad M, Gerber C. Reverse total shoulder arthroplasty from the most to the least common complication. *Int Orthop.* 2010;34:1075–82.
17. Mihata T, McGarry MH, Pirolo JM, Kinoshita M, Lee TQ. Superior capsule reconstruction to restore superior stability in irreparable rotator cuff tears: a biomechanical cadaveric study. *Am J Sports Med.* 2012;40:2248–55.
18. Hamada K, Fukuda H, Mikasa M, Kobayashi Y. Roentgenographic findings in massive rotator cuff tears. A longterm observation. *Clin Orthop Relat Res.* 1990:92–6.
19. Ellman H, Hunker G, Bayer M. Repair of the rotator cuff. End-result study of factors influencing reconstruction. *J Bone Joint Surg Am.* 1986;68:1136–44.
20. Goutallier D, Postel JM, Bernageau J, Lavau L, Voisin MC. Fatty muscle degeneration in cuff ruptures. Pre- and postoperative evaluation by CT scan. *Clin Orthop Relat Res.* 1994: 78–83.
21. Hamada K, Fukuda H, Mikasa M, Kobayashi Y. Roentgenographic findings in massive rotator cuff tears. A longterm observation. *Clin Orthop Relat Res.* 1990:92–6.
22. Mihata T, Lee TQ, Watanabe C, et al. Clinical results of arthroscopic superior capsule reconstruction for irreparable rotator cuff tears. *Arthroscopy.* 2013;29:459–70.
23. Mihata T, McGarry MH, Pirolo JM, Kinoshita M, Lee TQ. Superior capsular reconstruction to restore superior stability in irreparable rotator cuff tears: a biomechanical cadaveric study. *Am J Sports Med.* 2012;38:369–74.
24. Moore DR, Cain EL, Schwartz ML, Clancy WG Jr. Allograft reconstruction for massive, irreparable rotator cuff tears. *Am J Sports Med.* 2006;34:392–6.
25. Sclamberg SG, Tibone JE, Itamura JM, Kasraeian S. Six month magnetic resonance imaging follow-up of large and massive rotator cuff repairs reinforced with porcine. *J Shoulder Elbow Surg.* 2004;13:538–41.
26. Soler JA, Gidwani S, Curtis MJ. Early complications from the use of porcine dermal collagen implants (Permacol) as bridging constructs in the repair of massive rotator cuff tears. A report of 4 cases. *Acta Orthop Belg.* 2007;73: 432–6.
27. Audenaert E, van Nuffel J, Schepens A, Verhelst M, Verdonk R. Reconstruction of massive rotator cuff lesions with a synthetic interposition graft: a prospective study of 41 patients. *Knee Surg Sports Traumatol Arthrosc.* 2006;14:360–4 [Epub 2005 Oct 27].
28. Clithrow HD, Bain GI. Rotator cuff augmentation using semitendinosus tendon autograft. *Tech Shoulder Elbow Surg.* 2015;16:43–6.
29. Ishihara Y, Mihata T, Tamboli M, et al. Role of the superior shoulder capsule in passive stability of the glenohumeral joint. *J Shoulder Elbow Surg.* 2014;23:642–8.
30. Mihata T, McGarry MH, Kahn T, Goldberg I, Neo M, Lee TQ. Biomechanical effect of thickness and tension of fascia lata graft on glenohumeral stability for superior capsule reconstruction in irreparable supraspinatus tears. *Arthroscopy.* 2016;32:418–26.
31. Mihata T, Bui CNH, Akeda M, et al. A biomechanical cadaveric study comparing superior capsule reconstruction using fascia lata allograft with human dermal allograft for irreparable rotator cuff tear. *J Shoulder Elbow Surg.* 2017;26: 2158–66.
32. Denard PJ, Brady PC, Adams CR, Tokish MJ, Burkhart SS. Preliminary results of arthroscopic superior capsule reconstruction with dermal allograft. *Arthroscopy.* 2018;34:93–9.