

CASE REPORT

Total knee prosthesis in a patient diagnosed with ochronotic arthropathy[☆]



M. Sabater^{*}, A. Alías, J.M. Segur

Servicio de Cirugía Ortopédica y Traumatología, Hospital Clínic de Barcelona, Barcelona, Spain

Received 4 December 2019; accepted 25 January 2020

KEYWORDS

Total knee arthroscopy;
Ochronosis;
Alcaptonuria;
Homogentisic acid

Abstract Ochronosis is a rare genetic disease of phenylamine and tyrosine metabolism in which an accumulation of homogentisic acid occurs. The accumulation of HGA causes alcaptonuria and deposition in the connective tissue causing a dark colouring of the tissue. In the joints, it can lead to early and very disabling arthropathy, known as ochronotic arthropathy. We present the case of a patient diagnosed with ochronosis and ochronotic arthropathy of the left knee, in which we describe the intraoperative process with the macroscopic and microscopic anatomopathological findings. The patient made good progress after implantation of a total knee prosthesis (TKP), PS type, and was able to follow the same rehabilitation protocol used in patients without ochronotic arthropathy undergoing TKP. The patient showed improvement in the different functional scales, as well as disappearance of pain.

© 2020 SECOT. Published by Elsevier España, S.L.U. This is an open access article under the CC BY-NC-ND license (<http://creativecommons.org/licenses/by-nc-nd/4.0/>).

PALABRAS CLAVE

Artroplastia total de rodilla;
Ocronosis;
Alcaptonuria;
Ácido homogentísico

Prótesis total de rodilla en paciente diagnosticada de artropatía ocrónica

Resumen La ocronosis es una enfermedad genética rara del metabolismo de la fenilamina y de la tirosina en la que se produce un acúmulo de ácido homogentísico (AHG). La acumulación del AHG provoca alcaptonuria y depósito en el tejido conectivo provocando una coloración oscura del mismo. En las articulaciones puede provocar una artropatía temprana muy invalidante, conocida como artropatía ocrónica. Presentamos el caso de una paciente diagnosticada de ocronosis y artropatía ocrónica de la rodilla izquierda en la que describimos el proceso intraoperatorio con las características anatomopatológicas macroscópica y microscópica encontradas.

[☆] Please cite this article as: Sabater M, Alías A, Segur JM. Prótesis total de rodilla en paciente diagnosticada de artropatía ocrónica. Rev Esp Cir Ortop Traumatol. 2021;65:69–72.

^{*} Corresponding author.

E-mail address: msabater@clinic.cat (M. Sabater).

La paciente presenta muy buena evolución tras la implantación de una prótesis total de rodilla (PTR) tipo PS siendo capaz de seguir el mismo protocolo de rehabilitación utilizado en pacientes sometidos a PTR sin artropatía ocrónica. La paciente muestra mejoría de las distintas escalas funcionales, así como desaparición del dolor.

© 2020 SECOT. Publicado por Elsevier España, S.L.U. Este es un artículo Open Access bajo la licencia CC BY-NC-ND (<http://creativecommons.org/licenses/by-nc-nd/4.0/>).

Introduction

Ochronosis consists of recessive autosomal phenylalanine and tyrosine metabolism disease caused by 1,2 homogentisate dioxygenase deficit. This causes an accumulation of homogentisic acid (HGA).¹ The classical clinical triad of this disease is^{1,2}: 1) alkaptonuria: excessive excretion of HGA in urine, which due to oxidation manifests as dark urine; 2) ochronosis: HGA deposition in collagen-rich connective tissue; and 3) ochronotic arthropathy: swiftly progressing arthropathy with brittle tissue due to the accumulation of HGA oxidation products.

HGA accumulation causes the deposition of ochronotic pigment in all connective tissues, especially large joint cartilage and intervertebral discs at the lumbosacral level. The knee is the joint that is affected the most often, and symptoms usually appear after the fourth decade.^{1,3} Although no definitive treatment exists as yet, in published cases arthroplasty shows similar results to those in patients with non-ochronotic arthrosis.^{3,4} We present the case of a 61 year-old female patient diagnosed with ochronosis by the Rheumatology Department of our Hospital, who consulted due to gonalgia.

Clinical case

A 61 year-old woman was referred by the Rheumatology Department to evaluate treatment of degenerative arthropathy of the left knee. The patient showed cutaneous signs of ochronosis, with colouration of the thenar and lateral zones of the fingers of both hands; there was also hyperpigmentation of the sclera and colouration of urine, but no family history explained this.

She had progressive gonalgia that did not respond to conservative treatment. Physical examination showed a reducible varus axis with an articular balance of 0–5–90°. She had preoperative femoropatellar and interlineal internal femorotibial pain with a Knee Society Score⁵ and Western Ontario and McMaster Universities Osteoarthritis Index⁶ of 62/100 and 87, respectively. X-ray images (anteroposterior, lateral and telemetry of the lower limbs) confirmed the symptoms of Ahlbäck grade IV arthrosis (Fig. 1). After the patient had been informed of the therapeutic options and possible adverse effects, she was offered implantation of a cemented (Palacos® with gentamycin) NexGen PS (Zimmer®) total knee prosthesis (TKP). The patient signed the informed consent for surgery and the use of her data for publication.

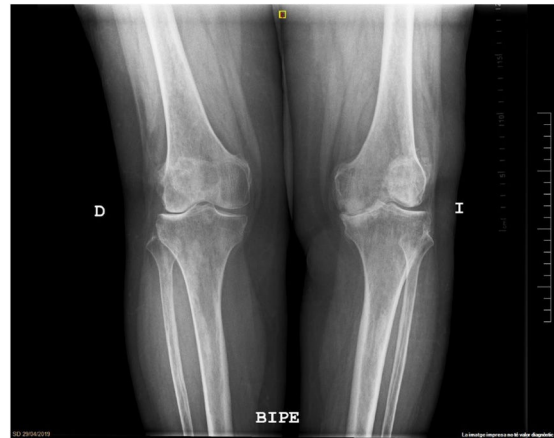


Figure 1 Preoperative X-ray image while standing.

Surgery was performed under spinal anaesthesia with preventive ischemia of the limb. It was performed using an anterior approach with medial parapatellar arthrotomy. Black intratendinous nodules were observed at the level of the extensor apparatus, and the capsule had a withdrawn appearance, with black colouration. The cartilage as well as the menisci and ligaments were hard and brittle, with the same black pigmentation (Fig. 2). Although when cut the bone did not seem to be affected by this colouration, it was softer than normal in consistency. There was a bone defect measuring approximately 0.5 cm × 1.5 cm on the internal plateau of the tibia. This defect was filled with cement, without the need for supplements or cones. A synovial sample was taken and sent to the pathological anatomy department, which confirmed ochronosis. The usual technique in our hospital for PS total knee prosthesis was performed, with the intraoperative infiltration of ropivacaine and adrenalin using local infiltration analgesia technique, without drainages. The patient followed the same fast-track rehabilitation protocol that we usually use in our hospital after this operation, walking on the day surgery took place and with active assisted mobility physiotherapy and isometric and isotonic strengthening exercises. She was discharged on the second day after surgery. There were no complications with the wound, and articular balance improved to 0–0–110°, without pain. 3 months after surgery she was examined clinically and radiographically; the patient stated that she was pain-free and had an articular balance of 0–0–120°, with correct joint stability and a Knee Society Score of 85/100 and a Western Ontario and McMaster Universities Osteoarthritis Index of 20. Conven-

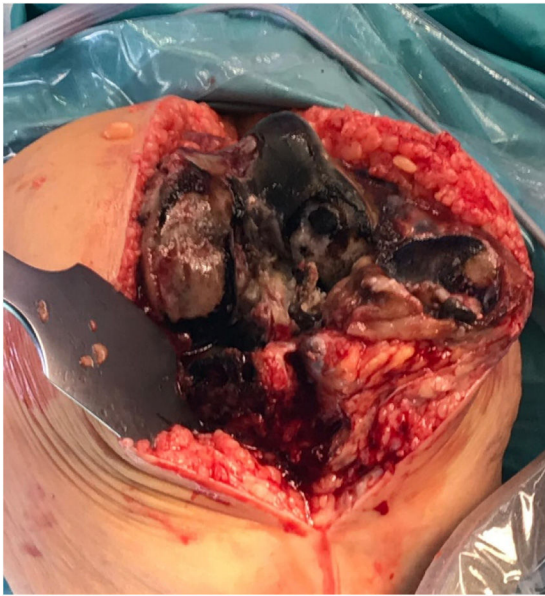

Figure 2 Intraoperative appearance of pigment-impregnated tissues.

tional examination by X-ray was completed using telemetry, showing correct alignment of the operated limb and correct implant position (Fig. 3).

Discussion

This case consisted of a knee affected by ochronotic arthropathy, with good initial clinical results after the implantation of an arthroplasty. Unlike arthropathy due to arthrosis, this type of joint involvement cause swiftly progressing destruction that is highly disabling. It usually affects load-bearing joints such as the hips, knees, shoulders and thoracolumbar spinal column. The knee is usually the most affected joint.^{1,3} Several studies show good results of treatment using prostheses in the knees of patients with this disease.^{3,4,7} Ochronosis is a rare pathological process that is not very well-known in the context of arthroplasty, although it is important that surgeons know how to recognise it, pre-operatively if possible, to thereby overcome any possible intraoperative complications caused by HGA deposit. The complications described in different clinical cases are knee tendon tearing, increased bleeding due to synovial hypertrophy and fractures,^{3,4} none of which were observed in this case.

Diagnosis usually takes place during surgery, when we find ochronotic pigment in a joint. Nevertheless, early diagnosis is important for pre-anaesthetic evaluation, to reduce the risk of any eventual complications.⁸ These patients may have thoracolumbar involvement which affects the type of anaesthesia to be used, or even cardiac or respiratory problems if HGA has accumulated in these tissues.

It is important to be fully aware of tissue involvement during surgery. In our case we saw that cartilage as well as tendons and ligaments were affected by black colouration (Fig. 2). The femoral condyle and medial tibial plateau showed major degeneration, with involvement up to the subchondral bone, although at this level no macroscopic

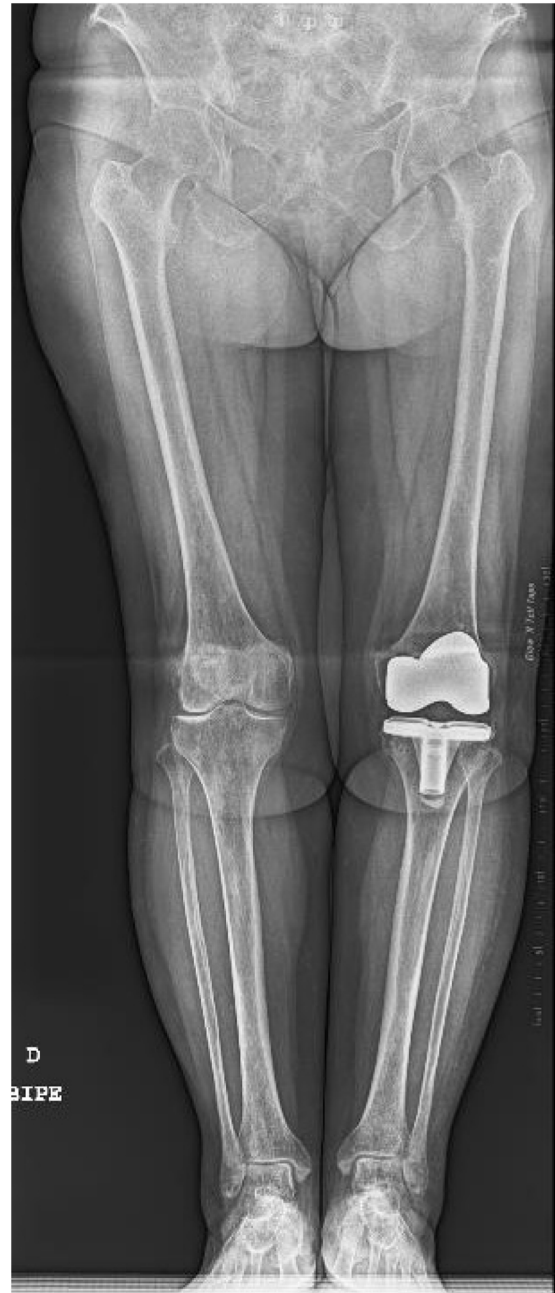

Figure 3 Postoperative X-ray image.

involvement by the pigment was observed. Although when it was cut we found the bone to be normal in colour and without pigment, it was soft in consistency. Respecting this point, several authors in the literature describe the same findings.^{4,7,9,10} Patel⁴ observe the same distribution as in our case, where the pigmentation did not affect the bone, although it was softer in consistency. However, Fisher and Davis¹¹ do not agree with these results, and they believe that the bone structures too are affected by ochronosis, because they report fractures around femoral prostheses after mild trauma in patients with ochronosis and without other risk factors. In our case, unlike the aforementioned studies, pathological anatomy showed normal bone, although with involvement by HGA. Although it is true that the accumu-

lation of this acid takes place in all connective tissues, in the case of bone, as it is subject to a continuous process of remodelling and reabsorption, excess HGA is eliminated,^{9,10} and this is why no pigment accumulation is observed.

In clinical terms the result of implantation of a total knee prosthesis in patients with ochronosis is good. The implant type to be used will be influenced by the bone defect and state of the ligaments, as is the case in primary arthrosis, as ochronosis does not inherently need a more constrictive type of implant or one with a different fixing system. As in our case, different authors report an improvement in pain and the functional scales.^{3,4,7}

To conclude, knee arthroplasty is a good solution for patients with ochronotic knee arthropathy. Clinical suspicion of this condition is important prior to surgery, to be able to undertake correct pre-anaesthetic evaluation and plan for surgery with its possible complications.

Level of evidence

Level of evidence IV.

References

1. Gil JA, Wawrzynski J, Waryasz GR. Orthopedic manifestations of ochronosis: pathophysiology, presentation, diagnosis, and management. *Am J Med.* 2016;129, <http://dx.doi.org/10.1016/j.amjmed.2016.01.010>, 536.e1–6.
2. Ventura-Ríos L, Hernández-Díaz C, Gutiérrez-Pérez L, Bernal-González A, Pichardo-Bahena R, Cedeño-Garcidueñas AL, et al. Ochronotic arthropathy as a paradigm of metabolically induced degenerative joint disease. A case-based review. *Clin Rheumatol.* 2016;35:1389–95, <http://dx.doi.org/10.1007/s10067-014-2557-7>.
3. Mazoochy H, Razi M. Knee and hip joint replacement surgery in a patient with ochronotic arthropathy: surgical tips. *Arch Bone Jt Surg.* 2018;6:577–81.
4. Patel VG. Total knee arthroplasty in ochronosis. *Arthroplast Today.* 2015;1:77–80, <http://dx.doi.org/10.1016/j.artd.2015.03.003>.
5. Insall JN, Dorr LD, Scott RD, Scott WN. Rationale of the Knee Society clinical rating system. *Clin Orthop Relat Res.* 1989;248:13–4.
6. Bellamy N. The WOMAC Knee and Hip Osteoarthritis Indices: development, validation, globalization and influence on the development of the AUSCAN Hand Osteoarthritis Indices. *Clin Exp Rheumatol.* 2005;23 Suppl 39:148e53.
7. Ozmanevra R, Güran O, Karatosun V, Günel I. Total knee arthroplasty in ochronosis: a case report and critical review of the literature. *Ekleml Hastalik Cerrahisi.* 2013;24:169–72, <http://dx.doi.org/10.5606/ehc.2013.36>.
8. Pandey R, Kumar A, Garg R, Khanna P, Darlong V. Perioperative management of patient with alkaptonuria and associated multiple comorbidities. *J Anaesthesiol Clin Pharmacol.* 2011;27:259–61, <http://dx.doi.org/10.4103/0970-9185.81839>.
9. Vigorita VW, Marino PD, Lucas PA. The distribution of ochronosis in osteoarthritic articular cartilage in knee. *HSS J.* 2016;12:76–80, <http://dx.doi.org/10.1007/s11420-015-9464-6>.
10. Doganavsargil B, Pehlivanoglu B, Bicer EK, Argin M, Bingul KB, Sezak M, et al. Black joint and synovia: histopathological evaluation of degenerative joint disease due to Ochronosis. *Pathol Res Pract.* 2015;211:470–7, <http://dx.doi.org/10.1016/j.prp.2015.03.001>.
11. Fisher AA, Davis MW. Alkaptonuric ochronosis with aortic valve and joint replacements and femoral fracture: a case report and literature review. *Clin Med Res.* 2004;2:209–15.