

## Original Article

The Transvaginal Approach in Acute Appendicitis<sup>☆</sup>

Raúl Castro Pérez, \* Luis Ramón Acosta González, Eduardo Dopico Reyes, Juan Carlos Delgado Fernández, Luis Enrique Robaina Arias, Martha Oriolo Estrada

Servicio de Cirugía General, Hospital Provincial Docente Abel Santamaría Cuadrado, Ciudad de Pinar del Río, Provincia de Pinar del Río, Cuba

## ARTICLE INFO

## Article history:

Received 14 November 2010

Accepted 14 November 2010

Available online 11 November 2011

## Keywords:

Transvaginal approach

Acute appendicitis

MA-NOS

Minilaparoscopy

## A B S T R A C T

**Introduction:** The purpose of this work is to present 8 minilaparoscopic-assisted transvaginal appendectomies using rigid instruments in patients with acute appendicitis.

**Material and methods:** Eight minilaparoscopic-assisted transvaginal appendectomies were performed from the 10th of August 2009 to the 30th of June 2010. The inclusion criteria were women between 18 and 65 years of age with a diagnosis of acute appendicitis. The exclusion criteria were palpable masses, appendicular abscesses, ASA III and IV; morbid obesity (BMI>35); gynaecological infections; virgin patients and pregnant women. The surgical intervention was performed with rigid instruments. Surgical time, the need for post-operative analgesics, and post-surgical complications.

**Results:** The age range varied between 18 and 42 years, with a mean of 29.6 years. The mean surgical time was 48.3 min (37–75 min). Analgesics were given to 2 patients after surgery (1 parenteral and 1 oral). Five patients were discharged before 24 h and 3 at 48 h. There were no post-operative complications.

**Conclusions:** Minilaparoscopic-assisted transvaginal appendectomy with rigid instruments, in selected women is a feasible and safe method, and with better aesthetic results than laparoscopic appendectomy, but future studies will be required that can demonstrate its advantages.

© 2010 AEC. Published by Elsevier España, S.L. All rights reserved.

## El abordaje transvaginal en la apendicitis aguda

## R E S U M E N

**Objetivo:** Reportar 8 apendicectomías transvaginales asistidas por minilaparoscopia en pacientes con apendicitis aguda, con el empleo de instrumentos rígidos.

**Material y métodos:** Desde el 10 de agosto del 2009 al 30 de junio del 2010, fueron realizadas 8 apendicetomías transvaginales asistidas por minilaparoscopia. Criterios de inclusión: mujeres entre 18 y 65 años de edad con diagnóstico de apendicitis aguda. Criterios de exclusión: Masas palpables; abscesos apendiculares; Asa III y IV; obesidad mórbida (IMC > 35); infecciones ginecológicas; pacientes vírgenes y gestantes. Las intervenciones quirúrgicas fueron realizadas con instrumentos rígidos. Se estudió el tiempo quirúrgico; necesidad de analgésicos en el postoperatorio y complicaciones postoperatorias.

## Palabras clave:

Abordaje transvaginal

Apendicitis aguda

MA-NOS

Minilaparoscopia

<sup>☆</sup> Please cite this article as: Castro Pérez R, et al. El abordaje transvaginal en la apendicitis aguda. Cir Esp. 2011;89:517–23.

\* Corresponding author.

E-mail address: castro@princesa.pri.sld.cu (R. Castro Pérez).

**Resultados:** El rango de edad fluctuó entre los 18 y 42 años con una media de 29.6 años. El tiempo quirúrgico medio fue de 48,3 min (37-75). En el postoperatorio se administraron analgésicos a 2 pacientes (1 parenteral y 1 oral). El alta hospitalaria se dio a 5 pacientes antes de las 24 horas y en 3 a las 48 horas. No se presentaron complicaciones postoperatorias. **Conclusiones:** La apendicectomía transvaginal asistida por minilaparoscopia con el empleo de instrumentos rígidos, en mujeres seleccionadas, es un método factible, seguro y con mejores resultados estéticos que la apendicectomía laparoscópica, pero serán necesarios estudios futuros que demuestren sus ventajas.

© 2010 AEC. Publicado por Elsevier España, S.L. Todos los derechos reservados.

## Introduction

Acute appendicitis is the condition most often faced by the general surgeon in the emergency department.<sup>1</sup>

For over a century, the treatment of choice for an inflamed caecal appendix was removal via the incision described by McBurney<sup>2</sup> in 1894. For most patients the intervention could be performed through this small incision, so appendectomy was performed with relative ease. Minimally invasive appendectomy was therefore not pursued with the same enthusiasm as for benign diseases of the gallbladder, as it was claimed that there were no advantages over the traditional technique,<sup>3</sup> the operating time was longer<sup>4</sup> and hospital costs were higher.<sup>5</sup> However, laparoscopic appendectomy has gained acceptance and, although there are still some controversial aspects,<sup>6</sup> it has become a familiar technique in emergency general surgery.<sup>7</sup>

Some unconventional approaches have been used to remove this organ without injuring the abdominal wall. For example, gynaecologists have for 60 years been performing incidental appendectomy while performing a vaginal hysterectomy.<sup>8,9</sup>

Recently, after Kalloo et al.<sup>10</sup> demonstrated the possibility of using natural orifices, appendectomies have been reported in patients with acute conditions using flexible endoscopes via peroral transgastric routes<sup>11</sup> and the vaginal orifice.<sup>12</sup>

This article describes our experience treating acute appendicitis with a minilaparoscopy-assisted transvaginal approach, using rigid instruments.

## Patients and Methods

After obtaining permission from the Research Ethics Committee and the patients' informed consent, 8 minilaparoscopy-assisted transvaginal appendectomies were performed in the period from 10th of August 2009 to 30th of June 2010.

Women between 18 and 65 diagnosed with acute appendicitis were operated upon by this method when general surgeons with previous experience in transvaginal cholecystectomies were available to perform emergency surgery. Exclusion criteria were: palpable mass, appendicular abscess, ASA III and IV, morbid obesity (BMI>35), gynaecological diseases, virgins or pregnant women and contraindications for laparoscopic surgery. The operating time, the need for analgesics and postoperative complications were studied.

A gynaecological physical examination, abdominal ultrasound and other studies typical of emergency surgery were

performed. Preoperative antibiotic therapy was indicated according to the department protocol: metronidazole 500 mg and gentamicin 240 mg by intravenous infusion. If a complicated appendicitis (gangrenous or perforated) was diagnosed during the intervention, antibiotic treatment was continued afterwards with the standard frequency and dosages. The administration of oral antibiotics was then re-evaluated, depending on the patient's evolution.

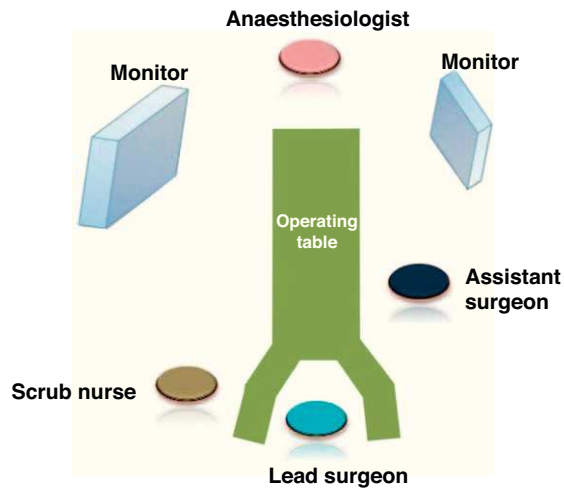
One of the study variables was the need for postoperative analgesics on demand, according to the verbal analogue scale from 0 to 10: patients with mild pain (1-3) were prescribed oral acetaminophen 1 g, or an ampoule of avafortan intravenously if the oral route had not been started; moderate pain (4-7) was prescribed 50 mg tramadol intravenously; and severe pain (8-10) was prescribed intramuscular morphine at 1 mg/kg, due to not having an infusion pump available in the hospital.

General endotracheal anaesthesia and short-term analgesics (fentanyl) were used. Lithotomy position. Disinfection of the abdomen, vagina and perineum using 10% povidone-iodine. Urine was evacuated with a catheter. The operating table was in the Trendelenburg position (on her left side) and the surgical team as shown in Fig. 1. Pneumoperitoneum was at 15 mm Hg, and a 5 mm trocar was inserted in the lower inner edge of the navel with a laparoscope of 5 mm diameter and 45° inserted through it. The abdomen was explored and the diagnosis confirmed. When pus or seropurulent fluid was found in the pouch of Douglas (Fig. 2A), an internal puncture was performed using a vaginal approach while monitoring for evacuation (Fig. 2B), and a sample taken for bacteriological culture.

An 11 mm diameter trocar (Fig. 2C-E) was inserted directly through the vaginal fornix, which led a 10 mm diameter telescope with a working channel of 6 mm (Karl Storz 26034 AAK), see Fig. 2F and G.

The distal end of the appendix was held with a grasper located in the umbilical miniport (Fig. 2H and I). Then, through the working channel of the laparoscope, adhesions were released (Fig. 3A and B), the mesoappendix electrocoagulated with bipolar clamp (Fig. 3C) and sectioned. The base was ligated with an endoloop and the organ amputated with scissors (Fig. 3D).

The stump was treated with monopolar electrocautery and not invaginated. According to its diameter, the appendix was removed within the vaginal trocar cannula (Fig. 3E) or in a laparoscopy bag. The region was irrigated with saline and aspirated (Fig. 3F and G). The vaginal trocar was removed under visual control from the umbilical miniport and the colpotomy was closed with 2 chromic catgut stitches (Fig. 3H).



**Fig. 1 – Position of the surgical team: lead surgeon between the legs of the patient, assistant surgeon to the left, the scrub nurse next to the primary surgeon and the anaesthesiologist in the usual position.**

Outpatient monitoring of patients was scheduled weekly for the first postoperative month, then every month until the third month, then every three months until 1 year after the surgery.

## Results

Eight patients with acute appendicitis underwent minilaparoscopy-assisted transvaginal appendectomies. The ages of the patients were between 18 and 42 years (mean 29.6 years). The mean operating time was 48.3 min (37–75 min).

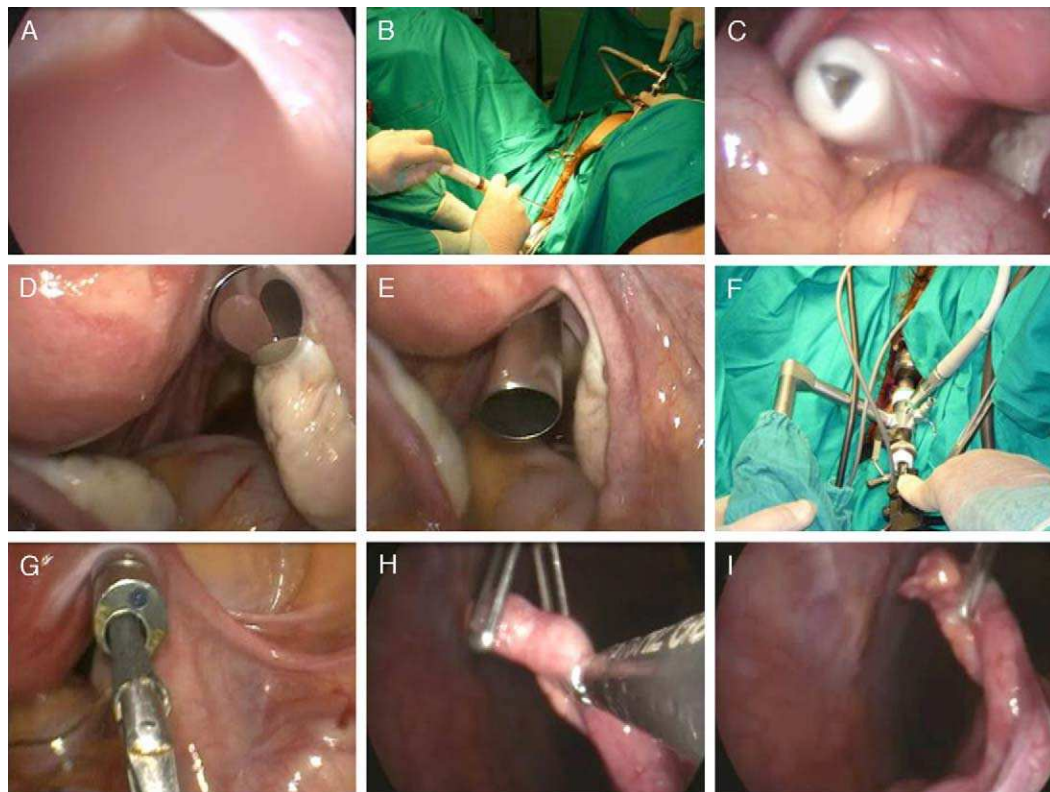
Administration of analgesics was necessary in the post-operative period for 2 patients: one for moderate pain and the other for mild pain. The remaining 6 did not complain of pain.

Five patients were discharged within 24 h and 3 within 48 h. Histological analysis of the samples confirmed the diagnosis of uncomplicated acute appendicitis.

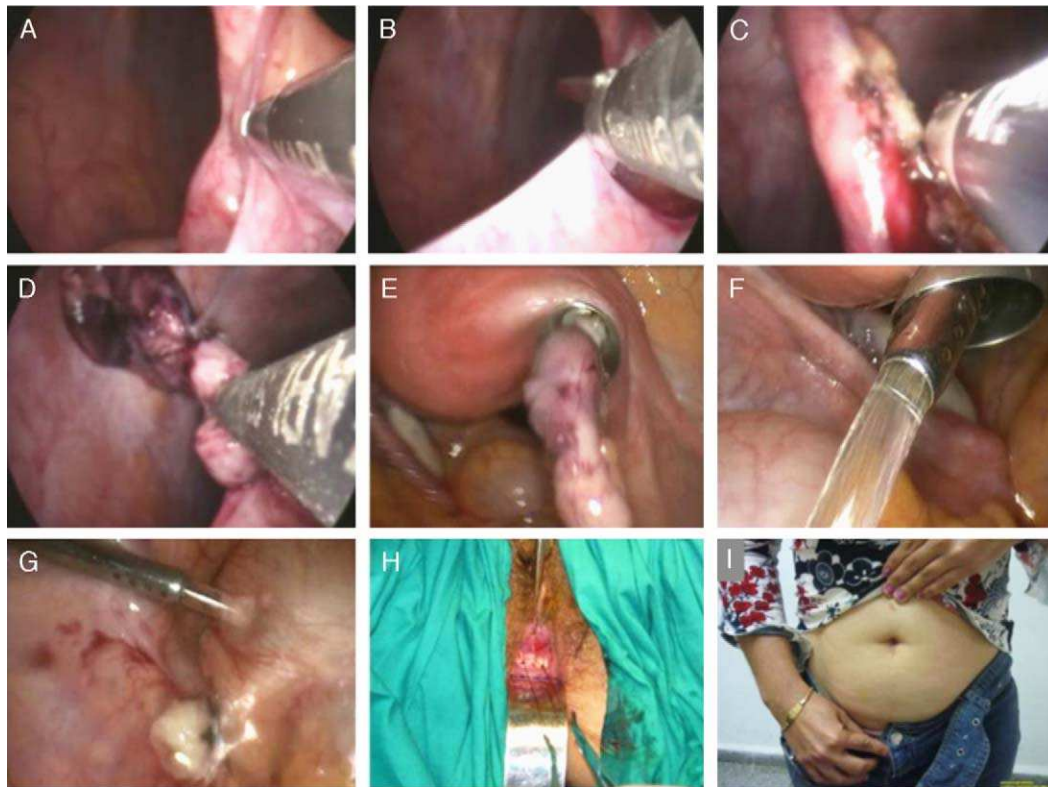
Of the 8 patients, 2 have had their 1-year follow-up, and the remaining 6 patients continue with a regular follow-up, having elapsed between 5 and 11 months (mean 8.1 months) since the operation. No procedure-related complications have been found during this time.

## Discussion

The vagina has been used as a route to the abdomen for more than 100 years. In 1896, Kelly<sup>13</sup> reported ectopic pregnancies treated by colpotomy. But it was Von Ott<sup>14</sup> in 1901 who first used it to observe the peritoneal cavity. Later work by Klapfen, Telinde, Palmer and Decker contributed to the development of culdoscopy,<sup>15</sup> which became very popular as a means of



**Fig. 2 – (A) Pus in the pouch of Douglas; (B) puncture of the pouch of Douglas; (C)–(E) vaginal trocar entry into the peritoneal cavity; (F) external view of the telescope with a working channel; (G) internal view of the telescope with a working channel; (H)–(I) caecal appendix traction from the umbilical miniport.**



**Fig. 3 – (A) and (B) Release of adhesions; (C) electrocoagulation of the mesoappendix; (D) amputation of the caecal appendix; (E) removal of the organ inside the vaginal trocar cannula; (F)–(G) irrigation and aspiration of the region; (H) colpotomy closure; (I) aesthetic result of the intervention.**

diagnosis and for minor surgical procedures. In the 1970s it fell out of favour with gynaecologists who preferred laparoscopy.<sup>16</sup>

In the 1990s, laparoscopic surgery contributed to it being taken up again in some hospitals,<sup>17</sup> which took advantage of the magnification of the images and the long surgical instruments to perform more complex and less aggressive surgical procedures. Also at this time, general surgeons and urologists began to use it as an exit port for large surgical specimens.<sup>18–23</sup> Removals of large gallbladder stones,<sup>18</sup> the spleen,<sup>20,21</sup> kidney<sup>19,22</sup> and colon segments<sup>23</sup> were reported.

Since 1949, when Bueno<sup>8</sup> performed the first transvaginal appendectomy in Spain, gynaecologists performed it during vaginal hysterectomy as an additional operation on normal appendices for purely preventive purposes. They used the same instruments for open surgery and accessed the organ when it was visible from the vagina, provided that it was not attached to adjacent structures and had a very loose mesoappendix.<sup>9</sup>

Pelosi et al.<sup>9</sup> suggested releasing adhesions and the full mobilisation of the organ laparoscopically to then perform the appendectomy through the vagina using the open surgery techniques described before. Tsin et al.<sup>24</sup> were first to do this through the vagina using video-assisted surgery techniques and an abdominal miniport. Placing a 5–12 mm diameter trocar at its top allowed the use of staplers.

However, it was only after the proposal by Kalloo<sup>10</sup> when general surgeons became interested in the vaginal approach

as an entry route to the abdomen. Within a short period of time, there were numerous studies showing that surgery was possible on organs as distant as the gallbladder,<sup>25–28,33–39</sup> liver,<sup>29,41</sup> stomach<sup>30,31</sup> and spleen,<sup>32,42</sup> using either flexible<sup>25–35</sup> or rigid<sup>36–41</sup> instruments, and with the assistance<sup>25–32,36–41</sup> or not<sup>33–35</sup> of miniports in the abdominal wall.

Despite its proximity to the vaginal fornix, transvaginal appendectomies are not reported frequently in patients undergoing surgery for appendicitis. Palanivelu et al.<sup>12</sup> reported the first cases in 2007 on 6 patients using a flexible endoscope. Conversion to laparoscopic surgery because of technical difficulties was required in 3 (50%) of them. The help of a 3 mm diameter miniport in the abdominal wall was needed in 2 cases, and 1 (12.5%) was performed entirely using the vaginal approach (T-NOTES). Bernhardt et al.<sup>43</sup> performed a similar intervention in a woman with subacute appendicitis. Recently, Zorrón et al.<sup>44</sup> reported a series of 37 patients.

To the best of our knowledge, there are no published reports of transvaginal appendectomies in women with acute appendicitis performed with rigid instruments and only a miniport in the abdominal wall.

The 8 appendectomies in our series were performed without difficulty: 5 were oedematous and 3 fibrinopurulent appendicitis. The latter group had pus or seropurulent fluid in the pouch of Douglas, without the organ being perforated or the formation of abscesses. The fluid was aspirated through the vagina, which facilitated the subsequent entry of trocars under internal control. Given that the possibility of postoperative

intraoperative septic complications is not uncommon in acute appendicitis, and that the transvaginal approach may lead to confusion about the origin of any germs (whether from the inflamed organ or the bacterial flora of the vaginal opening), it was decided to take an initial sample of peritoneal fluid for culture analysis to help identify the source of any infection. However, this complication did not occur.

The treatment of the mesoappendix at the base of the organ was always performed through the vaginal port, using the working channel of the endoscope. The umbilical miniport was used only for traction and mobilisation of the appendix. This channel also facilitated the passage of 5 mm diameter clippers. However, if the surgeon requires the use of larger diameter (10 mm) clippers or staplers, the camera can be moved to the umbilical miniport and the staplers inserted through the vaginal port, after removing the telescope with a working channel.

The use of staplers reduces operating time and makes the intervention less difficult,<sup>45,46</sup> by placing a larger diameter (5–12 mm) trocar into the vagina. These were not used for patients treated in our series, because its high cost did not allow it to be used in such a common operation.

Appendectomies were technically easy to perform, so it was possible to perform surgery with only 2 working ports (vaginal and umbilical). However, in difficult cases, such as retrocaecal appendicitis, placing a second port (5 mm diameter) in the vaginal fornix or inserting working instruments adjacent to the 10 mm trocar using the same hole, gives greater opportunities for dissection. In our experience, when performing transvaginal cholecystectomies,<sup>37</sup> we found that inserting instruments through the same trocar hole usually caused gas to escape, necessitating a vaginal tamponade with a wet compresses, which was certainly uncomfortable for the surgeon. So we preferred to insert a second trocar.

The operating time in our series was similar to laparoscopic appendectomies performed in our hospital<sup>47</sup> and in other international studies.<sup>48</sup> However, it was lower than that reported in transvaginal appendectomy using only flexible instruments.<sup>12</sup> None of our patients required conversion to laparoscopic or open surgery, but that may be because we had no complex cases. Five of our patients were discharged from hospital within 24 h of surgery, while the remaining 3 had purulent or seropurulent fluid in the pelvic cavity and were kept under observation for 48 h, without continued preoperative antibiotic treatment.

Although only 2 patients required parenteral or oral analgesic treatment, this was a very small series for these indicators to be assessed objectively.

Hybrid techniques represent an intermediate step between laparoscopic surgery and “pure” surgery through natural orifices (T-NOTES/T-NOS).<sup>17,31,49</sup> They contribute to clinical study and technological innovation, while ensuring greater safety for the patient.

Currently, a hybrid transvaginal appendectomy has advantages over pure ones. Prior to performing a colpotomy, the umbilical miniport allows the peritoneal cavity to be explored and confirms the diagnosis, which is sometimes difficult in a woman.<sup>50</sup> This makes it possible to detect previously undiagnosed endometriosis, which would contraindicate the vaginal route of entry<sup>39</sup>; it provides an opportunity for

the surgeon to identify the exact location of the caecal appendix (which is variable in humans) and to generally assess the degree of difficulty of the intervention. This makes it possible from the outset to decide whether a second working port needs to be placed in the vaginal fornix.

Secondly, internal observation guarantees that entry into the peritoneal cavity is as safe as possible. Despite the experience of gynaecologists with the “blind” opening of the vaginal fornix, where low rates of iatrogenic cases are reported,<sup>51</sup> entry through such a small space is not without iatrogenic injuries to adjacent important organs.<sup>52</sup> Therefore, and because of the growing interest in this surgical approach, gynaecologists have suggested trying new techniques to make the vaginal orifice a safer gateway to the abdomen without any monitoring.<sup>53–55</sup> However, these are not yet widespread, nor are there studies showing any benefits.

In addition, there are no large series published and the vaginal approach has not been studied under the new concept of surgery through natural orifices, where the number and diameter of trocars placed in the vaginal fornix are greater than previously known. They also include new procedures such as direct insertion of trocars into the peritoneal cavity to achieve greater speed and improved sealing,<sup>41</sup> which is a manoeuvre that would be impossible without internal visual inspection.

Finally, an umbilical miniport during surgery ensures adequate assistance. It facilitates dissection manoeuvres, and the entire peritoneal cavity can be irrigated and aspirated through it. Furthermore, if there is generalised peritonitis, a standard 5 mm diameter cannula can be used and the working channel telescope in the vaginal port can be replaced with an extra long one of 30° or 45°.

Anatomically, the right iliac fossa is located very close to the vaginal fornix and is nearly facing it, so it can be addressed without great difficulty using a rigid telescope with a working channel. It is known that the current flexible endoscopes are complex and difficult to use in open areas such as the peritoneal cavity.<sup>31,56,57</sup> Disadvantages include the fact that they are unstable along their axis, which makes positioning manoeuvres difficult in the surgical field.<sup>32</sup> Without the support of the luminal wall, gravity causes the endoscope to settle on other organs as it passes through<sup>58</sup>; their very flexibility limits any transmission of force<sup>59</sup>; their working channels only allow the passage of small diameter instruments which cannot manage the triangulation necessary to perform the dissection operations, due to sliding along parallel channels close together<sup>60</sup>; the optics and working instruments do not have independent sideways movement and move along together simultaneously<sup>61</sup>; in addition, it is difficult to perform quick manoeuvres if there is any bleeding, and as yet there are no adequate tools for haemostasis.<sup>52</sup>

Technological development will surely provide flexible instruments that will play a central role in all surgical activity.<sup>62–64</sup> However, it is not currently possible to dispense with rigid instruments, or the assistance of at least one miniport in the abdominal wall, if safe, efficient and reproducible surgery is required through natural orifices.<sup>31,39</sup>

Minilaparoscopy-assisted transvaginal appendectomy with the use of rigid instruments in selected women with acute appendicitis is a feasible, safe method with better

cosmetic results than laparoscopic appendectomy. However, prospective randomised studies are needed to demonstrate its advantages.

## Conflicts of Interest

The authors have no conflicts of interest to declare.

## REFERENCES

- Pieper R, Kager L. The incidence of acute appendicitis and appendicectomy: an epidemiological study of 971 cases. *Acta Chir Scand.* 1982;148:145.
- McBurney. The incision made in the abdominal wall in cases of apendicitis with a description of a new method of operating. *Ann Surg.* 1894;20:38.
- Temple LK, Litwin DE, McLeod RS. A meta-analysis of laparoscopic versus open appendectomy in patients suspected of having acute appendicitis. *Can J Surg.* 1999;42:377-83.
- Hart R, Rajgopal C, Plews Sweenwy AJ, Davies W, Gray D, Taylor B. Laparoscopic versus open appendectomy: a prospective randomized trial of 81 patients. *Can J Surg.* 1996;39:457-62.
- Johnson AB, Peetz ME. Laparoscopic appendectomy is an acceptable alternative for the treatment of perforated appendicitis. *Surg Endosc.* 1998;12:940-3.
- Korndorffer JR, Fellingner E, Reed W. SAGES guideline for laparoscopic appendectomy. *Surg Endosc.* 2010;24:757-61.
- Nakhamiyayev V, Galldin L, Chiarello M, Lumba A, Gorecki PJ. Laparoscopic appendectomy is the preferred approach for appendicitis: a retrospective review of two practice patterns. *Surg Endosc.* 2010;24:859-64.
- Bueno B. Primer caso de apendicectomía por vía vaginal. *Tokoginec Pract (Madrid).* 1949;8:152-4.
- Pelosi III MA, Pelosi MA. Vaginal appendectomy at laparoscopic-assisted vaginal hysterectomy: a surgical option. *Surg Laparosc Endosc.* 1996;6:399-403.
- Kaloo AN, Singh VK, Jagannath SB, Niiyama H, Hill SL, Vaughn CA, et al. Flexible transgastric peritoneoscopy: a novel approach to diagnostic and therapeutic interventions in the peritoneal cavity. *Gastrointest Endosc.* 2004;60:114-7.
- Rao GV, Reddy DN, Banerjee R. NOTES: human experience. *Gastrointest Endosc Clin North Am.* 2008;18:361-70.
- Palanivelu C, Rajan P, Rangarajan M, Parthasarathi R, Senthilnathan P, Prasad M. Transvaginal endoscopic appendectomy in humans: a unique approach to NOTES-world's first report. *Surg Endosc.* 2008;22:1343-7.
- Kelly HA. Treatment of ectopic pregnancy by vaginal puncture. *Bull Johns Hopkins Hosp.* 1896;7:208.
- Von Ott D. Die Beleuchtung der Bauchhöhle (Ventroskopie) als Methode bei Vaginaler Coeliotomie. *Abl Gynakol.* 1902;231:817-23.
- Christian J, Barrier BF, Schust D, Miedema B, Thaler K. Culdoscopy: a foundation for natural orifice surgery—past, present, and future. *J Am Coll Surg.* 2008;207:417-22.
- Burnett AF. Reinventing the culdoscope. *Surg Endosc.* 2000;14:685-8.
- Tsin DA, Colombero LT, Lambeck J, Manolas P. Minilaparoscopy-assisted natural orifice surgery. *JSL.* 2007;11:24-9.
- Delvaux G, Devroey P, De Waele, Willems G. Transvaginal removal of gallbladders with large stones after laparoscopic cholecystectomy. *Surg Laparosc Endosc.* 1993;3:307-9.
- Breda G, Silvestre P, Giunta A, Xausa D, Tamai A, Gherardi L. Laparoscopic nephrectomy with vaginal delivery of the intact kidney. *Eur Urol.* 1993;24:116-7.
- Zornig C, Emmermann A, von Waldenfels HA, Felixm\_ller C. Die Kolpotomie zur Präparatebergung in der laparoskopischen Chirurgie Colpotomy for removal of specimen in laparoscopic surgery. *Chirurg.* 1994;65:883-5.
- Vereczkei A, Illenyi L, Arany A, Szabo Z, Toth L, Horvath OP. Transvaginal extraction of the laparoscopically removed spleen. *Surg Endosc.* 2003;17:157.
- Gill IS, Cherullo EE, Meraney AM, Borsuk F, Murphy DP, Falcone T. Vaginal extraction of the intact specimen following laparoscopic radical nephrectomy. *J Urol.* 2002;167:238-41.
- Wilson JI, Dogiparthi KK, Hebblethwaite N, Clarke MD. Laparoscopic right hemicolectomy with posterior colpotomy for transvaginal specimen retrieval. *Colorectal Dis.* 2007;9:662.
- Tsin DA, Colombero LT, Mahmood D, Padouvas J, Manolas P. Operative culdolaparoscopy: a new approach combining operative culdoscopy and minilaparoscopy. *J Am Assoc Gynecol Laparosc.* 2001;8:438-41.
- Zorrón R, Filgueiras M, Maggioni LC, Pombo L, Lopes G, Lacerda A. NOTES transvaginal cholecystectomy: report of the first case. *Surg Innov.* 2007;14:278-83.
- Bessler M, Stevens PD, Milone L, Parikh M, Fowler D. Transvaginal laparoscopically assisted endoscopic cholecystectomy: a hybrid approach to natural orifice surgery. *Gastrointest Endosc.* 2007;66:1243-5.
- Marescaux J, Dallemagne B, Perretta S, Wattiez A, Mutter D, Coumaros D. Report of transluminal cholecystectomy in a human being. *Arch Surg.* 2007;142:823-6.
- Dolz C, Noguera JF, Martín A, Vilella A, Cuadrado A. Colectectomía transvaginal (NOTES) combinada con minilaparoscopia. *Rev Esp Enferm Dig.* 2007;99:698-702.
- Noguera JF, Dolz C, Cuadrado A, Olea JM, Vilella A. Transvaginal liver resection (NOTES) combined with minilaparoscopy. *Rev Esp Enferm Dig.* 2008;100:411-5.
- Nakajima K, Nishida T, Takahashi T, Souma Y, Hara J, Yamada T, et al. Partial gastrectomy using natural orifice transluminal endoscopic surgery (NOTES) for gastric submucosal tumors: early experience in humans. *Surg Endosc.* 2009;23:2650-5.
- Lacy AM, Delgado S, Rojas OA, Ibarzábal A, Fernández-Esparrach G, Taura P. Hybrid vaginal MA-NOS sleeve gastrectomy: technical note on the procedure in a patient. *Surg Endosc.* 2009;23:1130-7.
- Targarona EM, Gómez G, Rovira R, Pernas JC, Balagué C, Guarner-Argente C, et al. NOTES-assisted transvaginal splenectomy: the next step in the minimally invasive approach to the spleen. *Surgical Innovation.* 2009;16:218-22.
- De Sousa LH, de Sousa JA, de Sousa Filho LH, de Sousa MM, de Sousa VM, de Sousa AP, et al. Totally NOTES (T-NOTES) transvaginal cholecystectomy using two endoscopes: preliminary report. *Surg Endosc.* 2010;24:2444-52.
- Ramos AC, Murakami A, Galvão Neto M, Galvão MS, Silva AC, Canseco EG, et al. NOTES transvaginal videoassisted cholecystectomy: first series. *Endoscopy.* 2008;40:572-5.
- Bessler M, Gumbs AA, Milone L, Evanko JC, Stevens P, Fowler D. Pure natural orifice transluminal endoscopic surgery (NOTES) cholecystectomy. *Surg Endosc.* 2010;24:2316-7.
- Zornig C, Emmermann A, Waldenfels HA, Mofid H. Laparoscopic cholecystectomy without visible scar: combined transvaginal and transumbilical approach. *Endoscopy.* 2007;39:913-5.
- Castro R, Acosta LR, Dopico E, Robaina LE. MANOS: colecistectomías transvaginales. Reporte preliminar. *Cir Esp.* 2009;85:292-7.

38. Davila F, Tsin DA, Domínguez G, Dávila U, Jesús R, Gómez de Arteche A. Transvaginal cholecystectomy without abdominal ports. *JSLs*. 2009;13:213-6.
39. Federlein M, Borchert D, Muller V, Atas Y, Fritze F, Burghardt J, et al. Transvaginal video-assisted cholecystectomy in clinical practice. *Surg Endosc*. 2010;24:2444-52.
40. Lacy AM, Delgado S, Rojas OA, Almenara R, Blasi A, Llach J. MA-NOS radical sigmoidectomy: report of a transvaginal resection in the human. *Surg Endosc*. 2008;22:1717-23.
41. Castro R, Dopico E, Acosta LR. Minilaparoscopic-assisted transvaginal approach in benign liver lesions. *Rev Esp Enferm Dig*. 2010;102:357-64.
42. Targarona EM, Maldonado EM, Marzol JA, Marinello F. Natural orifice transluminal endoscopic surgery: the transvaginal route moving forward from cholecystectomy. *World J Gastrointest Surg*. 2010;2:179-86.
43. Bernhardt J, Gerber B, Schober HC, Kähler G, Ludwig K. NOTES—case report of a unidirectional flexible appendectomy. *Int J Colorectal Dis*. 2008;23:547-50.
44. Zorrón R, Palanivelu C, Neto M, Ramos A, Salinas G, Burghardt J, et al. International multicenter trial on clinical natural orifice surgery NOTES IMTN Study: preliminary results of 362 patients. *Surg Innov*. 2010;17:142-58.
45. Wagner M, Aronsky D, Tschudi J, Metzger A, Klaiber C. Laparoscopic stapler appendectomy. A prospective study of 267 consecutive cases. *Surg Endosc*. 1996;10:895-9.
46. Beldi G, Vorburger SA, Bruegger LE, Kocher T, Inderbitzin D, Candinas D. Analysis of stapling versus endoloops in appendiceal stump closure. *Br J Surg*. 2006;93:1390-3.
47. Castro R, Dopico E, Delgado JC, Zayas R, Robaina LE. La cirugía mínimamente invasiva en la apendicitis aguda. Nuestra experiencia en 2463 pacientes. Trabajo presentado en el X Congreso Cubano de Cirugía, 2008 Dic 2-5, Palacio de Convenciones de la Habana: Sociedad Cubana de Cirugía; 2008.
48. Champault A, Polliand C, Mendes da Costa P, Champault G. Laparoscopic appendectomies: retrospective study of 2074 cases. *Surg Laparosc Endosc Percutan Tech*. 2008;18:168-72.
49. Pearl JP, Marks JM, Ponsky JL. Hybrid surgery: combined laparoscopy and natural orifice surgery. *Gastrointest Endosc Clin N Am*. 2008;18:325-32.
50. Viñas X, Torres G, Feliu X, Macarulla E, Abad JM, Besora P, et al. Impacto de la cirugía laparoscópica en el manejo del dolor abdominal agudo en la mujer joven. ¿Indicación de apendicectomía selectiva? *Cir Esp*. 2004;75:331-4.
51. Watrelot A. Place of transvaginal fertiloscopy in the management of tubal factor disease. *Reprod Biomed Online*. 2007;15:389-95.
52. Noguera JF, Moreno C, Cuadrado A, Olea JM, Morales R, Vicens JC, et al. NOTES. Historia y situación actual de la cirugía endoscópica por orificios naturales en nuestro país. *Cir Esp*. 2010;8:222-7.
53. Gordts S, Campo R, Rombauts L, Brosens I. Transvaginal hydrolaparoscopy as an outpatient procedure for infertility investigation. *Hum Reprod*. 1998;13:99-103.
54. Tanaka M, Sagawa T, Hashimoto M, Mizumoto Y, Yoshimoto H, Yamazaki R, et al. Ultrasound-guided culdotomy for vaginal ovarian cystectomy using a renal balloon dilator catheter. *Ultrasound Obstet Gynecol*. 2008;31:342-5.
55. Tanaka M, Sagawa T, Hashimoto M, Mizumoto Y, Yoshimoto H, Yamazaki R, et al. The culdotomy four s two u procedure for transvaginal. access to the peritoneal cavity. *Endoscopy*. 2009;41:472-4.
56. Canes D, Lehman AC, Farritor SM, Oleynikov D, Desai MM. The future of NOTES instrumentation: flexible robotics and in vivo minirobots. *J Endourol*. 2009;23:787-92.
57. Sánchez-Margallo FM, Asencio Pascual JM, Tejonero Álvarez MC, Sánchez Hurtado MA, Pérez Duarte FJ, Usón Gargallo J, et al. Diseño del entrenamiento y la adquisición de habilidades técnicas en la colecistectomía transvaginal (NOTES). *Cir Esp*. 2009;85:307-13.
58. Olsina Kissler JJ, Balsells Valls J, Dot Bach J, Suboh Abadía MA, Armengol Bertoli J, Esteves M, Rosal Fontana M, et al. Cirugía endoscópica transluminal NOTES: resultados experimentales iniciales. *Cir Esp*. 2009;85:298-306.
59. Swain P, Sadaat V, Brenneman R, Ewers R. Force transmission at flexible endoscopy with conventional endoscopes and shape locking endoscope guide catheter. *Gastrointest Endosc*. 2004;59. Abstr M1709.
60. Mintz Y, Horgan S, Cullen J, Stuart D, Falor E, Talamini MA. NOTES: a review of the technical problems encountered and their solutions. *J Laparoendosc Adv Surg Tech*. 2008;18:583-7.
61. Kotzampassi K, Grosomanidis V, Eleftheriadis E. Improving triangulation in NOTES by triple access. *Hellenic J Surg*. 2010;82:95-9.
62. Thompson CC, Ryou M, Soper NJ, Hungess ES, Rothstein RI, Swanstrom LL. Evaluation of a manually driven, multitasking platform for complex endoluminal and natural orifice transluminal endoscopic surgery applications. *Gastrointest Endosc*. 2009;70:121-5.
63. Spaun GO, Zheng B, Martinec DV, Cassera MA, Dunst CM, Swanström LL. Bimanual coordination in natural orifice transluminal endoscopic surgery: comparing the conventional dualchannel endoscope, the R-Scope, and a novel direct-drive system. *Gastrointest Endosc*. 2009;69:39-45.
64. Marescaux J, Perretta S. NOTES: Un nuevo abordaje mínimamente invasivo. *Cir Esp*. 2009;85:265-7.