



Review Article

Benign Non-Parasitic Hepatic Cystic Tumours[☆]

José Manuel Ramia,* Roberto de La Plaza, Joan Figueras, Jorge García-Parreño

Unidad de Cirugía Hepatobiliopancreática, Servicio de Cirugía General y Aparato Digestivo, Hospital Universitario de Guadalajara, Guadalajara, Spain

ARTICLE INFO

Article history:

Received 9 February 2011

Accepted 3 May 2011

Available online 19 December 2011

Keywords:

Tumour

Benign

Liver

Cyst

Cystadenoma

Polycystosis

Review

Surgery

A B S T R A C T

Hepatic cystic tumours are a heterogeneous group of diseases with different aetiology and incidence, and with similar clinical signs and symptoms. They are classified as congenital, traumatic, parasitic, or neoplastic cysts. The congenital cystic tumours are the most prevalent, and include the simple cyst and polycystic hepatic disease. Other less common lesions are, hepatic cystadenoma, ciliated embryonic cyst, and a miscellaneous group. We have carried out a review of all benign non-parasitic hepatic cystic tumours, placing special emphasis on therapeutic strategies.

© 2011 AEC. Published by Elsevier España, S.L. All rights reserved.

Tumores hepáticos quísticos benignos no parasitarios

R E S U M E N

Los tumores quísticos hepáticos son un grupo heterogéneo de enfermedades con distinta etiología e incidencia, y con manifestaciones clínicas similares. Se clasifican en quistes congénitos, traumáticos, parasitarios o neoplásicos. Los tumores quísticos congénitos son los más prevalentes e incluyen al quiste simple y a la enfermedad poliquistica hepática. Otras lesiones infrecuentes son el cistoadenoma hepático, el quiste hepático ciliado embrionario, y un grupo miscelánea. Hemos efectuado una revisión de todas lesiones quísticas hepáticas benignas no parasitarias, haciendo hincapié en las estrategias terapéuticas.

© 2011 AEC. Publicado por Elsevier España, S.L. Todos los derechos reservados.

Palabras clave:

Tumor

Benigno

Hígado

Quiste

Cistoadenoma

Poliquistosis

Revisión

Cirugía

Hepatic cysts (HC) are a heterogeneous group of diseases with a different aetiology and prevalence, but are clinically similar.¹⁻⁴ They can be classified as congenital, traumatic,

parasitic and neoplastic.⁵⁻¹⁰ The congenital type is the most important one and includes simple cyst (SC) and polycystic liver disease (PLD).^{8,9,11-13} HC are diagnosed incidentally, as

[☆] Please, cite this article as: Ramia JM, et al. Tumores hepáticos quísticos benignos no parasitarios. Cir Esp. 2011;89:565-73.

* Corresponding author.

E-mail address: jose_ramia@hotmail.com (J.M. Ramia).

they are usually asymptomatic, benign and more frequent in women.^{2-4,6,14-17} Their incidence is unknown but it is estimated that 5% of the population have non-parasitic HC.^{7,8,15,17-22}

Simple Cyst

The SC is the most common liver injury, with a prevalence in the adult population of between 0.1% and 7%.^{5,6,9-12,20,22-31} It is filled with serous fluid and has no communication with the biliary tree.^{10,12,16,23,24} It is more common in women, with a ratio of 2:1 for asymptomatic and 9:1 for symptomatic SC.^{2,5,8,17,19,22,24,27,29,31} It is probably due to an aberrant bile duct losing communication with the biliary tree,^{1,5,8,10,12,14,18,22,24,27-30,32} and cases of spontaneous disappearance have been reported.³⁰

Macroscopically, it has a spherical or ovoid shape, unilocular and without septa. Its size ranges from a few millimetres to more than 20 cm, and 60% of patients have a single lesion.^{6,23,24} Unlike PLD, multiple SC occupy less than 50% of a patient's liver.^{6,17} Microscopically, the SC has a column monolayer epithelium, similar to the biliary one, that may become necrotic if the intracystic pressure is high.^{5,6,23,24,27,29,30} There is no surrounding stroma in small SC and only a thin layer of connective tissue in large ones.^{6,24}

SC is usually asymptomatic and diagnosed incidentally.^{9-12,17,22-25,28,29,31-33} When symptomatic (10%-15%), the most common symptom is abdominal pain.^{5,14,17,18,22,24,27,28,30,32} Other symptoms include nausea and vomiting, postprandial fullness, shoulder pain, dyspnoea and palpable abdominal tumour, etc.^{5,11,12,16-18,20,22,24,28,31,32} Analytical studies provide normal results unless there is compression of the biliary tree. Some SC present with high levels of intracystic CA19-9.^{9,18,34} SC complications occur in 5% of patients.^{11,20,23} The two most common complications are infection, often monomicrobial by *E. coli*, and bleeding.^{2,11,16,20,23,26,32} Other less common ones are as follows: traumatic or spontaneous rupture, torsion, compression of surrounding structures such as the inferior vena cava; portal vein, causing portal hypertension; the bile duct, producing cholestasis, cholangitis and jaundice; fistulisation to the

duodenum or biliary tree; and exceptionally, malignisation.^{2,7-9,11,16,20,22-24,26,28,31,32,35-41}

Intracystic haemorrhage usually occurs in elderly patients with large SC.^{13,33} The most common symptoms are rapid growth and abdominal pain.^{2,12,31,33} If bleeding is significant, it may lead to compressive thrombosis of the inferior vena cava.^{13,20,36} The intracystic haematic content may mimic a hepatic cystadenoma (HCy).^{13,33,38} Contrast ultrasound and magnetic resonance imaging (MRI) are useful for the diagnosis of intracystic haemorrhage.^{2,12,42} A bleeding SC must be treated surgically to prevent future complications,^{13,23} although percutaneous drainage, embolisation and observation, if it is not infected, have been used in patients with severe comorbidities.¹³

The most cost-effective imaging method for SC is abdominal ultrasound. The radiographic features are typical^{13,32,33}: a circular or oval anechoic lesion, non-septated, with posterior enhancement caused by dense echoes behind the SC due to intracystic fluid.^{5,11,23,24,42} A CT scan confirms the presence of avascular cystic lesions with water density without contrast enhancement (Fig. 1).¹¹ MRI is useful for the diagnosis and detection of intracystic complications: the SC is observed as a T2 homogeneous hyperintense lesion without contrast enhancement and low intensity on T1.^{9,11,23} Differential diagnosis arises with the hydatid cyst, especially in endemic areas, HCy and cystic metastases.^{1,10,14,18,24,43}

Treatment is needed only if there are complications, and periodic monitoring suffices for asymptomatic patients.^{1,5,12,14,15,17,22,24,25,27-29,31,43} The size of the cyst itself is not an indication for surgery, although large ones are usually symptomatic.^{2,3,14,18,31} Treatment options may be non-surgical (puncture aspiration with or without injection of sclerosing agents) or surgical,^{14,22,28-30,32,44} which are divided into conservative procedures: fenestration, and other techniques now practically abandoned (cystojejunostomy or marsupialisation); or radical (cystectomy or hepatic resection).^{3,12,17,25,26,29,32,44}

Aspiration under ultrasound/CT control may relieve the symptoms, but relapse is the norm. It makes sense to apply it only for patients at high surgical risk, as a diagnostic technique, in infected cysts or to find out whether the cyst causes the symptoms.^{1-3,5,6,11,12,15,17,18,22,23,28,29,32} The instillation of sclerosing agents (e.g., alcohol, minocycline,

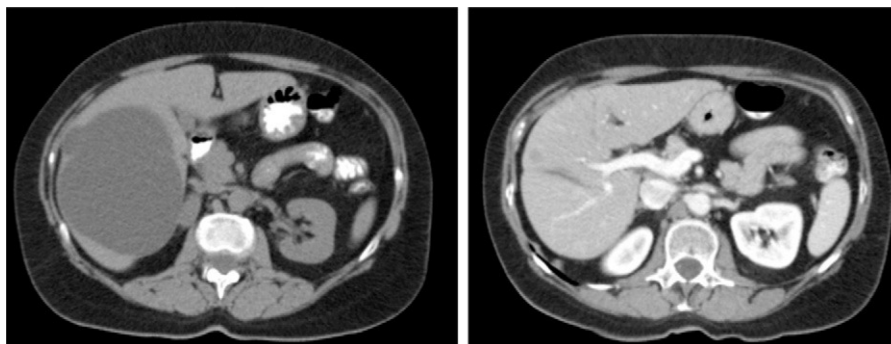


Fig. 1 – Abdominal CT: laparoscopic pre-fenestration and post-fenestration simple cyst.

monoethanolamine oleate or pantopaque) improves the results obtained with aspiration but has a high recurrence rate (20%–90%) and complications: pain during the procedure, alcohol poisoning, cholangitis or eosinophilia.^{2,9,11,12,14,16,18,22,28,29,31} The presence of a coagulation disorder, intracystic bleeding or SC communication with the biliary tree contraindicates the use of puncturing.^{1,11,12,14,16,29}

Fenestration is a technique that can be performed by laparotomy or laparoscopy.^{12,22,26,28,32,45,46} Its surgical risk is low, but long-term results are short-lived since late relapse is common. Laparoscopic fenestration was first described by Z'graggen in 1991 and has become the most commonly performed procedure in solitary symptomatic SC.^{3,6,17,18,22,27–29,43,47,48}

Laparoscopic fenestration (LF) starts with the puncture of the cyst for an analytical study (tumour markers, amylase, bilirubin and LDH), as well as a microbiological and cytological study of the intracystic fluid. The visible part of the SC is then dried with a hook, dissecting sealer, cutting stapler and is extracted into a sample bag for later histological analysis (Fig. 2).^{2,5,27,28,31,32} If there are multiple connected cysts, fenestration of the deep cysts can be performed via the external cysts.^{11,45} The windows made must be large enough to ensure permeability of the communication and prevent the SC from filling.^{6,11,15,28} A biopsy must be performed on any suspicious intracystic node.^{12,31} Fulguration of the unresected cystic epithelium has been performed with argon, electrocautery, and other similar tools.^{12,14,25,26,28,29,31,49} Currently, laparotomic fenestration is rarely indicated.³¹

The percentage of complications after LF of SC is between 0% and 18%.^{5,12,17,18,31} These include the following: abdominal hydatid cyst spread if there is an incorrect diagnosis, post-fenestration ascites, air embolism, pleural effusion, dyspnoea, biloma and haemorrhage.^{12,29,43,47} The rate of recurrence of symptoms is between 4% and 44%.^{5,14,15,17,18,26,28,29,31,43,48} Factors favouring recurrence after LF are: cysts centrally located or on the posterior right part, limited resection of the visible cyst wall, previously operated cysts, and the use of a hook instead of a dissecting sealer for resection.^{14,15,18,25,28} The very frequent radiological recurrence after LF is not always accompanied by the appearance of symptoms.¹⁷

Total cystectomy and hepatic resection are techniques performed occasionally.^{2,5,11,12,14,15,22,29,31,44} There is a publication on radiofrequency treatment of SC.⁵⁰

The treatment for patients with infected SC is percutaneous puncture and antibiotics to improve the symptoms and provide a reliable diagnosis, deciding the most appropriate treatment later.⁷

Polycystic Liver Disease

Polycystic liver disease (PLD) has a prevalence of between 0.05% and 0.6%. It consists of multiple hepatic cysts occupying more than 50% of the liver parenchyma. It is as an inherited autosomal dominant disease, and usually occurs in combination with polycystic kidney disease or cysts in other organs (pancreas, spleen, ovaries and lung, although rarely in the latter).^{1,2,6,11,31,34,45,46,51–64} One-third of patients with PLD never develop kidney cysts, and these patients have genetic alterations on chromosome 19p13.2-13.1 (PRKSCH) and 6q (SEC63). This is different to patients with hepatorenal polycystic disease, with alterations on chromosomes 4 and 16 (PKD1 and 2).^{52,55,60,61,65–72} Patients with only PLD have larger cysts but with fewer complications than patients with hepatorenal polycystic disease.^{52,66}

PLD is more common in women, who also tend to have more and larger cysts.^{46,60,64,66,73} Patients with PLD also have a higher incidence of intracranial aneurysms.^{11,31,51,62,64,71,72}

Liver injury in PLD can be microcystic, macrocystic or biliary hamartomas (von Meyenburg complexes) distributed evenly over the liver and peribiliary areas.^{52,58,61,69} The normal parenchyma shows fibrosis and vascular changes.⁶³ Cysts usually contain clear fluid and histologically are lined by cuboidal epithelium.^{58,61,69} The cysts grow in size, number and volume with age.⁶⁵

PLD cysts are usually asymptomatic.^{45,51,52,57,58,60,61,72} When symptoms occur, due to increased volume or compression of adjacent structures, they are similar to those of SC.^{31,46,52,54,55,58,60–65,67,72,74,75} Complications are more common in symptomatic patients: for example, cyst infection, rupture, torsion, intracystic bleeding, portal hypertension causing ascites and/or oesophageal varices, compression of the vena cava, biliary obstruction or cystocutaneous fistula.^{45,51,52,55,57,58,60,61,65,67,68,72,76} Cystic infection or rupture is more common in patients with a kidney transplant, possibly due to immunosuppression.⁶² Most symptomatic patients

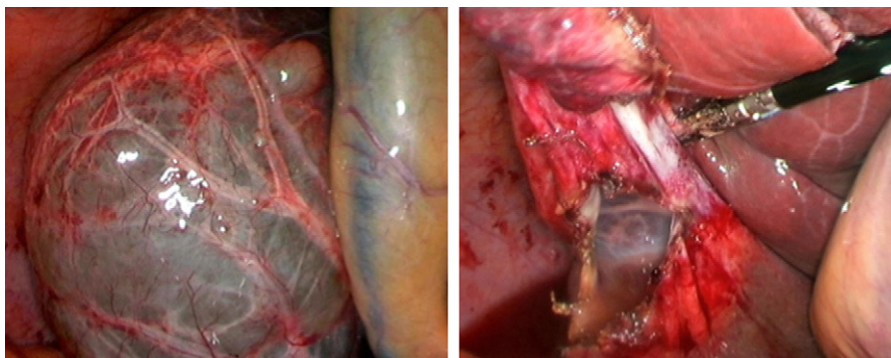


Fig. 2 – Simple liver cyst undergoing laparoscopic fenestration with Ligasure®.

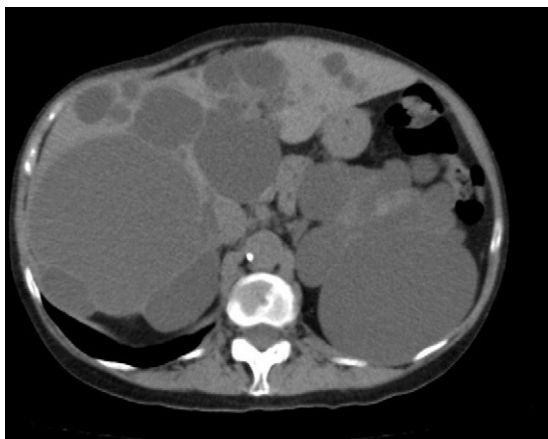

Fig. 3 – CT: polycystic liver disease.

(75%) have palpable hepatomegaly.^{54,61,62} Stigmata of liver disease and acute liver failure are rare.^{60,77}

Diagnosis of PLD can be made by ultrasound, helical CT and MRI.^{55,58,60,61,67,72} CT is better at defining the extent of the liver disease and the involvement of adjacent organs.³¹ It shows multiple hypoattenuating liver lesions of various sizes with well-defined margins and no contrast enhancement (Fig. 3).^{60,72} In MRI, the lesions are of low intensity on T1 and hyperintense on T2,⁶¹ and this is very useful for determining intracystic bleeding.⁶³ The liver biochemical profile is usually normal or slightly altered.^{2,52,55,60,61,64,72} The serum CA19-9 may be increased, and the intracystic one is usually very high, especially in large cysts.⁵⁹

Patients with asymptomatic PLD require no treatment.^{2,52,53,55,57,58,62,74} There is no consensus on how to treat symptomatic patients.^{2,27,31,45,53,55,57,60,61,63,65,72} The goal of treatment is to reduce the size of the cysts, without compromising liver function, and achieve the longest possible period without symptoms.⁵¹

The choice of treatment must be based on the size and extent of the cysts and the presence or not of complications. Gigot devised a classification that defines a therapeutic strategy and divides the cysts into the following: type I, a few large cysts between 7 and 10 cm; type II, multiple medium-sized cysts (5–7 cm); and type III, multiple medium and small cysts (less than 5 cm).^{26,31,51,72,78} Li and Schnellendorf proposed new classifications which have not been used as much.^{51,74}

Type I patients can opt for LF of the accessible dominant cyst(s) or puncture.¹ LF results in a reduction of 12.5% in cystic volume (range: 9.4%–24.7%) which produces a clinical improvement (less bloating and postprandial fullness), and a recurrence of 4.5%–16%.^{1,14,25,26,45,60,61,67,74,78} In some cases (e.g., infected cyst or high surgical risk), a percutaneous puncture can be performed to temporarily improve the symptoms.^{1,2,26,61,78} Its advantage is minimum morbidity and mortality, but the disadvantages are the high recurrence rate and low reduction in mass.^{46,53,58,61,67,72,79}

There are 2 procedures for type II patients: fenestration and liver resection, or a combination of both. Both have significant morbidity, and long-term palliation of the symptoms is not achieved.^{3,7,15}

Fenestration was classically performed by laparotomy by draining the internal cysts into the most superficial ones.^{45,51,61,72} Fenestration does not achieve the results expected due to the growth of other small or inaccessible cysts, and for not managing to collapse the liver easily due to its rigidity.^{11,31,45,46,61} In recent years there have been small series of LF in patients with PLD.^{26,31,45,60,67,78} Comparing both approaches, laparotomic fenestration results in a reduction in volume of 43%, a mean recurrence rate of 17% (11%–26%), a morbidity between 0% and 56% and a mortality between 0% and 11%.^{6,25,26,72} LF obtains an initial improvement in symptoms for over 70% of patients, recurrence is between 0% and 54%,^{26,31,45,60,61} mortality is practically nil and morbidity between 0% and 67% (including ascites, bleeding, biliary fistula and pleural effusion).^{26,45,48,67,72} The technical problems of LF are mistaking a cyst for a large venous trunk, leading to cataclysmic bleeding; and difficult access to the intrahepatic cysts or posterior segments.^{25,45,51,53,61,75} The published results do not give a clear preference for laparotomy or laparoscopic fenestration.⁵¹

Hepatic resection is occasionally used, but is the method of choice when the patient has portal hypertension and/or cysts situated in an anatomical region of the liver.

The combination of resection and fenestration of peripheral cysts and communication with the innermost ones is the technique with the best results, with a reduction in volume of 75% and a recurrence rate of 15%.^{1,26,46,51,53,62,63,67,69} The advantages are: reduction in volume, complex cyst elimination, and regeneration of healthy liver parts.⁶³ Morbidity ranges between 20% and 100%, including vascular lesions, biliary lesions, postoperative ascites, which is very difficult to resolve as it exceeds the peritoneal absorption capacity (900 ml/day), insufficient postoperative liver volume and kinking of the liver.^{45,46,51,61–63,67,72,74} Mortality is between 0% and 11%.^{46,51,53,63,67,72,74} The main disadvantages of this technique are high morbidity and mortality; it is not applicable to patients with a severe preoperative hepatorenal situation and, when it fails, there is little choice for the patient other than a liver transplant. It is always recommended to perform a cholecystectomy with cholangiography to prevent biliary leakage.^{58,63} Fenestration of the cysts near the hepatic veins and vena cava is important to prevent future compression complications.^{63,74}

Type III can be treated by a combination of fenestration and/or resection or liver transplant.^{1,26,63,74} If the PLD-affected areas are close and leave enough viable parenchyma, resection with fenestration is feasible. However, when it is very diffuse, or the remaining volume is less than 30%, or there are histological changes in the liver parenchyma or there is renal failure, a transplant is indicated before any complications appear.^{31,63,64,68,78} In 1988, Kwok performed the first PLD-induced liver transplant. Since then there have been 600 cases in Europe and PLD consists of 0.5% of indications for liver transplantation.^{51,56,64,68,73,77,80,81} The most common indication is the lethal exhaustion syndrome (cachexia, fatigue and pain).⁷² Women comprise 90% of transplant recipients, hepatorenal affection is 90%, but only 53% are kidney transplants.^{56,63,64,68,73,74,77,80–83} Morbidity is 85% and perioperative mortality is 12.5%, due mainly to the poor pre-operative

condition. Survival at 5 years is 85%.^{56,63,64,67,73,74,77,80-83} Palliation of the symptoms is excellent.^{56,63,64,67,73,74,77,80-83}

These transplants are often complex due to previous surgery and the large size of the liver.^{63,67,77} Traditionally, it was recommended to start surgery via the hepatic hilum, use the veno-venous bypass and the classical technique with resection of the inferior vena cava,⁶⁵ but the piggyback option is feasible in a large percentage of patients.^{63,81}

There are several arguments against performing a liver transplant in PLD: it is a benign disease, there is usually hepatocellular failure, indefinite immunosuppressive therapy, surgery with associated morbidity and mortality and lack of donations.^{1,63,64,77,81} The arguments in favour are: good results and improved quality of life after transplantation.^{61,64,67} The right time to perform liver transplantation and the convenience of a hepatorenal transplant is a complex decision.^{63,64,67,77}

Other therapeutic measures include treatment with octreotide and analogues but these have not been successful.^{34,74} A multicentre study of lanreotide obtained a reduction in cystic volume of 2.9%.⁶⁵ Placing a stent in the vena cava in patients with intractable ascites caused by hepatomegaly may be effective.⁵⁴

Hepatobiliary Cystadenomas

Hepatobiliary cystadenomas (HCy) are rare liver tumours,^{6,84-93} comprising 5% of total hepatic cysts.^{4,84,85,87-97} Middle-aged women account for 85% of them.^{3,4,84-87,89-94,96,97} Its histogenesis is unknown.^{90,92-94,97}

In 1985, 2 subtypes of HCy were defined, according to the presence or not of ovarian-like mesenchymal stroma.^{4,87,88,90,91,98} The HCy without stroma are more common in men, and become malignant more often.^{87,94,96,99} There is a sub-type of HCy without stroma with acidophilic cells that only occurs in men and is considered a semi-malignant variant.⁹¹ It is not known if the malignant variant (cystadenocarcinoma) is an evolution from a HCy or an initially malignant tumour.^{87,90,91} The rate of malignancy may reach 30%.⁸⁴

HCy are multiloculated, well-defined, solitary lesions, usually with internal septations, papillary projections or nodules on the wall of the HCy or septa. At the microscopic level, they have the following layers: simple cuboidal or columnar monolayer epithelium, mesenchymal stroma (absent in the variant without stroma) and an outer layer of dense connective tissue.^{4,6,84,86,87,90-94,96-98,100,101} The intracystic fluid may be cloudy or clear with a gelatinous or mucinous appearance.^{87,94} HCy is variable in size (1.5-30 cm).^{85,87,88,93,95} There may occasionally be communication between the HCy and the biliary tree. It is associated with mucinous cystic tumours of the pancreas.^{86,90,96}

Most HCy are asymptomatic and are found incidentally.^{85,87,90-94} The symptoms it causes are similar to those of SC.^{4,21,85-91,93,94,97,100} Possible complications include intracystic haemorrhage, compression or obstruction of the bile duct, ascites, bacterial overinfection, rupture, recurrence and malignisation.^{85,89-91,94,97}

Analytical studies are usually normal, with elevated liver function results if there is compression of the biliary tree.^{21,93,94,96} Markers in the intracystic fluid are high, especially for CA19-9.^{84,93,94,102} The presence of CA19-9 in the epithelium of HCy has been demonstrated immunohistochemically.^{4,13,86-88,91,92,97,102,103} The ultrasound image shows an ovoid anechoic cystic mass with multiple hyperechoic internal septa and papillary projections in the septa or cyst wall.^{4,86,87,91,92} The CT image shows a multilobulated, well-defined, thick-walled cystic mass of low density, and usually has internal septa, mural nodules, and/or papillary projections with contrast enhancement.^{4,6,87,91,92,97} MRI is useful for evaluating the intracystic content features.⁹⁴ Puncturing is not recommended due to the low diagnostic sensitivity and risk of spread.^{4,13,91} Correct preoperative diagnosis is between 30% and 95%.⁸⁴ The presence of a significant solid component (nodular solid masses or marked parietal thickening), intracystic haemorrhage, wall calcifications, and the combination of nodules and septa are suggestive of malignancy.^{87,91,95-97}

HCy treatment is complete surgical resection, as it is a potentially malignant lesion, which commonly relapses after partial surgery due to the inability to preoperatively distinguish between HCy and cystadenocarcinoma.^{3,4,6,10,21,84-86,88-90,94,96,97,99,100} The decision to perform complete enucleation or anatomic resection depends on the location of the HCy.^{4,89,91,92,94,99} HCy with mesenchymal stroma is more easily enucleated.⁹¹

Patients diagnosed preoperatively for SC who undergo a LF with a final diagnosis of HCy must be operated on for complete excision.^{91,93}

Ciliated Hepatic Foregut Cyst

Ciliated hepatic foregut cyst (CHFC) is an uncommon liver cystic lesion, with only 100 cases being published.¹⁰⁴⁻¹⁰⁸ It is postulated that CHFC derives from intrahepatic embryonic remnants that differentiate towards respiratory tissue rather than biliary.^{6,105-107,109}

It is usually benign, solitary, single, subcapsular and unilocular, and is often located in segment IV. It is of variable size, but usually under 4 cm.¹⁰⁴⁻¹¹¹ Its content is viscous or mucoid.^{104,106,108,109} The mean age of onset is 48 years with a slight predominance towards men.^{104,105,110} Histologically, there are 4 layers: mucin-producing pseudostratified ciliated columnar epithelium, subepithelial connective tissue, stroma, and fibrous capsule.^{6,105,107-109,111} Three cases of squamous cell carcinoma in CHFC that developed in previous squamous metaplasia foci have been described, suggesting a progression from dysplasia to carcinoma.^{104,105,111-113}

Its diagnosis is usually incidental because they are asymptomatic in 80% of cases.^{104-106,108,110} The most typical symptom is abdominal pain, although it can also cause jaundice or portal hypertension.^{104-108,111,112}

On the ultrasound image, it appears as an anechoic or hypoechoic, well-defined, round lesion, with a visible intracystic echogenic mass.^{104,110} The CT image shows hypodense lesions without contrast enhancement. On MRI, the T2 hyperintensity is characteristic, with a variable T1

intensity depending on the content.^{104,106-109,111} Puncturing has a positive predictive value of 76%.¹⁰⁴

The traditional treatment was puncturing with aspiration or injection of sclerosing agents, with surgical treatment recommended only in symptomatic lesions with uncertain diagnosis.^{106,107} Publication of 3 cases of malignisation (3% of the total) raises doubts about the most appropriate treatment.^{106,111,112} CHFC must always be resected if larger than 4 cm (the 3 patients with large cysts had malignant CHFC), symptomatic, with progressive growth or when there is a mass on the cyst wall.^{104,106,111} Complete laparoscopic resection of CHFC is an interesting option.¹¹¹

Other Rare Cystic Lesions

Other rare cystic lesions have been described:

- Intrahepatic pancreatic pseudocyst: only 27 cases were described up to 2006. They are usually located in the left hepatic lobe, are usually asymptomatic, and diagnosis is incidental. Diagnostic confirmation comes after puncture when there is a fluid rich in amylase.¹¹⁴ Treatment ranges from monitoring and percutaneous drainage to surgery¹¹⁴;
- Post-traumatic cysts: the conservative management of liver injuries has increased the number of post-traumatic cysts. Only those symptomatic ones or those with diagnostic uncertainty should be operated on^{1,5,7,115};
- Hamartomas: also called von Meyenburg complexes. They are caused by a failure of involution of the embryonic bile ducts.¹¹⁶ They are multiple lesions of 0.1-1.5 cm and are not communicated with the bile duct.¹¹⁶ Autopsy incidence varies between 0% and 2.8%. They are usually incidental findings, as they are usually asymptomatic but may exceptionally cause microabscesses or degenerate into cholangiocarcinoma.^{116,117} A CT image may be confused with multiple liver metastases but MRI provides an accurate diagnosis¹¹⁶;
- Epidermoid cyst;
- Lymphangiomas;
- Biloma: These are caused by spontaneous, traumatic or iatrogenic rupture of the biliary system;
- Biliary intraductal papillary mucinous tumour: There are 2 types, cystic and non-cystic.¹⁰¹

Conflicts of Interest

The authors have no conflicts of interest to declare.

REFERENCES

1. Mazza OM, Fernandez DL, Pekolj J, Pfaffen G, Sanchez R, Molmenti E, et al. Management of non parasitic hepatic cysts. *J Am Coll Surg.* 2009;209:733-9.
2. Erdogan D, Van Delden OM, Rauws EJ, Busch ORC, Lameris JS, Gouma DJ, et al. Results of percutaneous sclerotherapy and surgical treatment in patients with symptomatic simple liver cysts and polycystic liver disease. *World J Gastroenterol.* 2007;13:3095-100.
3. Regev A, Reddy KR, Berho M, Sleeman D, Levi JU, Livingstone AS, et al. Large cystic lesions of the liver in adults: a 15-year experience in a tertiary center. *J Am Coll Surg.* 2001;193:36-45.
4. Marcos R, Rodríguez A, Martín J, Ramos P, Galván M, Gutiérrez A, et al. Cistoadenomas hepatobiliares. *Cir Esp.* 2006;79:375-8.
5. Cowles RA, Mulholland MW. Solitary hepatic cysts. *J Am Coll Surg.* 2000;191:311-21.
6. Hansman MF, Ryan JAJ, Holmes JH, Hogan S, Lee FT, Kramer D, et al. Management and long term follow-up of hepatic cysts. *Am J Surg.* 2001;181:404-10.
7. Lin CC, Lin SC, Ko WC, Chang KM, Shih SC. Adenocarcinoma and infection in a solitary hepatic cyst. *World J Gastroenterol.* 2005;11:1881-3.
8. Poggi G, Gatti C, Delmonte A, Teragni C, Bernardo G. Spontaneous rupture of non-parasitic hepatic cyst. *Int J Clin Pract.* 2006;60:99-103.
9. Miyamoto M, Oka M, Izumiya T, Nagaoka T, Ishihara Y, Udea K, et al. Non parasitic cyst giant hepatic cyst causing obstructive jaundice was successfully treated with monoethanolamine oleate. *Intern Med.* 2006;45:621-5.
10. Frider B, Alvarez J, Chiappeta L, Amante M. Non parasitic symple liver cyst: always a benign entity? Unusual presentation of a cystadenoma. *Dig Dis Sci.* 2005;50:317-9.
11. Martin IJ, McKinley AJ, Currie EJ, Holmes P, Garden OJ. Tailoring the management of nonparasitic liver cysts. *Ann Surg.* 1998;228:167-72.
12. Klingler PJ, Gadenstatter M, Schmid T, Bodner E, Schwelberger HG. Treatment of hepatic cysts in the era of laparoscopic surgery. *Br J Surg.* 1997;84:438-44.
13. Zhang YL, Yuan L, Shen F, Wang Y. Hemorrhagic hepatic cysts mimicking biliary cystadenoma. *World J Gastroenterol.* 2009;28:4601-3.
14. Garcea G, Pattenden CJ, Stephenson J, Dennison AR, Berry DP. Nine-year single center experience with nonparasitic liver cysts: diagnosis and management. *Dig Dis Sci.* 2007;52:185-91.
15. Petri A, Hohn J, Makula E, Kokai EL, Savanya GK, Boros M, et al. Experience with different methods of treatment of nonparasitic liver cysts. *Langenbecks Arch Surg.* 2002;387:229-33.
16. Van Sonnenberg E, Wroblecka JT, D'Agostino HB, Mathieson JR, Casola G, O'Laoide R, et al. Symptomatic hepatic cysts: percutaneous drainage and sclerosis. *Radiology.* 1994;190:387-92.
17. Loehe F, Globke B, Marnoto R, Bruns CJ, Graeb C, Winter H, et al. Long term results alter surgical treatment of nonparasitic hepatic cysts. *Am J Surg.* 2010;200:23-31.
18. Treckmann JW, Paul A, Sgourakis G, Heuer M, Wandelt M, Sotiropoulos GC. Surgical treatment of nonparasitic cysts of the liver: open versus laparoscopic treatment. *Am J Surg.* 2010;199:776-81.
19. Tabrizian P, Midulla PS. Laparoscopic excision of a large hepatic cyst. *JLS.* 2010;14(April-June (2)):272-4.
20. Buyse S, Asselah T, Vilgrain V, Parais V, Sauvanet A, Consigny Y, et al. Acute pulmonary embolism: a rare complication of a large non parasitic hepatic cyst. *Eur J Gastroenterol Hepatol.* 2004;16:1241-4.
21. Thomas KT, Welch D, Trueblood A, Sulur P, Wise P, Gorden DL, et al. Effective treatment of biliary cystadenoma. *Ann Surg.* 2005;241:769-73.
22. Pitale A, Bohra AK, Diamond T. Management of symptomatic liver cysts. *Ulster Med J.* 2002;71:106-10.

1. Mazza OM, Fernandez DL, Pekolj J, Pfaffen G, Sanchez R, Molmenti E, et al. Management of non parasitic hepatic cysts. *J Am Coll Surg.* 2009;209:733-9.
2. Erdogan D, Van Delden OM, Rauws EJ, Busch ORC, Lameris JS, Gouma DJ, et al. Results of percutaneous sclerotherapy and surgical treatment in patients with symptomatic

23. Pons F, Llovet JM. Actitud a seguir ante una lesión hepática focal. *Rev Esp Enferm Dig.* 2004;96:567-77.
24. Farges O, Bismuth H. Fenestration in the management of polycystic liver disease. *World J Surg.* 1995;19:25-30.
25. Bai XL, Liang TB, Yu J, Wang WL, Shen Y, Zhang M, et al. Long term results of laparoscopic fenestration for patients with congenital liver cysts. *Hepatobiliary Pancreat Dis Int.* 2007;6:600-3.
26. Gigot JF, Legrand M, Hubens G, Canniere L, Wibin E, Deweer F, et al. Laparoscopic treatment of nonparasitic liver cysts: adequate selection of patients and surgical technique. *World J Surg.* 1996;556-61.
27. Palanivelu C, Rangarajan M, Senthilkumar R, Mdankumar MV. Laparoscopic management of symptomatic multiple hepatic cysts: a combination of deroofting and radical excision. *JLS.* 2007;11:466-9.
28. Gambin TC, Holloway SE, Heckman JT, Geller DA. Laparoscopic resection of benign hepatic cysts: a new standard. *J Am Coll Surg.* 2008;207:731-6.
29. Tocchi A, Mazzoni G, Costa G, Cassini D, Bettelli E, Agostini N, et al. Symptomatic nonparasitic hepatic cysts. *Arch Surg.* 2002;137:154-8.
30. Yoshida H, Onda M, Tajiri T, Mamada Y, Taniai N, Uchida E, et al. Spontaneous disappearance of a hepatic cyst. *J Nippon Med Sch.* 2001;68:58-60.
31. Nagorney DM. Surgical management of cystic disease of the liver. In: Saunders WB, editor. *Surgery of the liver and biliary tract.* 4th ed. L Blumgart; 2007; p. 1261-76.
32. Krakenbuhl L, Baer HU, Renzulli P, Žraggen K, Frei E, Buchler M. Laparoscopic management of nonparasitic symptom-producing solitary hepatic cysts. *J Am Coll Surg.* 1996;183:493-8.
33. Kitajima Y, Okayama Y, Hirai M, Hayashi K, Imai H, Okamoto T, et al. Intracystic hemorrhage of a simple liver cyst mimicking a biliary cystadenocarcinoma. *J Gastroenterol.* 2003;38:190-3.
34. Van Keipema L, Drenth JP. Effect of octreotide on polycystic liver volumen. *Liver Int.* 2009;633-4.
35. Salemis NS, Georgoulis E, Gourgiotis S, Tsohataridis E. Spontaneous rupture of a giant non parasitic hepatic cyst presenting as an acute abdomen. *Ann Hepatol.* 2007;6:190-3.
36. Leung TK, Lee CM, Chen HC. Fatal thrombotic complications of hepatic cystic compression of the inferior vena: a case report. *World J Gastroenterol.* 2005;11:1728-9.
37. Macho O, Gomez J, Nuñez A, Narvaiza L, Albeniz L. Giant simple hepatic cyst as dyspnea symptoma in a 93 year-old patient. *An Med Interna.* 2007;24:135-7.
38. Takahashi G, Yoshida H, Mamada Y, Taniai N, Bando K, Tajiri T. Intracystic hemorrhage of a large simple hepatic cyst. *J Nippon Med Sch.* 2008;75:302-5.
39. Hsieh CB, Chen CJ, Yu JC, Chang TM, Gao HW. Primary squamous cell carcinoma of the liver arising from a complex liver cyst: report of a case. *Surg Today.* 2005;35:328-31.
40. Alfonso R, Melo F, Ballester JM, Caro F. Sarcoma pleomórfico hepático sobre quiste hepático no parasitario. *Cir Esp.* 2009;86:386-7.
41. Kim HS, Kim GY, Lim SJ, Lee SM, Kim YW. Undifferentiated pleomorphic sarcoma of the liver presenting as a unilocular cyst. *Hepatobiliary Pancreat Dis Int.* 2009;8:541-3.
42. Naganuma H, Funaoka M, Fujimori S, Ishida H, Komatsuda T, Yamada M, et al. Hepatic cyst with intracystic bleeding: contrast-enhanced sonographic findings. *J Med Ultrason.* 2006;33:105-7.
43. Giuliani F, D'Acapito F, Vellone M, Giovannini I, Nuzzo G. Risk of laparoscopic fenestration of liver cysts. *Surg Endosc.* 2003;17:1735-8.
44. Madariaga JR, Iwatsuki S, Starzl T, Todo S, Selby R, Zetti G. Hepatic resection for cystic lesions of the liver. *Ann Surg.* 1993;218:610-4.
45. Konstadoulakis M, Gomatos IP, Albanopoulos K, Alexakis N, Leandros E. Laparoscopic fenestration for the treatment of patients with sever adult polycystic liver disease. *Am J Surg.* 2003;189:71-5.
46. Yang GS, Li QG, Lu JH, Yang N, Zhang HB, Zhou XP. Combined hepatic resection with fenestration for highly symptomatic polycystic liver disease: a report on seven patients. *World J Gastroenterol.* 2004;10:2598-601.
47. Gagner M, Rogula T, Selzer D. Laparoscopic liver resection: benefits and controversies. *Surg Clin North Am.* 2004; 84:451-62.
48. Fiamingo P, Tedeschi U, Veroux M, Cillo U, Brolese A, Da Rold A, et al. Laparoscopic treatment of simple hepatic cysts and polycystic liver disease. *Surg Endosc.* 2003;17:623-6.
49. Aoki T, Kato T, Yasuda D, Shimizu Y, Murai N, Sato A, et al. Cyst wall resection and ablation by hand-assisted laparoscopic surgery combined with argon plasma coagulator for huge hepatic cysts. *Int Surg.* 2007;92:361-6.
50. Du XL, Ma QJ, Wu T, Lu JG, Bao GQ, Chu YK. Treatment of hepatic cysts by B-ultrasound-guided radiofrequency ablation. *Hepatobiliary Pancreat Dis Int.* 2007;6:330-2.
51. Russel RT, Pinson CW. Surgical Management of polycystic liver disease. *World J Gastroenterol.* 2007;13:5052-9.
52. Bistriz L, Tamboli C, Bigam D, Bain VG. Polycystic liver disease: experience at a teaching hospital. *Am J Gastroenterol.* 2005;100:2212-27.
53. Li TJ, Zhang HB, Lu JH, Zhao J, Yang N, Yang GS. Treatment of polycystic liver disease with resection-fenestration and a new classification. *World J Gastroenterol.* 2008;14: 5066-72.
54. Grams J, Teh SH, Torres VE, Andrews JC, Nagorney DM. Inferior vena cava stenting: a safe and effective treatment for intractable ascites in patients with polycystic liver disease. *J Gastrointest Surg.* 2007;11:985-90.
55. Varona JF, Usandizaga I, Perez Maestu R, Marcos J, Lozano F. Varón de 77 años con ictericia y prurito. *Rev Clin Esp.* 2006;206:197-8.
56. Lang H, Woellwarth JV, Oldhafer KJ, Behrend M, Schlitt HJ, Nashan B, et al. Liver transplantation in patients with polycystic liver disease. *Transplant Proc.* 1997;29: 2832-3.
57. Chavez RE, Jamieson NV. Poliquistosis hepática. In: Berenguer J, Parrilla P, editors. *Trasplante hepático.* 1st ed. Editorial Elba; 1999; p. 88-9.
58. Vall Llovera J, Bosch A, Gil E, Pons L, Barba S, Palau M, et al. Poliquistosis hepática del adulto abscesificada. *Cir Esp.* 2002;72:113-5.
59. Waanders E, Van Keimpema L, Brouwer JT, Van Oijen MGH, Aerts R, Sweep FGJ, et al. CA19-9 is extremely elevated in polycystic liver disease. *Liver Int.* 2009;1389-95.
60. Barahona J, Camacho J, Cerda E, Hernández J, Yamamoto JK, Torre A, et al. Factors that influence outcome in non-invasive and invasive treatment in polycystic liver disease patients. *World J Gastroenterol.* 2008;14:3195-200.
61. Morgan DE, Lockhart ME, Canon CL, Holcombe MP, Bynon JS. Polycystic liver disease: multimodality imaging for complications and transplant evaluation. *Radiographics.* 2006;26:1655-68.
62. Parks RW, Garden OJ. Benign liver lesions. In: Garden OJ, editor. *Hepatobiliary and pancreatic surgery.* 4th ed. WB Saunders; 2010; p. 75-105.
63. Aussilhou B, Doufle G, Hubert C, Francoz C, Paugam C, Paradis V, et al. Extended liver resection for polycystic liver disease can challenge liver transplantation. *Ann Surg.* 2010;252:735-43.

64. Pirenne J, Aerts R, Yoong K, Gunson B, Koshiha T, Fourneau I, et al. Liver transplantation for polycystic liver disease. *Liver Transpl.* 2001;7:238-45.
65. Van Keimpema L, Nevens F, Vanslembrouck R, Van Oijen MGH, Hoffmann AL, Dekker HM, et al. Lanreotide reduces the volumen of polycystic liver: a randomized double-blind, placebo-controlled trial. *Gastroenterology.* 2009;137:1661-8.
66. Hoevenaren IA, Wester R, Schrier RW, McFann K, Doctor RB, Drenth JP, et al. Polycystic liver: clinical characteristics of patients with isolated polycystic liver disease compared with patients with polycystic liver and autosomal dominant polycystic kidney disease. *Liver Int.* 2008;28:264-70.
67. Van Keimpema L, Hockerstedt K. Treatment of polycystic liver disease. *Br J Surg.* 2007;96:1379-80.
68. Swenson K, Seu P, Kinkhabwala M, Maggard M, Martin P, Goss J, et al. Liver Transplantation for adult polycystic liver disease. *Hepatology.* 1998;28:412-5.
69. Jones RS. Surgical management of non-parasitic liver cysts. In: Blumgart L, editor. *Surgery of the liver and biliary tract.* 4th ed. WB Saunders; 2007; p. 1211-7.
70. Iglesias DM, Palmitano JA, Arizurieta E, Kornblihtt AR, Herrera M, Bernath V, et al. Isolated polycystic liver disease not linked to polycystic kidney disease 1 and 2. *Dig Dis Sci.* 1999;44:385-8.
71. Reynolds DM, Falk CT, Li A, King BF, Kamath PS, Huston IIIrd J, et al. Identification of a locus for autosomal dominant polycystic liver disease on chromosome 19 p 13.2-13.1. *Am J Hum Genet.* 2000;1598-604.
72. Arnold HL, Harrison SA. New advances in evaluation and management of patients with polycystic liver disease. *Am J Gastroenterol.* 2005;100:2569-82.
73. Gustafsson BI, Friman S, Mjornstedt L, Olausson M, Backman L. Liver transplantation for polycystic liver disease: indications and outcome. *Transplant Proc.* 2003;35:813-4.
74. Schnelldorfer T, Torres VE, Zakaria S, Rosen CE, Nagorney DM. Polycystic liver disease. A critical appraisal of hepatic resection, cyst fenestration and liver transplantation. *Ann Surg.* 2009;250:112-8.
75. Van Keimpema L, Ruurda JP, Ernst MF, Van Geffen HJAA, Drenth JPH. Laparoscopic fenestration of liver cysts in polycystic liver disease results in a median volumen reduction of 12.5%. *J Gastrointest Surg.* 2008;12:477-82.
76. Di Carlo I, Di Stefano A, Pulvirenti E, Toro A. Laparoscopic excision of a case of percutaneous cystohepatic fistula in a patient affected by polycystic disease of the liver: point of technique. *Surg Laparosc Endosc Percutan Tech.* 2008;18:514-5.
77. Starzl T, Reyes J, Tzakis A, Miele L, Todo S, Gordon R. Liver Transplantation for polycystic liver disease. *Arch Surg.* 1990;125:575-7.
78. Gigot JF, Jadoul P, Que F, Van Beers BE, Etienne J, Horsmans Y, et al. Adult polycystic liver disease: is fenestration the most adequate operation for long term management? *Ann Surg.* 1997;225:286-94.
79. Nakaoka R, Das K, Kudo M, Chung H, Innoue T. Percutaneous aspiration and ethanolamine oleate sclerotherapy for sustained resolution of symptomatic polycystic liver disease: an initial experience. *AJR.* 2009;193:1540-5.
80. Kwok MK, Lewin KJ. Massive hepatomegaly in adult polycystic liver disease. *Am J Surg Pathol.* 1998;12:321-4.
81. Ramia JM, San Juan F, Orbis JF, Moya A, López-Andújar R, De Juan M, et al. Tratamiento de la poliquistosis hepática mediante trasplante hepático. *Cir Esp.* 2004;76:358-62.
82. Jeyarajah DR, Gonwa TA, Testa G, Abbasoglu O, Goldstein R, Husberg BS, et al. Liver and kidney transplantation for polycystic disease. *Transplantation.* 1998;66:529-31.
83. Koyama I, Fuchinoue S, Urashima Y, Kato Y, Tsuji K, Kawase T, et al. Living related liver transplantation for polycystic liver disease. *Transpl Int.* 2002;15:578-80.
84. Teoh AYW, Ng SSM, Lee KF, Lai PBS. Biliary cystadenoma and other complicated cystic lesions of the liver: diagnostic and therapeutic challenges. *World J Surg.* 2006;30:1560-6.
85. Manouras A, Markogiannakis H, Lagoudianakis E, Katergiannakis V. Biliary cystadenoma with mesenchymal stroma: report of a case and review of the literature. *World J Gastroenterol.* 2006;12:6062-9.
86. Yu FC, Chen JH, Yang KC, Wu CC, Chou YY. Hepatobiliary cystadenoma: a report of two cases. *J Gastrointest Liver Dis.* 2008;17:203-6.
87. Fukunaga N, Ishikawa M, Ishikura H, Ichimori T, Kimura S, Sakata A, et al. Hepatobiliary cystadenoma exhibiting morphologic changes from simple hepatic cyst shown by 11-year follow up imagings. *World J Surg Oncol.* 2008;6:129-35.
88. Ramirez C, Ruiz M, Santoyo J, Iaria M, Suarez M, Jimenez M, et al. Cistoadenoma biliar con estroma mesenquimal "ovarian like" y niveles elevados de CA19.9. *Rev Esp Enferm Dig.* 2004;96:588-9.
89. Den Hoed PT, Lameris H, Klooswijk B, Ijzermans JNM. Biliary cystadenoma: an uncommon cause of cholestatic jaundice. *Eur J Surg Oncol.* 1999;25:335-6.
90. Catinis GE, Frey DJ, Sinner JW, Balart LA. Hepatic cystadenoma: an unusual presentation. *Am J Gastroenterol.* 1998;93:827-9.
91. Dixon E, Sutherland FR, Mitchell P, McKinnon G, Nayak V. Cystadenomas of the liver: a spectrum disease. *Can J Surg.* 2001;44:371-5.
92. Beuran M, Dan Venter M, Dumitru L. Large mucinous biliary cystadenoma with "ovarian-like" stroma: a case report. *World J Gastroenterol.* 2006;12:3779-81.
93. Fiamingo P, Veroux M, Cillo U, Basso S, Buffone A, D'Amico DF. Incidental cystadenoma after laparoscopic treatment of hepatic cysts: which strategy. *Surg Laparosc Endosc Percutan Tech.* 2004;14:282-4.
94. Vogt DP, Henderson JM, Chmielewski E. Cystadenoma and cystadenocarcinoma of the liver: a single center experience. *J Am Coll Surg.* 2005;200:727-33.
95. Pojchamarnwiputh S, Na Chiangmai W, Chotirosniramit A, Lertprasertsuke N. Computed tomography of biliary cystadenoma and biliary cystadenocarcinoma. *Singapore Med J.* 2008;49:392-6.
96. Buetow PC, Buck JL, Pantongrag-Brown L, Ros PR, Devaney K, Goodman Z, et al. Biliary cystadenoma and cystoadenocarcinoma: clinical-imaging-pathologic correlation with emphasis on the importance of ovarian stroma. *Radiology.* 1995;196:805-10.
97. Zhou JP, Dong M, Zhang Y, Kong FM, Guo KJ, Tian YL. Giant mucinous biliary cystadenoma: a case report. *Hepatobiliary Pancreat Dis Int.* 2007;6:101-3.
98. Wheeler DA, Edmondson HA. Cystadenoma with mesenchymal stroma in the liver and the bile ducts. A clinicopathologic study of 17 cases. *Cancer.* 1985;56:1434-45.
99. Daniels JA, Coad JE, Payne W, Kosari K, Sielaff TD. Biliary cystadenomas: hormone receptor expression and clinical management. *Dig Dis Sci.* 2006;51:623-8.
100. Lauffer JM, Baer HU, Maurer CA, Stoupis C, Zimmerman A, Buchler MW. Biliary cystoadenocarcinoma of the liver: the need for complete resection. *Eur J Cancer.* 1998;34:1845-51.
101. Lim JH, Jang KT, Rhim H, Kim YS, Lee KT, Choi SH. Biliary cystic intraductal papillary mucinous tumor and cystadenoma/cystadenocarcinoma differentiation by CT. *Abdom Imaging.* 2007;32:644-51.

102. Koffron A, Ferrario M, Rao S, Abecassis M. Intrahepatic biliary cystadenoma: role of cyst fluid analysis and surgical management in the laparoscopic era. *Surgery*. 2004;136:926-36.
103. Horsmans Y, Laka A, Gigot JP, Geubel AP. Serum and cystic fluid CA19-9 determinations as a diagnostic help in liver cysts of uncertain nature. *Liver*. 1996;16:255-7.
104. Sharma S, Dean AG, Corn A, Kohli V, Wright H, Sebastian A, et al. Ciliated hepatic foregut cyst: an increasingly diagnosed condition. *Hepatobiliary Pancreat Dis*. 2008;7:581-9.
105. Ben Mena N, Zalinski S, Svrcek M, Lewin M, Fléjou JF, Wendum D, et al. Ciliated hepatic foregut cyst with extensive squamous metaplasia: report of a case. *Virchows Arch*. 2006;449:730-3.
106. Kiyochi H, Okada K, Iwakawa K, Nakanisshi M, Satoh H, Iimori S, et al. Ciliated hepatic foregut cyst with obstructive jaundice. *Case Rep Gastroenterol*. 2008;2:479-85.
107. Fernandez L, Nuño J, García-Moreno F, Lopez-Hervas P, Quijano Y, Mena A, et al. Quiste hepatico ciliado embrionario multilocular, Aportación de un nuevo caso y revisión de la literatura. *Rev Esp Enferm Dig*. 2005;97:606-8.
108. Shaw JM, Krige JEJ, Beningfield SJ, Locketz ML. Ciliated hepatic foregut cyst: a rare cystic liver lesion. *J Gastrointest Surg*. 2008;12:1304-5.
109. Straus T, Osipov V. Ciliated hepatic foregut cyst in a patient with renal cell carcinoma. *BMC Cancer*. 2006;6:244-50.
110. Fang SH, Dong DJ, Zhang SZ. Imaging features of ciliated hepatic foregut cyst. *World J Gastroenterol*. 2005;11:4287-9.
111. Hirata M, Ishida H, Konno K, Nishiura S. Ciliated hepatic foregut cyst: case report with an emphasis on US findings. *Abdom Imaging*. 2001;26:594-6.
112. Goodman MD, Mak GZ, Reynolds JP, Tevar AD, Pritts TA. Laparoscopic excision of a ciliated hepatic foregut cyst. *JSLs*. 2009;13:96-100.
113. Furlanetto A, Palo dei Tois A. Squamous cell carcinoma arising in a ciliated hepatic foregut cyst. *Virchows Arch*. 2002;441:296-8.
114. Les I, Córdoba J, Vargas V, Guarner L, Boyé R, Pineda V. Pseudoquiste pancreático de localización hepática. *Rev Esp Enferm Dig*. 2006;98:616-20.
115. Chen BK, Gamagami RA, Kang J, Easter D, Lopez T. Symptomatic post-traumatic cyst of the liver: treatment by laparoscopic surgery. *J Lap Adv Surg Tech*. 2001;11:41-2.
116. Martin DR, Kalb B, Sarmiento JM, heffron TG, Coban I, Adsay NV. Giant and complicated variants of cystic bile duct hamartomas of the liver: MRI finding and pathological correlation. *J Magn Reson Imaging*. 2010;31:903-11.
117. Rocken C, Pross M, Brucks U, Ridwelski K, Roessner A. Cholangiocarcinoma occurring in a liver with multiple bile duct hamartomas. *Arch Pathol Lab Med*. 2000;124:1704-6.