

Image of the Month

Aortic Thrombosis in a Patient With Essential Thrombocythemia[☆]

Trombosis aórtica en paciente con trombocitemia esencial

Joaquín Campos Franco,^{a,*} Lucía Martínez Lesquereux,^b Carmen Seoane Pose,^c
Gerardo Pazos González^c

^a Servicio de Medicina Interna, Complejo Hospitalario Universitario de Santiago de Compostela, Santiago de Compostela, Spain

^b Servicio de Cirugía General, Complejo Hospitalario Universitario de Santiago de Compostela, Santiago de Compostela, Spain

^c Servicio de Radiodiagnóstico, Complejo Hospitalario Universitario de Santiago de Compostela, Santiago de Compostela, Spain

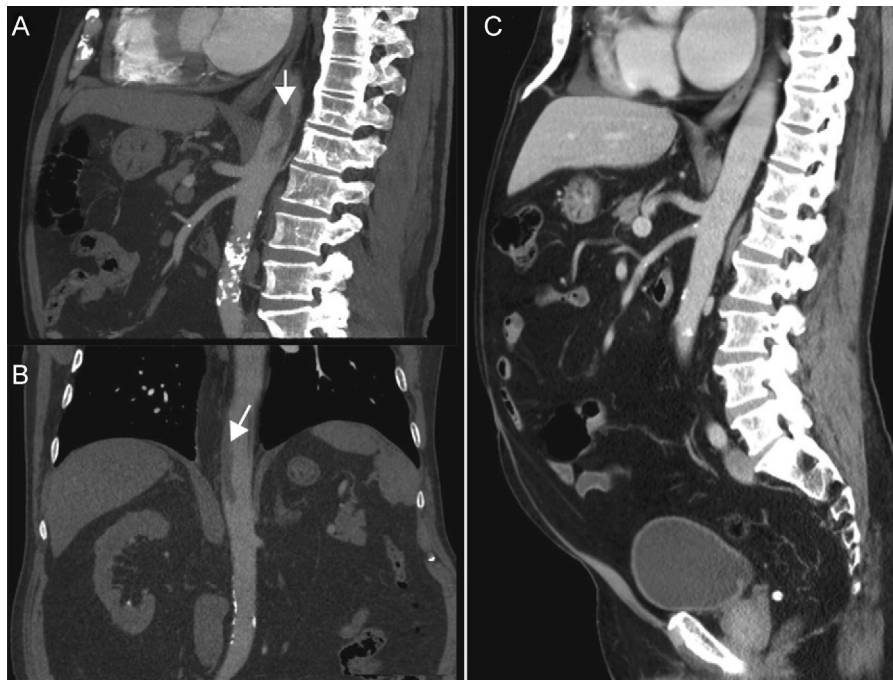


Fig. 1

A 74-year-old male with a history of essential thrombocythemia treated with hydroxyurea presented with epigastric abdominal pain. An emergency blood test demonstrated thrombocytosis (902,000 platelets/ μ L). Abdominal computed tomography (CT) revealed the presence of a thrombus in the initial portion of the abdominal aorta (Fig. 1A and B, left) as well as hypodense lesions of the spleen compatible with splenic infarctions. A conservative approach was decided; antiplatelet treatment was initiated and the patient had a favourable response. One month later, abdominal CT confirmed the disappearance of the aortic thrombus (Fig. 1C, right).

[☆] Please cite this article as: Campos Franco J, et al. Trombosis aórtica en paciente con trombocitemia esencial. Cir Esp. 2013;91:e9.

* Corresponding author.

E-mail address: xkamos@hotmail.com (J. Campos Franco).