



Special Article

Treatment of Complex Cryptoglandular Anal Fistulas. Does it Still Require an Experienced Surgeon? ☆,☆☆

José V. Roig,^{a,1,*} Juan García-Armengol^{b,1}

^aUnidad de Coloproctología, Servicio de Cirugía General y del Aparato Digestivo, Consorcio Hospital General Universitario de Valencia, Valencia, Spain

^bUnidad de Coloproctología, S.C. Hospital 9 de Octubre, Valencia, Spain

ARTICLE INFO

Article history:

Received 5 September 2011

Accepted 14 October 2011

Available online 22 June 2013

Keywords:

Complex anal fistula

Cryptoglandular fistula

Anal incontinence

Fistulotomy

Advance rectal flap

Ligature of the inter-sphincter trajectory

Sealants

Anal Fistula Plug

A B S T R A C T

There is still controversy on the management of complex cryptoglandular fistulas, even after employing the newest, theoretically simple, techniques. A critical review of the literature was performed, in order to clarify the role of the surgeon, where the precarious balance between eradicating sepsis and maintaining anorectal influences the choice. Techniques, such as fistulotomy, immediate sphincter repair or ligature of the inter-sphincter trajectory, are discussed. The new sphincter preserving techniques, such as sealing, use of plugs and cell therapy are also analyzed. However, with a few exceptions, the scientific evidence is low or zero, due to the lack of clinical trials and to the large variation in the presentations and technical details that could influence the results. For this reason, experience in treating complex cryptoglandular fistulas is still essential.

© 2011 AEC. Published by Elsevier España, S.L. All rights reserved.

* This study has been presented at three conferences: IVth Annual Meeting, European Society of Coloproctology, Prague 2009; XIX Congresso Nacional Português de Coloproctología, Porto 2009; and Association of Coloproctology of Great Britain & Ireland Annual Meeting, Bournemouth 2010.

☆☆ Please cite this article as: Roig JV, García-Armengol J. Tratamiento de las fístulas de ano complejas de causa criptoglandular. ¿Aún se requiere un cirujano con experiencia? Cir Esp. 2013;91:78-89.

* Corresponding author.

E-mail address: roig_jvi@gva.es (J.V. Roig).

¹ European Board in Coloproctology.

Abbreviations: CF, complex fistula; IOF, internal orifice of the fistula; RF, risk factors; AFC, alterations in fecal continence; EAS, external anal sphincter; IAS, internal anal sphincter; EAF, endorectal advancement flap; ISR, immediate sphincter repair; LIFT, ligation of intersphincteric fistula tract; AFP, anal fistula plug; VAAFT, video-assisted anal fistula treatment.

2173-5077/\$ - see front matter © 2011 AEC. Published by Elsevier España, S.L. All rights reserved.

Tratamiento de las fístulas de ano complejas de causa criptoglandular. ¿Aún se requiere un cirujano con experiencia?

RESUMEN

Palabras clave:

Fístula de ano compleja
Fístula criptoglandular
Incontinencia anal
Fistulotomía
Colgajo de avance rectal
Ligadura del trayecto interesfintérico
Sellantes
Anal Fistula Plug

Sigue habiendo controversias en el manejo de las fístulas de ano complejas de origen criptoglandular (FC) incluso tras el empleo de técnicas novedosas teóricamente más simples. Para clarificar el papel del cirujano colorrectal en su tratamiento, se efectúa una revisión crítica de la literatura basándonos en que el precario balance entre erradicar la sepsis y mantener la función anorrectal afecta la elección. Se discuten técnicas como la fistulotomía, colgajos de avance, reparación esfinteriana inmediata o ligadura del trayecto interesfintérico. También se analizan las nuevas tecnologías preservadoras del esfínter como el sellado, empleo de tapones y terapia celular. Sin embargo, con escasas excepciones, la evidencia científica es baja o nula debido a la escasez de ensayos clínicos y a que hay gran variabilidad de presentaciones y de detalles técnicos que pueden influir en el resultado. Por tanto, la experiencia en el tratamiento de las FC sigue siendo esencial.

© 2011 AEC. Publicado por Elsevier España, S.L. Todos los derechos reservados.

Introduction

Fistulas are one of the most common anorectal problems. They have been treated for millennia: the *Corpus Hippocraticum*¹ discusses the use of setons or fistulotomy, as well as instruments for its treatment. In the 14th century, John Arderne² published a monographic text with therapies similar to current treatments, and Félix de Tassy successfully operated on Luis XIV of France after a “prospective assay” amongst members of the Court.³ Nevertheless, it was Frederick Salmon, founder of the London charity institution *St Mark’s Hospital for Fistula and other Diseases of the Rectum*, who began the trail toward a scientific approach to the problem.⁴

We know that most fistulas are cryptoglandular in etiology and originate from an infection of the intersphincteric space, although there is no unequivocal confirmation of this theory.⁵ We diagnose them better, although the evaluation of an expert surgeon is most important.⁶ But, how should we treat them? There is no evidence to determine how to ideally maintain the stable balance between continence control and curing the septic process,⁷ especially when treating complex fistulas (CF), defined as those in which the tract includes an important part of the anal sphincter or those associated with or at high risk of fecal incontinence.

Fistula surgery, feared by some and in some cases obscure, has always had a sort of artisan element. Quite possibly, the need for three-dimensional assessment, difficulties in following the trajectories, finding the internal orifice of the fistula (IOF) or not compromising the sphincters have contributed to the fact that not too many surgeons have tried to deal with difficult cases. Many aspects, however, have been clarified: we can evaluate the anatomy of the fistula and its relationship with the sphincters, there are multiple therapeutic options, and less-aggressive therapies have arisen in which the verbs *dissect*, *cut* and *suture* have been substituted with *seal*, *plug* or *implant*, encouraging even the most timid to embark on treating complex cases, driven by the industry.

Undoubtedly, we must be open to change, but what is the current state? What do new treatments provide? In short, are

colorectal surgeons still required to treat a CF? The objective of the present article is to clarify this with evidence, data and a few reflections.

Risk Factors for Recurrence and Incontinence After “Classic” Surgery

Excluding Crohn’s, tuberculous or rectovaginal fistulas, there is great variability in the recurrence rate, which can range between 0% and 65% although usually situated at around 5%–8%.^{8–10}

The most widely used classification was described by Parks,¹¹ according to which suprasphincteric and extrasphincteric fistulas are the most difficult to treat, although they are fortunately the most uncommon. In addition, the risk factors (RF) for recurrence are: horseshoe extension, number of previous interventions,⁸ CF,¹² not finding the IOF^{8,9,12,13} and surgeon variables.⁸ In a group treating anal fistulas, the surgeon who operated on 55% of patients had a recurrence rate of 3.9% compared with 11.2% of the remainder, which attests to the influence of experience in this process.¹²

In addition, post-operative alterations in fecal continence (AFC) are frequent. Marks and Ritchie reported that 25% of patients had gas leaks, 17% liquid stool leaks and 3% solid stool, while 31% of patients presented mucus leaks or soiling.¹⁴ Soiling or mucus leaks are not considered in many series and there are such disparate results that some authors report less post-operative FI than other studies report before surgery.^{15–18} Thus, in our own case series, 14.9% of patients presented pre-operative FI,¹⁹ which is more than double that of the general population²⁰; this percentage increased after surgery to 49.1%, as observed by other authors.^{13,17} If patients are not directly asked about incontinence, its frequency is obviously underestimated. Given the prevalence of soiling, it would be interesting to add this variable to classification scores such as the Cleveland Clinic incontinence score.²¹

In 1934, Milligan and Morgan²² observed that, “If the anorectal ring is cut, the appearance of incontinence is certain”. This still holds true today and it has been

demonstrated to be a risk factor in univariate studies, along with high anal fistulas, female sex, anterior tracts, high IOF, vertical tracts, advanced age, double fistulas and previous surgery^{8,17,23,24}; meanwhile, multivariate studies show previous incontinence and hypotonic sphincter as RF.^{12,23} Colorectal surgery associations recommend that if more than 30% of the external anal sphincter (EAS) is to be cut, this should be done with caution by an experienced surgeon, especially in high risk cases.^{25,26}

Why is it Difficult to Decide on an “Ideal Treatment”?

This is largely due to the variability in the concept of CF, which basically includes difficult-to-treat fistulas (with possible risk to patients' continence), such as suprasphincteric and extrasphincteric fistulas, because fistulotomy would harm much of or all of the sphincters, and other treatments are technically difficult. High transsphincteric fistulas are also complicated, as well as those with RF, as mentioned. For their treatment, a wide variety of techniques have been described. Which is best? The levels of evidence rarely surpass that of an expert consensus. This is due to the different types of fistulas and clinical presentations, disparate results and ways of evaluation. On top of this, if we add the final opinions of each surgeon, the discussion turns into a veritable Tower of Babel.

Is Fistulotomy Obsolete?

Laying open the fistula tract is one of the oldest treatments. It may be used for simple fistulas with a level of evidence II and grade of recommendation B²⁵; and with level I and recommendation B, fistulotomy can be considered better than fistulectomy, given that the latter generates a wound that takes longer to cure and causes more damage to the sphincters.^{25,27,28} Fistulotomy is the method that offers more possibilities for a cure, at around 90%.¹³ But, there have been unacceptable rates of serious FI observed in CF and even 5% in simple fistulas.²⁹ Nonetheless, a recent article of the St. Mark's group³⁰ shows a cure rate of 96% of CF with fistulotomy, with a low rate of FI, and they therefore recommend its use in experienced hands. The use of radio-frequency has shown no benefits.⁷

The use of a seton does not greatly improve the results. With cutting setons, the rate of incontinence is proportional to the speed of cutting, and recurrences and FI are similar to those of fistulotomy.^{26,31,32} The latter has been reported in 18%.³³ But, what if the seton is snug but not tight, as in the *snug seton* concept by Hammond et al.³⁴? Cutting is progressive but slow, and in 52% the seton falls out spontaneously in 6 months, while in the remainder a minimal fistulotomy is needed, with reports of minor FI. Preserving or cutting the internal anal sphincter (IAS) with the placement of the seton also changes the results, and a recent meta-analysis showed that its preservation reduced post-operative incontinence.³⁵ In any case, fistulotomy and seton significantly deteriorate

Table 1 – Results of Treating Cryptoglandular CF With Fistulotomy or Staged Seton.

Fistulotomy				
Author	Number of cases	Follow-up, months	Recurrence or persistence, %	Incontinence, %
Kronborg, 1985 ²⁷	24	12	12.5	NS
Van Tets et al., 1994 ¹⁵	312	NS	6	24
Sangwan et al., 1994 ¹⁰	461	34	7	NS
García Aguilar et al., 1996 ⁸	624	29	8	45
Westerterp et al., 2003 ³⁶	11	12–48	0	82
Jordán et al., 2010 ¹²	62	19	1.5	10.2
Bokhari y Lindsey, 2010 ²⁹	68	NS	13	13 ^a
Seton				
Author	Number of cases	Follow-up, months	Persistence or recurrence, %	Incontinence, %
Ramanujam et al., 1983 ³⁷	45	NS	2	2
Williams et al., 1991 ³⁸	24	NS	8	54 ^a
Pearl et al., 1993 ³⁹	65	23	3	5 ^b
Graf et al., 1995 ⁴⁰	25	46	8	44
García-Aguilar et al., 1998 ⁴¹	47	27	9.2	65.9
Hasegawa et al., 2000 ⁴²	32	12	29	46
Hammond et al., 2006 ³⁴	29	42	0	25 ^a
Chuang-Wei et al., 2008 ⁴³	112	39	0.9	24 ^a
Lykke et al., 2010 ⁴⁴	41	NS	12	61

NS: not specified.

^a Minor.

^b major.

The concept of incontinence is not uniform among the articles analyzed.

sphincter pressures and anatomy,¹⁹ and surgeons who use them navigate like Ulysses between the monsters Escila and Caribdis, since aggressive treatment would mean incontinence and timid treatment would lead to recurrence^{8,10,12,15,27,29,34,36-44} (Table 1). A score has been described to determine whether the patient is able to be treated with fistulotomy by evaluating RF, including type of fistula, sphincter function and defecation habits.⁴⁵ Finally, leaving a loose seton in patients without Crohn's disease is associated with almost 50% of recurrences, and it is not useful in practice.⁴⁶

What is an acceptable treatment of CF? The use of fistulotomy in recurrent cases, with predominantly posterior fibrosis, in males with good muscle mass and a normal rhythm of defecation. But, of course, all this was before the appearance of sealing techniques...

A Good Option: Advancement Flaps

Possibly the gold standard for treating CF is endorectal advancement flap (EAF) surgery, as described by Noble⁴⁷ at the beginning of the 20th century, with later modifications.^{48,49} Technically, after surgically removing the extrasphincteric part of the tract, the mucosa is resected distal to the IOF and a flap is created with a wide base using rectal submucosa or mucosa, partially including the IAS or even including its entire thickness. Afterwards, the IOF is closed and the repair is covered with the flap.

Perhaps what is most important is correct closure of the IOF, which can also be reinforced with lateral or transversal plasty of the IAS or the rectal circular muscle layer.^{50,51} The EAF is a good technique to treat suprasphincteric, high or even low transsphincteric fistulas in patients at risk for incontinence. However, it may be technically demanding in recurrent fistulas with scar tissue that may make it difficult to even insert a retractor. In cases with technical difficulties, an anal skin flap can be created by advancing the perianal skin proximally toward the anal canal; this has obtained slightly poorer results.^{52,53}

The series are not homogenous: many are retrospective, some have selection biases and others have personal contributions that limit the power of the data obtained. Recurrences range from 0% to 33%, with an average of 19%⁵⁴ and the lack of interest that some authors show for assessing post-op continence is striking^{19,55-66}; alterations occur in about 13% of patients⁵⁴ (Table 2).

Overall, EAF is recommended in cases in which fistulotomy would cause FI (recommendation grade B),^{25,26} and it has an established role in the armamentarium of colorectal surgeons. The differences in the results suggest that technical factors are fundamental. Identified risk factors for failure include smoking^{67,68} and the associated use of adhesives.^{69,70} There is still controversy about which type of flap is better,⁵⁴ either complete or partial.⁷¹

The observation that in all the cases of failure the EAF had specifically failed at the IOF level has made researchers think that this may be due to persistent disease and consider whether a loose seton should be previously used or not.⁶³ It theoretically reduces suppuration and abscess cavities and is widely used as a first stage surgery.²⁶ However, reported cure rates are 63% if it is not used, compared with 67% when it is.⁷²

Although theoretically it does not harm the sphincters, FI after EAF is not unusual; it is possibly caused by the anal dilation necessary to carry out a technique that is often difficult.⁷³ So, it is one of the interventions that most affects the function of the IAS.¹⁹ It has also been speculated that a total thickness flap would have more effect on continence,⁷⁴ and a series of our own showed 51% FI compared with 33% after a mucosal-submucosal flap; $P=0.08$.⁷⁵ Even a certain degree of mucosal ectropion can lead to soiling.⁵⁴

And Why Not Reconstruct the Sphincter After Cutting it?

Since fistulotomy provides the best chance for a cure and its biggest problem is FI, one option would be immediate sphincter repair (ISR); it has excellent results after acute

Table 2 – Results of Treatment of Cryptoglandular CF With Endorectal Advancement Flap.

Author	Number of cases	Follow-up, months	Persistence or recurrence, %	Incontinence, %
Aguilar et al., 1985 ⁵⁵	189	8-84	1.5	10
Wedell et al., 1987 ⁵⁶	27	18-48	3.4	27.6
Ozuner, 1996 ⁵⁷	101	31	29	NS
Golub et al., 1997 ⁵⁸	164	19-135	3.3	15
Miller and Finan, 1998 ⁵⁹	25	18	0	0
Ortiz and Marzo, 2000 ⁶⁰	103	12	7	8
Sonoda et al., 2002 ⁶¹	48	17	22.9	NS
Mizrahi et al., 2002 ⁶²	41	40	33	NS
Mitalas et al., 2007 ⁶³	87	15	33	3.4
Uribe et al., 2007 ⁶⁴	51	44	7.1	19.6
Ortiz et al., 2008 ⁶⁵	91	42	17.6	12.1
Abbas et al., 2008 ⁶⁶	36	27	17	NS
Van Koperen et al., 2008 ¹³	70	76	21	40 ^a
Roig et al., 2009 ¹⁹	45	19/62 ^b	20	52.8 ^a

NS: not specified.

^a Including soiling.

^b Long-term telephone follow-up.

The concept of incontinence is not uniform among the articles analyzed.

Table 3 – Results of the Treatment of Cryptoglandular CF With Fistulotomy and Immediate Sphincter Repair.

Author	No.	Follow-up, months	High anal fistulas, %	Sphincter dehiscence, %	Persistence or recurrence, %	Incontinence, %
Parkash et al., 1985 ⁷⁷	120	6–60	1.6	3.3	2.5	3.6 ^a
Lux et al., 1991 ⁷⁸	46	15	56.5	0	0	19.2 ^b
Christiansen et al., 1995 ⁷⁹	14	12–96	100	0	14.3	21.4 ^a
Lewis et al., 1996 ⁸⁰	32	NS	100	NS	9.4	NS
Roig et al., 1999 ⁸¹	31	24	87	3.2	9.7	16.7 ^a
Pérez et al., 2005 ⁸²	35	32	100	0	5.7	12.5 ^a
Jivapaisarnpong, 2009 ⁸³	33	14	94	NS	12.1	0
Roig et al., 2010 ⁷⁵	75	13	76	1.3	10.6	21.4 ^a

NS: not specified.
^a Minor.
^b Occasional liquid feces.

trauma if there is no loss of substance.⁷⁶ This should be restricted to tracts that have no abscess cavities and when there is fibrosis that impedes creating a flap. It would be indicated in high or recurrent fistulas, preferably associated with incontinence due to previous sphincter lesions. The technique includes fistulotomy, debridement of the tract, primary sphincter reconstruction and careful closure of the mucosa of the anal canal. Despite its results^{75,77–83} (Table 3), the technique has been met with skepticism in surgical forums, even though it is a good option in selected cases.⁸⁴ Recurrences were similar to those of EAF in a randomized study⁸⁵; it does not alter continence in previously continent subjects and it improves continence in incontinent patients.⁸¹ A study of our own also compared it with flaps and observed postoperative deterioration in continence. Nonetheless, previously incontinent patients improved after ISR.⁷⁵

Ligation of the Intersphincteric Fistula Tract

A suggestion by Matos, Lunniss and Phillips⁸⁶ to preserve the sphincter has recently been modified.⁸⁷ It involves making an incision at the level of the intersphincteric groove, identifying the tract, ligation close to the IOF and resection of the intersphincteric portion.⁸⁸ Although it has been described as simple and reproducible, the patients must have been carefully selected or it is difficult to understand how certain fistulas were treated. The initial publication showed only one recurrence, but this has not been reproduced by other authors, although cases of FI have not been described after the

procedure^{87,89–93} (Table 4). There are no comparative studies with other techniques.

A recent modification associates the placement of a biological prosthesis to separate the ligated ends of the tract.⁹³ Although the preliminary results have been good, in order to insert the prosthesis a more extensive dissection is required, which may harm the sphincters, and the cost of the material must also be considered.

Sealants: The End of the Risk of Incontinence

In the era of minimally invasive surgery, the introduction of synthetic biological materials has led to the emergence of techniques for filling up the tract with a biomaterial. The sealant occludes the tract, and stimulates the migration, proliferation and activation of fibroblasts and endothelial pluripotent cells, acting as a matrix for cell growth and tissue integration.⁹⁴

Fibrinogen with thrombin has been used, a mix that produces fibrin glue (Tissucol[®]), autologous fibrin, bovine albumin+glutaraldehyde (BioGlue[®]) or cyanoacrylates (Glu-bran[®]). One would think that, with all these products, we would have a standardized and reproducible technique available that would make any surgeon capable of treating fistulas with minimal morbidity. But, it is not clear if the successes are due to the biomaterial per se or to the setting in which it is placed. Is it better to previously eradicate septic cavities? Is antibiotic prophylaxis required? Debride the tract and/or use abrasives? Close the IOF or not (which is a

Table 4 – Results of the Treatment for Cryptoglandular CF Using Ligation of Intersphincteric Fistula Tract (LIFT).

Author	Number of cases	Mean follow-up, months	Persistence or recurrence, %	Incontinence, %
Rojanasakul et al., 2007 ⁸⁷	18	6.5 ^b	5.6	0
Shanwani et al., 2010 ⁸⁹	45	9	17.8	0
Bleier et al., 2010 ⁹⁰	35	5	43	0
Aboulian et al., 2011 ⁹¹	25	6	32	0
Ooi et al., 2011 ⁹²	25	5.5	32	0
Ellis ^a , 2010 ⁹³	31	15	6	0

^a Associating a biological mesh (BioLift).

^b Maximum follow-up.

Table 5 – Results of the Treatment of Cryptoglandular CF Using Biological Sealants.

Author	Number of cases	Material used	Mean follow-up, months	Persistence or recurrence, % ^a	Incontinence, %
Venkatesh and Ramanujam, 1999 ⁹⁶	30	Autologous fibrin	NS	40	0
Cintron et al., 2000 ⁹⁷	26	Autologous fibrin	12	46	NS
Cintron et al., 2000 ⁹⁷	53	Tissucol [®]	12	36	NS
Patrlj et al., 2000 ⁹⁸ &	30	Tisseel [®]	28	26	0
Lindsey et al., 2002 ⁹⁹	13	Tissucol [®]	3	31	0
Sentovich et al., 2003 ¹⁰⁰ &&	48	Tissucol [®]	22	31	0
Buchanan et al., 2003 ¹⁰¹	22	Tissucol [®]	14	86	0
Louhghnarath et al., 2004 ¹⁰²	22	Tissucol [®]	26	77	NS
Singer et al., 2005 ¹⁰³	75	Tissucol [®]	27	75 ^d /56 ^e /65 ^f	0
Barillari et al., 2006 ¹⁰⁴	14	Glubran [®]	18	28.6	0
De la Portilla et al., 2007 ¹⁰⁵ /2010 ¹⁰⁶	14	BioGlue [®]	14/60	50 ^b /78.6 ^c	NS
Damin et al., 2009 ¹⁰⁷	30	Tissucol [®]	12	90	0
Queralto et al., 2010 ¹⁰⁸	34	Glubran [®]	34	32.4	0
Altomare et al., 2011 ¹⁰⁹	39	Tissucol [®]	12	61.6	0

NS: not specified.

^a On occasions, after a second injection due to persistence of fistula;

^b Mean follow-up of 14 months.

^c Mean follow-up 60 months.

^d Sealant plus antibiotic.

^e Sealant plus IOF closure.

^f Sealant plus both.

technique in and of itself⁹⁵)? Repeat sealing? For all these factors, there is a low level of evidence (level III, recommendation grade B) for their use in CF.²⁶

The initial success rates of 60%–70% worsened over the long term to reach a recurrence rate of 70%–100%^{96–109} (Table 5). However, the non-invasive nature and safety of sealants make them a reasonable first line of treatment in certain cases. A randomized study comparing setons with fibrin glue showed more favorable results for the latter, which is not surprising given the low effectiveness for a cure with a loose seton.⁹⁹ Another study compared cutting setons with fibrin sealing and found 12.5% of recurrences in the former compared with 60% in the latter, but with a more uncomfortable post-operative period and significant FI using setons.¹⁰⁹

The use of sealants, however, has been associated with perianal sepsis.¹¹⁰ It thus seems important to eliminate granulation tissue, close the IOF if it is large and avoid fragmentation of the glue to avoid trapping bacteria and detritus.¹⁰⁵

The treatment does not alter continence and is well tolerated, but it is actually not very effective. It was suggested that a long tract favored the efficacy of sealing,⁹⁶ but other authors observed that the opposite was true,¹⁰⁰ and some found no relationship with this factor or with the location of the IOF.¹⁰⁵ The sealant is reabsorbed in a few days, which is insufficient time to be able to serve as a matrix for tissue reparation. No one glue has been shown to be better than others as there are no comparative studies, but the material is undoubtedly another variable added to the complexity of fistulas and the technical details of their treatment. Do we see the bottle half full? With sealants we will be able to cure some patients without any risks, although, of course, we will be consuming resources. Perhaps this treatment is indicated if the sphincter function is poor or if the surgical risk is high, but the patients have to be informed of the expected results.¹⁰⁹

It has been suggested that the association of sealants with an EAF could improve results. However, a randomized study showed 46% of recurrences in the sealant branch+EAF compared to 20% if EAF was used alone.⁶⁹ Another study of this combination showed evidence of 88% persistence/recurrence.⁷⁰ The biomaterial may possibly create difficulties for contact between the edges of the flap or it may block the drainage of secondary tracts.

Fistula Plugs: A Simple Technique, But Safe and Effective?

Five years ago, bioabsorbable xenografts made of pig intestinal submucosa were introduced in the market. The so-called anal fistula plug (Surgisis[®] AFP[™]) is a cone-shaped device that is inserted in the fistula tract, after curetting and/or treating with abrasives, and attached to the IOF so that it occludes it. Later, it provides a framework for infiltration of connective tissue.

In 2006, Johnson et al.¹¹¹ initially reported a success rate of 87%, much higher than using adhesives. Other publications with longer follow-ups have not reproduced these results, and the cure rates have been around 28%^{111–126} (Table 6). In one series, the cure rate diminished from 80% in the short term to 55% 6 months later.¹¹⁶ Garg et al., in a systematic review on CF, found a cure rate of 35%–87% and 13%–71% of recurrences.¹²⁷ The results are worse in shorter tracts,¹²⁸ and a multivariate analysis has shown that smoking, posterior fistulas and recurrences prior to a plug are risk factors for failure.¹²⁴

About 19% of failed cases debut when the plug falls out, technical errors due to insufficient fixation or excessive tension. Another common cause of morbidity is post-operative abscess, which is seen in 4%–29% of cases¹²⁷ and can be reduced with a meticulous technique.¹²⁹ Post-operative FI has not been reported.

Although some retrospective studies show less recurrences with EAF compared with plugs in high fistulas,^{119,122} only two

Table 6 – Results of the Treatment of Cryptoglandular CF With the Use of Anal Fistula Plug.

Author	Number of cases	Mean follow-up, months	Persistence or recurrence, %	Extrusion/ abscess, * %
Johnson et al., 2006 ¹¹¹	15	3.5	13	NS
Champagne et al., 2006 ¹¹²	46	12	17.4	9
Van Koperen et al., 2007 ¹¹³	17	7	58.8	41
Schwandner et al., 2008 ¹¹⁴	12	9	54.5	10/10*
Christoforidis et al., 2008 ¹¹⁵	47	5	61.7	22/4*
Ky et al., 2008 ¹¹⁶	20	6.5	65	10*
Thekkinkattil et al., 2009 ¹¹⁷	36	11	50	23
Garg, 2009 ¹¹⁸	21	9	28.6	24/5*
Christoforidis et al., 2009 ¹¹⁹	37	14	68	19
Chung et al., 2009 ¹²⁰	30	3	39.7	NS
Ortiz et al., 2009 ¹²¹	15	12	80	20/6.6*
Wang et al., 2009 ¹²²	29	9	66	NS
El Gazzah et al., 2010 ¹²³	26	7	65.4	25
Ellis et al., 2010 ¹²⁴	63	12	24	1.6
Lenisa et al., 2010 ¹²⁵	60	13	40	0*
Van Koperen et al., 2011 ¹²⁶	31	11	71	13/3.1

NS: not specified.

randomized prospective studies compare them. Ortiz et al.¹²¹ observed 80% recurrence in patients with plugs vs 12.5% with EAF (RR=6.4), although the study was prematurely stopped. Nevertheless, van Koperen et al.¹²⁶ found no differences in either recurrences (AFP=71%; EAF=52%), nor in post-operative dysfunction or quality of life.

As in the case of association with adhesives, plugs increase recurrence if associated with an EAF,¹³⁰ so its use is not recommended.

Thus, collagen plugs are a therapeutic alternative, especially in patients with long-tract CF. Attention to detail is essential during their implantation, as are measures to prevent infection (previous seton drainage) in order to improve the results, and they should be used by experienced surgeons.^{124,127,131} There are no data that recommend plugs as a first line of treatment in high fistulas.

In order to avoid premature failure due to extrusion, newer plugs are now commercialized with a button-like end (Biodesign™ Surgisis® Fistula Plug), with a few been reports of limited efficacy in pouch-vaginal and rectovaginal fistulas.¹³² Another plug (GORE® BIO-A® Fistula Plug) has a 16 mm disc that can be cut to fit the defect, which is coupled to two tubes that are 9 cm long but can be fitted to the tract. It is a fibrous-porous structure made up of a biodegradable synthetic copolymer of trimethylene carbonate and glycolide, so it is therefore not biological material. There are still no publications about its use.

Recently, a new treatment has been reported in a pig model using acellular collagen paste resistant to enzymatic degradation (Permacol®), either alone or associated with autologous fibroblasts, compared with a control group that underwent 'core-out' fistulectomy. All the filled tracts were cured, with the observation that the autologous fibroblasts were better integrated in the tissue, but only 2 out of 7 patients in the control group were cured.¹³³ Clinically, it has been used in a phase 1 study using either strips or an injection of shredded collagen (Permacol®) diluted in fibrin glue to aid in its retention in the initial stages of healing. After 29 months, no patient had developed abscesses or FI.

54% of fistulas were cured vs 80%, although without statistical significance.¹³⁴

Stem Cells: The Future of Proctology?

Adult stem cell therapies have promising applications in many areas of medicine. An attractive manner to obtain them is through liposuction. The first published procedure was that of a woman with Crohn's disease and refractory rectovaginal fistula. The cells were injected in the rectal mucosa close to the IOF that had been previously sutured and a vaginal advancement flap was created. The wound healed quickly and there was no relapse during the 3 months of follow-up.¹³⁵ Afterwards, García Olmo et al. designed a phase I trial that concluded that the treatment was safe and effective for inducing a cure in patients with CF, including those with Crohn's disease.¹³⁶ In another phase II study, 49 patients with CF were randomized to receive stem cells and fibrin glue or isolated fibrin glue as a control group. The combination was shown to be effective and safe with 4 times more possibility for a cure than the control group.¹³⁷ We are now expecting the publication of a multicenter phase III trial in cryptoglandular FC with more than 200 patients. Whatever the results are, this research will surely lead to new possibilities.

And the Endoscopic Approach...

Recently, a new device has come onto the market, called the Video-Assisted Anal Fistula Treatment (VAAFT) (Karl Storz Endoskope), which consists of a rigid fistuloscope with a working channel and an irrigation channel that provides fistula treatment. The IOF is closed with endoanal sutures and stapling, using the semicircular Contour® Transtar™ device or a linear cutter-stapler, which is unlikely to be innocuous in the anal canal. The staples are also sealed with cyanoacrylate. The author affirms that "the technique is sphincter-saving... and the patients have no problems with incontinence" due to "complete destruction of the fistula from the inside".¹³⁸ There has been no

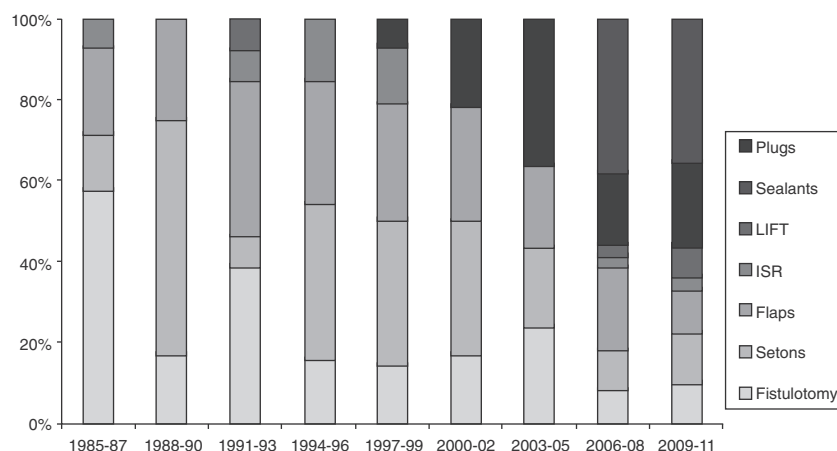


Fig. 1 – Triennial evolution of the publications (PubMed) about different techniques for the treatment of anal fistulas (1985–2011). Results expressed in percentage of the total. Observe the increase in biological therapies in recent years until reaching almost 60% of the total. LIFT: ligation of intersphincteric fistula tract; ISR: immediate sphincter repair.

series published, but it does not seem to be an advantageous option despite the cost.

Final Comments

Martin Van Butchell, a disciple of Hunter, ran an advertisement in the London Morning Herald in 1789 that read: “Fistula-in-ano: No cure, no pay. This teasing, local disease is radically cured (sometimes in one week, always in two) without cutting, dressing, medicine, cautery, injection, risk, confinement, loss of blood, or an atom found parts.¹³⁹” He was an eccentric charlatan who did not live up to what he promised. More than 200 years later, we surgeons still cannot make his claim a reality, and fistulas continue to pose problems in their approach, after-effects of their treatments or the alteration in quality of life that the disease or its therapies may condition.

There are very few prospective and randomized studies related to fistula treatment. It seems that there are no important differences between the techniques with regards to recurrences, although the use of biomaterials and advancement flaps are associated with less FI.^{140,141} Many therapies have not been developed on an experimental basis; instead, the enthusiasm for adopting new techniques guided by the industry is evident (Fig. 1). Thus, there are no therapeutic standards for such a common and prevalent problem.¹⁴²

The community of colorectal specialists should be urged to develop greater scientific evidence to decide which option is the best for a particular patient. Furthermore, functional alterations and quality of life do not necessarily correlate, so it would be important to analyze these aspects.¹⁴³

And, what is the opinion of the patients? In a survey, 74% would prefer not to risk their continence for a cure, versus 26% who would choose a fistulotomy,¹⁴⁴ although the information that the patients were given is arguable.

What to do with a complex case? Given the low degree of evidence available, surgery based on personal experience and refection of the different options is still valid. In short, the

treatment of anal CF still poses many gray areas in the era of evidence-based medicine, and the phrase by Lockhart-Mummery in 1929, “Probably more surgical reputations have been damaged by the unsuccessful treatment of a fistula than by excision of the rectum or gastroenterostomy”, still rings true.¹⁴⁵

Fistula surgery has passed through different historical periods: manual skills, scientific basis and developing biological therapies. We are sure that for some years we will continue to work with the three, but under the direction of an expert colorectal surgeon. So, for the question posed in the title of the article, the answer is, for now, yes.

Conflict of Interests

The authors declare having no conflict of interests.

REFERENCES

- Blanchard CE. The romance of proctology. Youngstown, OH: Medical Success Press Publishers. 1938.
- Arderne J. Treatises of fistula-in-ano. D’Arcy Power, Editor. English text society. Original series no. 139. Oxford: Oxford University Press. 1910.
- Pluchinotta A. Storia illustrata della proctologia. Padova: Ciba Geigy Edizioni. 1992.
- Greenshaw L. St Mark’s Hospital. A social history of a specialised hospital. Oxford: Oxford University Press. 1985.
- Phillips RKS, Lunniss P, editors. Anal fistula: surgical evaluation and management Londres: Chapman & Hall. 1996.
- Jordán J, Roig JV, García Armengol J, Esclapez P, Jordán Y, García Granero E, et al. Importancia de la exploración física y de los métodos de imagen en el diagnóstico de la fistula de ano. Cir Esp. 2009;85:238-45.
- Malik AI, Nelson RL. Surgical management of anal fistulae: a systematic review. Colorectal Dis. 2008;10:420-30.
- García-Aguilar J, Belmonte C, Wong D, Goldberg SM, Madoff RD. Anal fistula surgery. Factors associated with recurrence and incontinence. Dis Colon Rectum. 1996;39:723-9.

9. Sainio P, Husa A. Fistula-in-ano: clinical features and long-term results of surgery in 199 adults. *Acta Chir Scand.* 1985;151:169-76.
10. Sangwan YP, Rosen L, Riether RD, Stasik JJ, Sheets JA, Khubchandani IT. Is simple fistula-in-ano simple. *Dis Colon Rectum.* 1994;37:885-9.
11. Parks AG, Gordon PH, Hardcastle JD. A classification of fistula-in-ano. *Br J Surg.* 1976;63:1-12.
12. Jordán J, Roig JV, García-Armengol J, García-Granero E, Solana A, Lledó S. Risk factors for recurrence and incontinence after anal fistula surgery. *Colorectal Dis.* 2010;12:254-60.
13. Van Koperen PJ, Wind J, Bemelman WA, Bakx R, Reitsma JB, Slors FM. Long-term functional outcome and risk factors for recurrence after surgical treatment for low and high perianal fistulas of cryptoglandular origin. *Dis Colon Rectum.* 2008;51:1475-81.
14. Marks CG, Ritchie JK. Anal fistulas at St Mark's Hospital. *Br J Surg.* 1977;64:84-91.
15. Van Tets WF, Kuijpers HC. Continence disorders after anal fistulotomy. *Dis Colon Rectum.* 1994;37:1194-7.
16. Ho YH, Tan M, Leong AFP, Seow-Choen F. Marsupialization of fistulotomy wounds improves healing: a randomized controlled trial. *Br J Surg.* 1998;85:105-7.
17. Ommer A, Wenger FA, Rolfs T, Walz MK. Continence disorders after anal surgery - a relevant problem. *Int J Colorectal Dis.* 2008;23:1023-31.
18. Shouler PJ, Grimley RP, Keighley MRD, Alexander-Williams J. Fistula-in-ano is usually simple to manage surgically. *Int J Colorectal Dis.* 1986;1:113-5.
19. Roig JV, Jordán J, García-Armengol J, Esclapez P, Solana A. Changes in anorectal morphologic and functional parameters after fistula-in-ano surgery. *Dis Colon Rectum.* 2009;52:1462-9.
20. Roig JV, García-García A, Flors C, Castells P, Lledó S. Hábitos defecatorios en población laboral normal. *Rev Esp Enferm Dig.* 1993;84:224-30.
21. Jorge JMN, Wexner SD. Etiology and management of fecal incontinence. *Dis Colon Rectum.* 1993;36:77-97.
22. Milligan ETC, Morgan CN. Surgical anatomy of the anal canal with special reference to ano-rectal fistulae. *Lancet.* 1934;2:1150-213.
23. Toyonaga T, Matsushima M, Kiriu T, Sogawa N, Kanyama H, Matsumura N, et al. Factors affecting continence after fistulotomy for intersphincteric fistula-in-ano. *Int J Colorectal Dis.* 2007;22:1071-5.
24. Buchanan GN, Williams AB, Bartram CI, Halligan S, Nicholls RJ, Cohen CR. Potential clinical implications of direction of a trans-sphincteric anal fistula track. *Br J Surg.* 2003;90:1250-5.
25. Whiteford MH, 3rd Kilkenny J, Hyman N, Buie WD, Cohen J, Orsay C, et al. Standards Practice Task Force; American Society of Colon and Rectal Surgeons Practice parameters for the treatment of perianal abscess and fistula-in-ano (revised). *Dis Colon Rectum.* 2005;48:1337-42.
26. Williams JG, Farrands PA, Williams AB, Taylor BA, Lunniss PJ, Sagar PM, et al. The treatment of anal fistula: ACPGBI position statement. *Colorectal Dis.* 2007;9 Suppl. 4:18-50.
27. Kronborg O. To lay open or excise a fistula-in-ano: a randomized trial. *Br J Surg.* 1985;72:970.
28. Belmonte Montes C, Ruiz Galindo GH, Montes Villalobos JL, Decanini Terán C. Fistulotomía vs fistulectomía. Valoración ultrasonográfica de lesión al mecanismo del esfínter anal. *Rev Gastroenterol Mex.* 1999;64:167-70.
29. Bokhari S, Lindsey I. Incontinence following sphincter division for treatment of anal fistula. *Colorectal Dis.* 2010;12:e135-9.
30. Atkin GK, Martins J, Tozer P, Ranchod P, Phillips RK. For many high anal fistulas, lay open is still a good option. *Tech Coloproctol.* 2011;15:143-50.
31. Zbar AP, Ramesh J, Beer-Gabel M, Salazar R, Pescatori M. Conventional cutting vs internal anal sphincter-preserving seton for high trans-sphincteric fistula: a prospective randomized manometric and clinical trial. *Tech Coloproctol.* 2003;7:89-94.
32. Ho KS, Tsang C, Seow-Choen F, Ho YH, Tang CL, Heah SM, et al. Prospective randomised trial comparing ayurvedic cutting seton and fistulotomy for low fistula-in-ano. *Tech Coloproctol.* 2001;5:137-41.
33. Ritchie RD, Sackier JM, Hodde JP. Incontinence rates after cutting seton treatment for anal fistula. *Colorectal Dis.* 2009;11:564-71.
34. Hammond TM, Knowles CH, Porrett T, Lunniss PJ. The Snug Seton: short and medium term results of slow fistulotomy for idiopathic anal fistulae. *Colorectal Dis.* 2006;8:328-37.
35. Vial M, Parés D, Pera M, Grande L. Faecal incontinence after seton treatment for anal fistulae with and without surgical division of internal anal sphincter: a systematic review. *Colorectal Dis.* 2010;12:172-8.
36. Westerterp M, Volkers NA, Poolman RW, van Tets WF. Anal fistulotomy between Skylla and Charybdis. *Colorectal Dis.* 2003;5:549-51.
37. Ramanujam PS, Prasad ML, Abcarian H. The role of seton in fistulotomy of the anus. *Surg Gynecol Obstet.* 1983;157:419-22.
38. Williams JG, MacLeod CA, Rothenberger DA, Goldberg SM. Seton treatment of high anal fistulae. *Br J Surg.* 1991;78:1159-61.
39. Pearl RK, Andrews JR, Orsay CP, Weisman RI, Prasad ML, Nelson RL, et al. Role of the seton in the management of anorectal fistulas. *Dis Colon Rectum.* 1993;36:573-7.
40. Graf W, Pählman L, Ejerblad S. Functional results after seton treatment of high transsphincteric anal fistulas. *Eur J Surg.* 1995;161:289-91.
41. García-Aguilar J, Belmonte C, Wong DW, Goldberg SM, Madoff RD. Cutting seton versus two-stage seton fistulotomy in the surgical management of high anal fistula. *Br J Surg.* 1998;85:243-5.
42. Hasegawa H, Radley S, Keighley MR. Long-term results of cutting seton fistulotomy. *Acta Chir Jugosl.* 2000;47 Suppl. 1:19-21.
43. Chuang-Wei C, Chang-Chieh W, Cheng-Wen H, Tsai-Yu L, Chun-Che F, Shu-Wen J. Cutting seton for complex anal fistulas. *Surgeon.* 2008;6:185-8.
44. Lykke A, Steendahl J, Wille-Jørgensen PA. Treating high anal fistulae with slow cutting seton. *Ugeskr Laeger.* 2010;172:516-9.
45. Sjö Dahl R. Proposal: a score to select patients for fistulotomy. *Colorectal Dis.* 2010;12:487-9.
46. Galis-Rozen E, Tulchinsky H, Rosen A, Eldar S, Rabau M, Stepanski A, et al. Long-term outcome of loose seton for complex anal fistula: a two-centre study of patients with and without Crohn's disease. *Colorectal Dis.* 2010;12:358-62.
47. Noble G. New operation for complete laceration of the perineum designed for the purpose of eliminating infection from the rectum. *Trans Am Gynecol Soc.* 1902;27:357-63.
48. Laird DR. Procedures used in the treatment of complicated fistulas. *Am J Surg.* 1948;76:701-8.
49. Rothenberger DA, Chistenson CE, Balcos EG, Schottler JL, Nemer FD, Nivatvongs S, et al. Endorectal advancement flap for treatment of simple rectovaginal fistula. *Dis Colon Rectum.* 1982;25:297-300.
50. Lowry AC, Thorson AG, Rothenberger DA, Goldberg SM. Repair of simple rectovaginal fistula. Influence of previous repairs. *Dis Colon Rectum.* 1988;31:676-8.

51. De Parades V, Dahmani Z, Blanchard P, Zeitoun JD, Sultan S, Atienza P. Endorectal advancement flap with muscular plication: a modified technique for rectovaginal fistula repair. *Colorectal Dis.* 2011;13:921-5.
52. Del Pino A, Nelson RL, Pearl RK, Abcarian H. Island flap anoplasty for treatment of transsphincteric fistula-in-ano. *Dis Colon Rectum.* 1996;39:224-6.
53. Zimmerman DD, Briel JW, Gosselink MP, Schouten WR. Anocutaneous advancement flap repair of transsphincteric fistulas. *Dis Colon Rectum.* 2001;44:1474-80.
54. Soltani A, Kaiser AM. Endorectal advancement flap for cryptoglandular or Crohn's fistula-in-ano. *Dis Colon Rectum.* 2010;53:486-95.
55. Aguilar PS, Plasencia G, Hardy Jr TG, Hartmann RF, Stewart WR. Mucosal advancement in the treatment of anal fistula. *Dis Colon Rectum.* 1985;28:496-8.
56. Wedell J, Meier Zu Eissen P, Banzhaf G, Kleine L. Sliding flap advancement for the treatment of high level fistulae. *Br J Surg.* 1987;74:390-1.
57. Ozuner G, Hull TL, Cartmill J, Fazio VW. Long-term analysis of the use of transanal rectal advancement flaps for complicated anorectal/vaginal fistulas. *Dis Colon Rectum.* 1996;39:10-4.
58. Golub RW, Wise Jr WE, Kerner BA, Khanduja KS, Aguilar PS. Endorectal mucosal advancement flap: the preferred method for complex cryptoglandular fistula-in-ano. *J Gastrointest Surg.* 1997;1:487-91.
59. Miller GV, Finan PJ. Flap advancement and core fistulectomy for complex rectal fistula. *Br J Surg.* 1998;85:108-10.
60. Ortiz H, Marzo J. Endorectal flap advancement repair and fistulectomy for high trans-sphincteric and suprasphincteric fistulas. *Br J Surg.* 2000;87:1680-3.
61. Mizrahi N, Wexner SD, Zmora O, Silva GD, Efron J, Weiss EG, et al. Endorectal advancement flap. *Dis Colon Rectum.* 2002;45:1616-21.
62. Sonoda T, Hull T, Piedmonte MR, Fazio VW. Outcomes of primary repair of anorectal and rectovaginal fistulas using the endorectal advancement flap. *Dis Colon Rectum.* 2002;45:1622-8.
63. Mitalas LE, Gosselink MP, Zimmerman DDE, Schouten WR. Repeat transanal advancement flap repair: impact on the overall healing rate of high transsphincteric fistulas and on fecal continence. *Dis Colon Rectum.* 2007;50:1508-11.
64. Uribe N, Millán M, Mínguez M, Ballester C, Asencio F, Sanchiz V, et al. Clinical and manometric results of endorectal advancement flaps for complex anal fistula. *Int J Colorectal Dis.* 2007;22:259-64.
65. Ortiz H, Marzo M, De Miguel M, Ciga MA, Oteiza F, Armendariz P. Length of follow-up after fistulotomy and fistulectomy associated with endorectal advancement flap repair for fistula in ano. *Br J Surg.* 2008;95:484-7.
66. Abbas MA, Lemus-Rangel R, Hamadani A. Long-term outcome of endorectal advancement flap for complex anorectal fistulae. *Am Surg.* 2008;74:921-4.
67. Pinto RA, Peterson TV, Shawki S, Davila GW, Wexner SD. Are there predictors of outcome following rectovaginal fistula repair. *Dis Colon Rectum.* 2010;53:1240-7.
68. Ellis CN, Clark S. Effect of tobacco smoking on advancement flap repair of complex anal fistulas. *Dis Colon Rectum.* 2007;50:459-63.
69. Ellis CN, Clark S. Fibrin glue as an adjunct to flap repair of anal fistulas: a randomized, controlled study. *Dis Colon Rectum.* 2006;49:1736-40.
70. Alexander SM, Mitalas LE, Gosselink MP, Oom DMJ, Zimmerman DDE, Schouten WR. Obliteration of the fistulous tract with BioGlue adversely affects the outcome of transanal advancement flap repair. *Tech Coloproctol.* 2008;12:225-8.
71. Dubsy PC, Stift A, Friedl J, Teleky B, Herbst F. Endorectal advancement flaps in the treatment of high anal fistula of cryptoglandular origin: full-thickness vs mucosal-rectum flaps. *Dis Colon Rectum.* 2008;51:852-7.
72. Mitalas LE, Van Wijk JJ, Gosselink MP, Doornebosch P, Zimmerman DD, Schouten WR. Seton drainage prior to transanal advancement flap repair: useful or not. *Int J Colorectal Dis.* 2010;25:1499-502.
73. Zimmerman DD, Gosselink MP, Hop WC, Darby M, Briel JW, Schouten WR. Impact of two different types of anal retractor on fecal continence after fistula repair: a prospective, randomized, clinical trial. *Dis Colon Rectum.* 2003;46:1674-9.
74. Uribe Quintana N, Aguado Pérez M, Mínguez Pérez M, Ortiz Tarín I, Millán Scheiding M, Martín Diéguez MC, et al. Impacto de los colgajos transanales de avance en la continencia anal. *Cir Esp.* 2009;86:224-9.
75. Roig JV, García-Armengol J, Jordán JC, Moro D, García-Granero E, Alós R. Fistulectomy and sphincteric reconstruction for complex cryptoglandular fistulas. *Colorectal Dis.* 2010;12:e145-52 [online].
76. Stelzner F. Complex trauma of the perineum, especially the anorectal continence organ Experience and results in 27 patients 1956-1988. *Langenbecks Arch Chir.* 1990;375:55-63.
77. Parkash S, Lakshmiratan V, Gajendran V. Fistula-in-ano: treatment by fistulectomy, primary closure and reconstitution. *Aust N Z J Surg.* 1985;55:23-7.
78. Lux N, Athanasiadis S. Functional results following fistulectomy with primary muscle suture in high anal fistula. A prospective clinical and manometric study. *Chirurg.* 1991;62:36-41.
79. Christiansen J, Ronholt C. Treatment of recurrent high anal fistula by total excision and primary sphincter reconstruction. *Int J Colorectal Dis.* 1995;10:207-9.
80. Lewis A. Core out. In: Phillips RKS, Lunniss PJ, editors. *Anal fistula. Surgical evaluation and management* Londres: Chapman & Hall; 1996; p. 81-6.
81. Roig JV, García-Armengol J, Jordán J, Alós R, Solana A. Immediate reconstruction of the anal sphincter after fistulectomy in the management of complex anal fistulas. *Colorectal Dis.* 1999;1:137-40.
82. Pérez F, Arroyo A, Serrano P, Candela F, Sánchez A, Calpena R. Fistulotomy with primary sphincter reconstruction in the management of complex fistula-in-ano: prospective study of clinical and manometric results. *J Am Coll Surg.* 2005;200:897-903.
83. Jivapaisarnpong P. Core out fistulectomy, anal sphincter reconstruction and primary repair of internal opening in the treatment of complex anal fistula. *J Med Assoc Thai.* 2009;92:638-42.
84. Hull TL, El-Gazzaz G, Gurland B, Church J, Zutshi M. Surgeons should not hesitate to perform episiotomy for rectovaginal fistula secondary to cryptoglandular or obstetrical origin. *Dis Colon Rectum.* 2011;54:54-9.
85. Pérez F, Arroyo A, Serrano P, Sánchez A, Candela F, Pérez MT, et al. Randomized clinical and manometric study of advancement flap versus fistulotomy with sphincter reconstruction in the management of complex fistula-in-ano. *Am J Surg.* 2006;192:34-40.
86. Matos D, Lunniss PJ, Phillips RK. Total sphincter conservation in high fistula in ano: results of a new approach. *Br J Surg.* 1993;80:802-4.
87. Rojanasakul A, Pattanaarun J, Sahakitrungruang C, Tantiphlachiva K. Total anal sphincter saving technique for fistula-in-ano; the ligation of intersphincteric fistula tract. *J Med Assoc Thai.* 2007;90:581-6.
88. Rojanasakul A. LIFT procedure: a simplified technique for fistula-in-ano. *Tech Coloproctol.* 2009;13:237-40.

89. Shanwani A, Nor AM, Amri N. Ligation of the intersphincteric fistula tract (LIFT): a sphincter-saving technique for fistula-in-ano. *Dis Colon Rectum*. 2010;53:39-42.
90. Bleier JI, Moloo H, Goldberg SM. Ligation of the intersphincteric fistula tract: an effective new technique for complex fistulas. *Dis Colon Rectum*. 2010;53:43-6.
91. Aboulian A, Kaji AH, Kumar RR. Early result of ligation of the intersphincteric fistula tract for fistula-in-ano. *Dis Colon Rectum*. 2011;54:289-92.
92. Ooi K, Skinner I, Croxford M, Faragher I, McLaughlin S. Managing fistula-in-ano with ligation of the intersphincteric fistula tract (LIFT) procedure: The Western Hospital experience. *Colorectal Dis*. 2011. doi: 10.1111/j.1463-1318.2011.02723.x [Aug 11; Epub ahead of print].
93. Ellis CN. Outcomes with the use of bioprosthetic grafts to reinforce the ligation of the intersphincteric fistula tract (BioLIFT procedure) for the management of complex anal fistulas. *Dis Colon Rectum*. 2010;53:1361-4.
94. Hammond TM, Grahn MF, Lunniss PJ. Fibrin glue in the management of anal fistulae. *Colorectal Dis*. 2004;6:308-19.
95. Reznick RK, Bailey HR. Closure of the internal opening for treatment of complex fistula-in-ano. *Dis Colon Rectum*. 1988;31:116-8.
96. Venkatesh KS, Ramanujam P. Fibrin glue application in the treatment of recurrent anorectal fistulas. *Dis Colon Rectum*. 1999;42:1136-9.
97. Cintron JR, Park JJ, Orsay CP, Pearl RK, Nelson RL, Sone JH, et al. Repair of fistulae-in-ano using fibrin adhesive. Long-term follow up. *Dis Colon Rectum*. 2000;43:944-50.
98. Patrlj L, Kocman B, Martinac M, Jadrijevic S, Sosa T, Sebecic B, et al. Fibrin glue-antibiotic mixture in the treatment of anal fistulae: experience with 69 cases. *Digestive Surg*. 2000;17:77-80.
99. Lindsey I, Smilgin-Humphreys MM, Cunningham C, Mortensen NJ, George BD. A randomized, controlled trial of fibrin glue vs conventional treatment for anal fistula. *Dis Colon Rectum*. 2002;45:1608-15.
100. Sentovich S. Fibrin glue for anal fistulae. Long term results. *Dis Colon Rectum*. 2003;46:498-502.
101. Buchanan GN, Bartram CI, Phillips RKS, Gould SWT, Halligan S, Rockall TA, et al. The efficacy of fibrin sealant in the management of complex anal fistula: a prospective trial. *Dis Colon Rectum*. 2003;46:1167-74.
102. Loungnarath J, Dietz DW, Mutch MG, Birnbaum EH, Kodner JJ, Fleshman JW. Fibrin glue treatment of complex anal fistula has low success rate. *Dis Colon Rectum*. 2004;47:432-6.
103. Singer M, Cintron J, Nelson R, Orsay C, Bastawron A, Pearl R, et al. Treatment of fistulas-in-ano with fibrin sealant in combination with intra-adhesive antibiotics and/or surgical closure of the internal fistula opening. *Dis Colon Rectum*. 2005;48:799-808.
104. Barillari P, Basso L, Larcinese A, Gozzo P, Indinnimeo M. Cyanoacrylate glue in the treatment of ano-rectal fistulas. *Int J Colorectal Dis*. 2006;21:791-4.
105. De la Portilla F, Rada R, León E, Cisneros N, Maldonado VH, Espinosa E. Evaluation of the use of BioGlue (R) in the treatment of high anal fistulas: preliminary results of a pilot study. *Dis Colon Rectum*. 2007;50:218-22.
106. De la Portilla F, Rada R, Vega J, Cisneros N, Maldonado VH, Sánchez-Gil JM. Long-term results change conclusions on BioGlue in the treatment of high transsphincteric anal fistulas. *Dis Colon Rectum*. 2010;53:1220-1.
107. Damin DC, Rosito MA, Contu PC, Tarta C. Fibrin glue in the management of complex anal fistula. *Arq Gastroenterol*. 2009;14:300-3.
108. Queralto M, Portier G, Bonnaud G, Chotard JP, Cabarrot P, Lazorthes F. Efficacy of synthetic glue treatment of high cryptoglandular fistula-in-ano. *Gastroenterol Clin Biol*. 2010;34:477-82.
109. Altomare DF, Greco VJ, Tricomi N, Arcanà F, Mancini S, Rinaldi M, et al. Seton or glue for trans-sphincteric anal fistulae: a prospective randomized crossover clinical trial. *Colorectal Dis*. 2011;13:82-6.
110. Abbas MA, Tejirian T. Bioglue for the treatment of anal fistula is associated with acute anal sepsis. *Dis Colon Rectum*. 2008;51:1155-6.
111. Johnson EK, Gaw JU, Armstrong DN. Efficacy of anal fistula plug vs fibrin glue in closure of anorectal fistulas. *Dis Colon Rectum*. 2006;49:371-6.
112. Champagne BJ, O'Connor LM, Ferguson M, Orangio GR, Schertzer ME, Armstrong DN. Efficacy of anal fistula plug in closure of cryptoglandular fistulas: long-term follow-up. *Dis Colon Rectum*. 2006;49:1817-21.
113. Van Koperen PJ, D'Hoore A, Wolthuis AM, Bemelman WA, Slors JF. Anal fistula plug for closure of difficult anorectal fistula: a prospective study. *Dis Colon Rectum*. 2007;50:2168-72.
114. Schwandner O, Stadler F, Dietl O, Wirsching RP, Fuerst A. Initial experience on efficacy in closure of cryptoglandular and Crohn's transsphincteric fistulas by the use of the anal fistula plug. *Int J Colorectal Dis*. 2008;23:319-24.
115. Christoforidis D, Etzioni DA, Goldberg SM, Madoff RD, Mellgren A. Treatment of complex anal fistulas with the collagen fistula plug. *Dis Colon Rectum*. 2008;51:1482-7.
116. Ky AJ, Sylla P, Steinhagen R, Steinhagen E, Khaitov S, Ly EK. Collagen fistula plug for the treatment of anal fistulas. *Dis Colon Rectum*. 2008;51:838-43.
117. Thekkinkattil D, Botterill I, Ambrose S, Lundby L, Sagar P, Buntzen S, et al. Efficacy of the anal fistula plug in complex anorectal fistulae. *Colorectal Dis*. 2009;11:584-7.
118. Garg P. Flaps, glues and plugs – a view from the East. *Semin Colon Rectal Surg*. 2009;20:52-7.
119. Christoforidis D, Pieh MC, Madoff RD, Mellgren AF. Treatment of transsphincteric anal fistulas by endorectal advancement flap or collagen fistula plug: a comparative study. *Dis Colon Rectum*. 2009;52:18-22.
120. Chung W, Kazemi P, Ko D, Sun C, Brown CJ, Raval M, et al. Anal fistula plug and fibrin glue versus conventional treatment in repair of complex anal fistulas. *Am J Surg*. 2009;197:604-8.
121. Ortiz H, Marzo J, Ciga MA, Oteiza F, Armendáriz P, de Miguel M. Randomized clinical trial of anal fistula plug versus endorectal advancement flap for the treatment of high cryptoglandular fistula in ano. *Br J Surg*. 2009;96:608-12.
122. Wang JY, Garcia-Aguilar J, Sternberg JA, Abel ME, Varma MG. Treatment of transsphincteric anal fistulas: are fistula plugs an acceptable alternative. *Dis Colon Rectum*. 2009;52:692-7.
123. El-Gazzaz G, Zutshi M, Hull T. A retrospective review of chronic anal fistulae treated by anal fistulae plug. *Colorectal Dis*. 2010;12:442-7.
124. Ellis CN, Rostas JW, Greiner FG. Long-term outcomes with the use of bioprosthetic plugs for the management of complex anal fistulas. *Dis Colon Rectum*. 2010;53:798-802.
125. Lenisa L, Espin-Basany E, Rusconi A, Mascheroni L, Escoll-Rufino J, Lozoya-Trujillo R, et al. Anal fistula plug is a valid alternative option for the treatment of complex anal fistula in the long term. *Int J Colorectal Dis*. 2010;25:1487-93.
126. Van Koperen PJ, Bemelman WA, Gerhards MF, Janssen LW, Van Tets WF, Van Dalsen AD, et al. The anal fistula plug treatment compared with the mucosal advancement flap for cryptoglandular high transsphincteric perianal fistula: a double-blinded multicenter randomized trial. *Dis Colon Rectum*. 2011;54:387-93.

127. Garg P, Song J, Bhatia A, Kalia H, Menon GR. The efficacy of anal fistula plug in fistula-in-ano: a systematic review. *Colorectal Dis.* 2010;12:965-70.
128. McGee MF, Champagne BJ, Stulberg JJ, Reynolds H, Marderstein E, Delaney CP. Tract length predicts successful closure with anal fistula plug in cryptoglandular fistulas. *Dis Colon Rectum.* 2010;53:1116-20.
129. Corman ML. The Surgisis AFP anal fistula plug: report of a consensus conference. *Colorectal Dis.* 2008;10:17-20.
130. Mitalas LE, van Onkelen RS, Gosselink MP, Zimmerman DD, Schouten WR. The anal fistula plug as an adjunct to transanal advancement flap repair. *Dis Colon Rectum.* 2010;53:1713.
131. Christoforidis D. Who benefits from the anal fistula plug. *Dis Colon Rectum.* 2010;53:1105-6.
132. Gajsek U, McArthur DR, Sagar PM. Long-term efficacy of the button fistula plug in the treatment of ileal pouch-vaginal and Crohn's-related rectovaginal fistulas. *Dis Colon Rectum.* 2011;54:999-1002.
133. Himpson RC, Cohen CR, Sibbons P, Phillips RK. An experimentally successful new sphincter-conserving treatment for anal fistula. *Dis Colon Rectum.* 2009;52:602-8.
134. Hammond TM, Porrett TR, Scott SM, Williams NS, Lunniss PJ. Management of idiopathic anal fistula using cross-linked collagen: a prospective phase 1 study. *Colorectal Dis.* 2011;13:94-104.
135. García-Olmo D, García-Arranz M, García LG, Cuellar ES, Blanco IF, Prianes LA, et al. Autologous stem cell transplantation for treatment of rectovaginal fistula in perianal Crohn's disease: a new cell-based therapy. *Int J Colorectal Dis.* 2003;18:451-4.
136. García-Olmo D, García-Arranz M, Herreros D, Pascual I, Peiro C, Rodríguez-Montes JA. A phase I clinical trial of the treatment of Crohn's fistula by adipose mesenchymal stem cell transplantation. *Dis Colon Rectum.* 2005;48:1416-23.
137. García-Olmo D, Herreros D, Pascual I, Pascual JA, Del-Valle E, Zorrilla J, et al. Expanded adipose-derived stem cells for the treatment of complex perianal fistula: a phase II clinical trial. *Dis Colon Rectum.* 2009;52:79-86.
138. Meinero G. Video Assisted Anal Fistula Treatment. (V.A.A.F.T.) [accessed 03.09.11]. <http://www.piercarlomeinero.it/it/la-vaaft.html>
139. Christen AG, Christen JA, Van Butchell M. (1735-1814): the eccentric, kook dentist of old London. *J Hist Dent.* 1999;47:99-104.
140. Jacob TJ, Perakath B, Keighley MR. Surgical intervention for anorectal fistula. *Cochrane Database Syst Rev.* 2010;12:CD0006319.
141. Casal E, de San Ildefonso A, Sánchez J, Facal C, Pampin J. Fístula de ano de origen criptoglandular. Opciones terapéuticas. *Cir Esp.* 2005;78:28-33.
142. Parés D. Pathogenesis and treatment of fistula in ano. *Br J Surg.* 2011;98:2-3.
143. Wong S, Solomon M, Crowe P, Ooi K. Cure, continence and quality of life after treatment for fistula-in-ano. *ANZ J Surg.* 2008;78:675-82.
144. Ellis CN. Sphincter-preserving fistula management: what patients want. *Dis Colon Rectum.* 2010;53:1652-5.
145. Lockhart Mummery JP. Discussion on fistula-in-ano. *Proc Roy Soc Med.* 1929;22:1331-41.