



Original Article

Pancreatic Metastases Due to Renal Carcinoma: Our Cases and a Literature Review[☆]

Izaskun Markinez,^{*} Raúl Jiménez, Inmaculada Ruiz, Eloisa Villarreal, Aintzane Lizarazu, Nerea Borda, Xabier Arteaga, Miguel Ángel Medrano, Esther Guisasola, Adolfo Beguiristain, José María Enríquez-Navascués

Servicio de Cirugía General y Digestiva, Hospital Donostia, San Sebastián, Spain

ARTICLE INFO

Article history:

Received 19 February 2012

Accepted 14 July 2012

Available online 22 June 2013

Keywords:

Pancreatic metastases

Renal cell carcinoma

Pancreatic surgery

A B S T R A C T

Objective: To analyze the cases of pancreatic metastases due to renal carcinoma operated on in our hospital between the years 2000 and 2011.

Material and methods: A retrospective study using the variables of 8 patients who were subjected to surgery of pancreatic metastases due to renal carcinoma, and a comparison of our data with those from the literature.

Results: The incidence of metastatic disease of the pancreas due to renal carcinoma in our series was 1.2%. All the metastases were metachronous, with both sexes being affected equally. The mean time between resection of the renal tumor and the diagnosis of the metastasis was 12.42 years (range: 1.62–30.13 years). The therapeutic approach to the pancreatic lesions was surgical in all cases. Seven patients are currently still alive.

Conclusion: Metastatic disease of the pancreas due to renal carcinoma is uncommon (1%–2.8%). The interval between the primary resection and the metastasis can be quite long. Pancreatic metastasis must always be suspected in patients who present with a pancreatic mass and a history of renal carcinoma. Aggressive surgical treatment is recommended in selected cases. The surgery in these cases improves survival and the quality of life.

© 2012 AEC. Published by Elsevier España, S.L. All rights reserved.

Metástasis pancreáticas por carcinoma renal. Nuestra casuística y revisión de la literatura

R E S U M E N

Objetivo: Analizar los casos de metástasis pancreáticas por carcinoma renal intervenidos en nuestro Hospital entre los años 2000 y 2011.

Material y métodos: Estudio retrospectivo donde se recogen diferentes variables de 8 pacientes con metástasis pancreáticas por carcinoma renal intervenidos. Comparación de nuestros datos con los de la literatura.

Palabras clave:

Metástasis pancreáticas

Carcinoma de células renales

Cirugía pancreática

[☆] Please cite this article as: Markinez I, et al. Metástasis pancreáticas por carcinoma renal. Nuestra casuística y revisión de la literatura. Cir Esp. 2013;91:90–5.

^{*} Corresponding author.

E-mail address: ikur6@hotmail.com (I. Markinez).

2173-5077/\$ – see front matter © 2012 AEC. Published by Elsevier España, S.L. All rights reserved.

Resultados: La enfermedad metastásica del páncreas por carcinoma renal en nuestra serie ha sido de 1.2%. Todas las metástasis han sido metacrónicas. La afectación por sexo ha sido igual. El tiempo medio entre la resección del tumor renal y el diagnóstico de las metástasis ha sido de 12.42 años (rango: 1.62-30.13 años). La actitud terapéutica ante las lesiones pancreáticas ha sido quirúrgica en todos los casos. Hasta la fecha, 7 pacientes continúan vivos.

Conclusión: La enfermedad metastásica del páncreas por carcinoma renal es poco frecuente (1-2.8%). El intervalo entre la resección primaria y las metástasis puede ser bastante largo. Siempre debe sospecharse metástasis pancreática en los pacientes que presenten masa pancreática e historia de carcinoma renal. Se recomienda un tratamiento quirúrgico agresivo en casos seleccionados. La cirugía en estos casos mejora la supervivencia y la calidad de vida.

© 2012 AEC. Publicado por Elsevier España, S.L. Todos los derechos reservados.

Introduction

Pancreatic metastases of any primary tumor are rare and represent between 2% and 5% of pancreatic tumors. Renal cell carcinoma as a primary tumor is uncommon, representing between 1% and 2.8% of pancreatic metastases.¹⁻¹⁰

Due to the rarity and peculiarity of these pancreatic lesions, we decided to analyze the cases of pancreatic metastasis from renal carcinoma treated in our hospital between 2000 and 2011, and to analyze the frequency and characteristics compared with the literature.

Materials and Methods

We present a retrospective study of patients with a history of renal neoplasm that underwent pancreatic surgery from January 2000 to March 2011. To identify these patients, the diagnoses in the Hospital database were reviewed. We also reviewed patients with previous renal tumors treated by nephrectomy. A total of 11 patients were identified, 3 of whom were excluded because the pancreatic tumor was the primary tumor (adenocarcinoma or endocrine tumor) and not metastasis of the renal cell carcinoma.

Different variables were collected, including patient variables as well as those referring to the renal and pancreatic tumors they presented (Table 1). Due to the fact that some of the patients had undergone surgery many years beforehand and/or in other centers, we could not obtain all the renal tumor data.

Results

In our center during the period selected, 502 malignant renal neoplasms were treated surgically; the most frequent histologic type was clear cell (402 patients [80.1%]). Out of the 502 renal neoplasms, 6 (1.2%) had metastasized in the pancreas. Another 2 patients in the series were operated on for renal neoplasia in other centers, so we cannot add them to this percentage, although their data are included since their surgeries for pancreatic metastasis were done at our center. All the pancreatic metastases were metachronous (Table 1).

Distribution was equal in both sexes. Mean age at the time of the renal neoplasia was 52.87 years (range 40-62).

As a primary tumor, the 8 patients had presented a clear cell renal carcinoma. Half of the patients presented left kidney affection, while the other half presented right renal tumors.

The average time between renal tumor resection and the diagnosis of pancreatic metastases was 4533.75 days, or 12.42 years (range: 1.62-30.13 years), and the latest presentation of the series was more than 30 years after the nephrectomy.

The diagnosis of the pancreatic lesions was made during follow-up after nephrectomy in 3 patients (37.5%), due to the appearance of symptoms in 3 (37.5%) (abdominal pain in 2 and debut of diabetes mellitus with diabetic decompensation in another), in a study for another cause (renal colic) in one patient (12.5%) and as an intraoperative finding in another (12.5%) (Suspicion of left suprarenal metastasis; the pathology study reported pancreatic metastasis). The most widely used imaging methods in the diagnosis of the pancreatic lesions were ultrasound and CT. The diagnosis was not confirmed histologically by FNA prior to surgery in any case. The lesions were located in the head, body and tail of the pancreas (Figs. 1 and 2).

The therapeutic approach for the pancreatic lesions was surgery in all cases because all the lesions were resectable (Table 1). The intervention performed most frequently was total pancreatectomy with splenectomy and cholecystectomy (n=4, 50%) (in one, partial left nephrectomy was also performed due to tumor invasion). In one of the patients, an atypical resection was performed, thinking that there was a left suprarenal metastasis. The same surgical team performed all the interventions. No new pancreatic recurrences were detected.

All the histologic tests demonstrated that the pancreatic lesions corresponded with metastases of clear cell renal carcinoma. Five patients (62.5%) presented single pancreatic metastases, while the other 3 (37.5%) presented multiple lesions, as seen on pre-operative imaging tests.

None of the patients received adjuvant or neoadjuvant therapy for the pancreatic metastases.

As for postoperative morbidity, one patient presented hemorrhage of the hepaticojejunal anastomoses on the tenth post-op day, requiring transfusion of platelet concentrates and plasma (grade II of the Clavien classification). Another patient presented pseudomembranous colitis with acute renal

Table 1 – Characteristics of the Patients Diagnosed With Pancreatic Metastases of Renal Cell Carcinoma.

Patient	1	2	3	4	5	6	7	8
Sex	Male	Female	Male	Female	Male	Female	Female	Male
Age (at kidney SI)	59	59	62	56	56	40	49	42
Personal history	HC	HC		AHT	AHT	HC	AHT, DMII	AHT, AMI, HC
Date of renal cancer SI	24/02/2003	20/06/1996	07/07/2005	09/08/1998	1/06/2005	1/06/1995	1/06/1987	1/06/1981
Renal cancer stage	III		III	II	III			
Affected kidney	Right	Right	Right	Left	Left	Left	Left	Right
Date of pancreatic MET diagnosis	26/02/2008	17/07/2003	16/02/2007	25/02/2010	09/11/2010	24/02/2010	5/03/2011	11/07/2011
Days/years between kidney SI and diagnosis of pancreatic MET	1829/5.01	2584/7.08	590/1.62	4219/11.56	1988/5.45	5383/14.75	8679/23.78	10 998/30.1
Diagnosis of pancreatic MET	During follow-up	During follow-up	During surgery	Due to symptoms (abdominal pain and distension)	Due to symptoms (DM)	During follow-up	Due to symptoms (abdominal pain and vomiting)	Other cause (renal colic)
Location of pancreatic MET	Head and body	Head and body	Unknown	Head	Head	Body	Body	Tail
Date of SI for pancreatic MET	20/06/2008	19/11/2003	13/02/2007	03/05/2010	18/01/2011	16/03/2010	15/04/2011	16/09/2011
Type of SI for pancreatic MET	TP+partial left nephrectomy+SP+Chol	TP+SP+Chol	Atypical resection	TP+SP+Chol	TP+SP+Chol	TP+SP+Chol	TP+SP	Distal pancreatectomy+SP
Size of pancreatic MET, cm	1.5 and 1	2 and 1	0.9	1 (the largest of 5 nodules)	3.9	3	2	4
Single or multiple MET	Multiple	Multiple	Single	Multiple	Single	Single	Single	Single
Morbidity (Claviengrade)	0	0	V	II	IVb	0	0	0
Evolution	Alive	Alive	Dead	Alive	Alive	Alive	Alive	Alive
Months of survival	40	95	56	17	9	19	6	1

Chol: cholecystectomy; DM: diabetes mellitus; SP: splenectomy; HC: hypercholesterolemia; AHT: arterial hypertension; AMI: acute myocardial infarction; SI: surgical intervention; MET: metastasis; TP: total pancreatectomy.

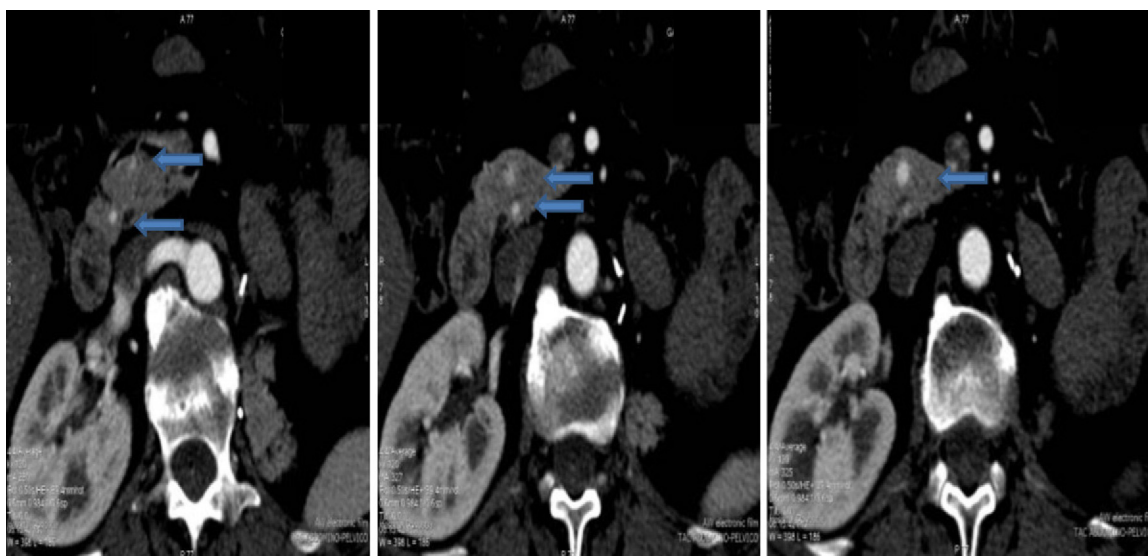


Fig. 1 – Multiple pancreatic metastases.

failure and compartment syndrome requiring surgery to reduce intra-abdominal pressure (placement of vacuum system), hemofiltration and tracheotomy (Clavien grade ivb). One patient died after an atypical resection due to a torpid post-operative course (Clavien grade v). The remaining patients presented no complications. To date, 7 patients are still alive (87.5%) and only one has died (12.5%).

During the follow-up after pancreatic lesion resection, 3 patients presented metastasis in other organs: one in the contralateral kidney requiring tumorectomy (nearly 7 years after pancreatic resection); one in the thyroid, treated with thyroidectomy (4 months after pancreatic intervention); and one in the bronchus of the left lower lobe (2 months after pancreatic intervention), who is currently being treated with chemotherapy (sunitinib) and bronchoscopic ablation. The remaining 4 patients (since one had died during post-op) have

not presented evidence of disease (disease-free survival: 50%). Mean follow-up was 2.56 years (range: 0.11–7.94 years).

Patient follow-up after the pancreatic intervention included periodic patient visits to our outpatient clinic.

Discussion

Pancreatic metastases of any primary tumor are rare and represent between 2% and 5% of pancreatic tumors. The most frequent primary tumors are lung, colon, breast, skin and brain. Metastatic disease of the pancreas due to renal cell carcinoma is rare (1%–2.8%), since the most frequent places for renal carcinoma metastasis are: the lungs (50%–60%), bones (30%–40%), liver (30%–40%), suprarenals and brain (5%).^{1,2,10} The percentage of pancreatic metastases due to renal tumors reported in our series is 1.2%, similar to what has been described in the literature.

Renal clear cell carcinoma is the most common histological type within the renal cell carcinomas, representing 70%–80%; in our series, the percentage of clear cell carcinomas was 80.1%.

The presentation of pancreatic metastases of renal carcinoma may be synchronous or metachronous, with cases being reported some 27 years after nephrectomy.^{1–10} In our series, all the metastases were metachronous, and the latest presentation of the series was more than 30 years after nephrectomy (range: 1.62–30.1 years). 85% of the recurrences occur within the first 3 years after nephrectomy.^{1,2} It is, therefore, extremely important to take into account the medical history as these patients can present metastasis at any time, in any location and with different symptoms. Given the suspicion for metastatic renal disease, imaging studies are essential and the confirmation diagnosis should be done in accordance with the location.¹

The mean age of our patients was 52.87, which is similar to the results of other authors, although somewhat younger (e.g. 56, 63.5, 62.2).⁹

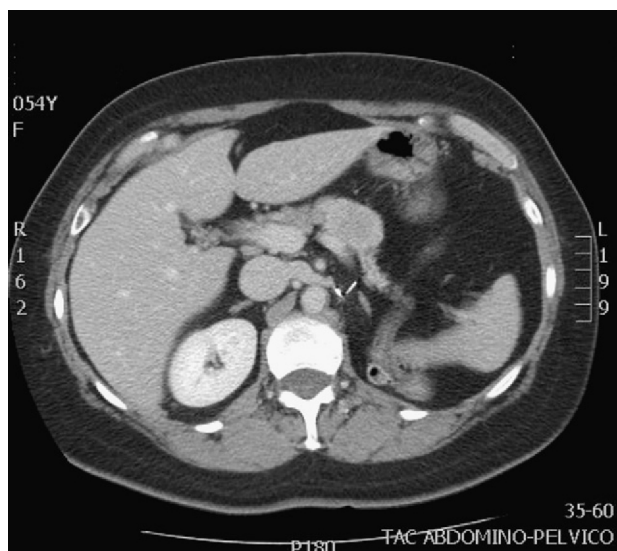


Fig. 2 – Single pancreatic metastasis.

The means of extension of renal cell carcinoma to the pancreas are controversial; it may be hematogenous or lymphatic, and direct extension to the pancreas is thought to be unusual.^{2,3,7} Renal carcinoma cells have an affinity for the pancreatic parenchyma and they can metastasize in the pancreas without there being metastasis in other organs.^{5,7,8} Due to this affinity, there may be recurrences after previous pancreatic resection.⁵

No relationship has been found between the location of the pancreatic metastases and the location of the primary renal carcinoma. The tumors on the left side do not metastasize more frequently in the tail of the pancreas, nor do the tumors on the right side metastasize more frequently in the head of the pancreas.^{3,7}

The presentation is usually as single, asymptomatic metastases. If there are symptoms, these may be very diverse and indistinguishable from other types of pancreatic cancer.^{1,2,4,7,9} In our cases, 5 patients (62.5%) presented single metastasis and 3 presented multiple metastases (37.5%); only 3 patients (37.5%) presented symptoms.

The multifocal nature of pancreatic metastases has been reported to range from 20% to 45%.⁷ Our percentage is 37.5%.

As for their diagnosis, metastases are usually diagnosed during follow-up studies. Pancreatic metastasis should always be suspected in patients who present a pancreatic mass and history of renal carcinoma.^{4,5,7,10} Diagnostic methods aid in making the differential diagnosis, which should include primary adenocarcinoma of the pancreas, neuroendocrine tumor, etc.^{2,6}

Ultrasound is more sensitive for detecting small pancreatic metastatic foci than CT.² The lesions appear hypoechogenic when compared with the pancreatic parenchyma. Abdominal CT can be useful for the differential diagnosis of pancreatic lesions: in premature phases, after the administration of intravenous contrast, these lesions are seen as hypervascular in the pancreatic parenchyma, unlike primary adenocarcinoma of the pancreas, which is typically hypovascular. These findings are not pathognomonic since endocrine pancreatic tumors also appear as hypervascular lesions.^{1,2,4-7,10} The use of MRI for the diagnosis of these lesions is increasing.⁷ Standard imaging methods (CT, MRI) cannot provide an adequate differential diagnosis.⁷ The role of PET-CT has yet to be defined, but it can be useful for ruling out unsuspected metastasis.^{4,5} Some authors, given the diagnostic difficulties in certain cases, use FNA. This has its risks and disadvantages, which is why other authors make the diagnosis after surgical resection of the surgical resection.^{4,7} In none of the cases presented FNA was used for the diagnosis.

In selected patients, when the primary tumor is controlled, the pancreas is the only organ affected by metastasis and the lesion or lesions are resectable, aggressive surgical treatment is recommended as long as there are no comorbidities that contraindicate it. Surgery in these cases improves survival and quality of life, especially in patients with asymptomatic metastases that occur after a disease-free period of more than 2 years.^{1,3-9} Aggressive surgical management for single pancreatic metastasis of renal cell carcinoma is justified. In contrast, in the case of multiple metastases, this is more controversial. Some authors consider that if there are multiple metastases it is because the disease is disseminated; nevert-

theless, as there is no other treatment, surgery is used. In conclusion, surgery is done as long as the disease is not locally unresectable, there is no comorbidity that contraindicates it and there is no unresectable extra-pancreatic disease.^{1-3,5,7}

All our patients presented resectable lesions, and the pancreas was the only organ affected by metastasis, so they were therefore treated surgically. The type of pancreatic resection is conditioned by the location of the lesions and the need to obtain free margins with preservation of the exocrine and endocrine functions of the pancreas.^{2,4,5,7} All the metastases seen on radiography and during surgical exploration should be resected. There is no need for radical lymph node dissection as the literature indicates that lymph node affection in pancreatic metastatic disease is very rare.^{1-3,8} In our case, only one patient with multifocal disease presented lymph node affection.

There are many articles that suggest that previous resection of renal carcinoma metastasis in other organs, such as the thyroid, suprarenal glands or lungs, should not rule out aggressive treatment of the secondary pancreatic metastases after having confirmed that it is the only organ with disease relapse.^{7,8}

Chemotherapy, hormone therapy and radiotherapy have not been demonstrated to be effective for primary renal tumors or their metastases. In recent years, promising results have been seen in phase III assays with sunitinib, sorafenib, temsirolimus and bevacizumab.^{2,3,7}

The resection of pancreatic metastases by other, non renal cancers has a poor prognosis as it is a sign of disseminated metastatic disease. Contrarily, survival after the resection of pancreatic metastases of renal cell carcinoma is clearly superior^{7,8}: the 5-year survival rate in patients with pancreatic metastases after resection is very variable, from 29% to 88% depending on the series.^{2,3,5-7} Survival is better than that of primary pancreatic tumors.^{1,2,7} In our series, there was only one death, 3 months after the procedure, due to surgical morbidity; the remaining patients are still alive (87.5%). Disease-free survival is 50%. Survival after the pancreatic resection is 30.37 months, although the patients present different follow-up times (0.11-7.94 years).

Factors associated with a favorable prognosis include a prolonged disease-free period, a single metastasis with central necrosis and complete resection with histologically negative margins. Others have reported that the tumor grade of pancreatic metastases correlates with the tumor grade of the primary renal tumor and that tumor grade is a predictor for survival, with a mean survival of 42 months for grade 2 cancer and 10 months for grade 3.⁷

Conclusions

Pancreatic metastases of any primary tumor are rare. Pancreatic metastasis should always be suspected in patients who present a pancreatic mass and history of renal cell carcinoma. The interval between the primary resection and metastasis can be quite long. Patients may or may not present symptoms, which vary widely. Thus, we should consider the length of follow-up in patients affected by renal tumors and determine whether these follow-ups are cost-effective, for

which more studies should be done with a larger number of cases.

In selected patients, when the primary tumor is controlled, the pancreas is the only organ affected by metastasis and the lesion or lesions are resectable, aggressive surgical treatment is recommended. Surgery in these cases improves survival and quality of life.¹⁻⁹

Conflict of Interests

The authors have no conflict of interests to declare.

REFERENCES

1. Pérez Fentes DA, Blanco Parra M, Toucedo Caamaño V, Lema Grille J, Cimadevila García A, Villar Núñez M. Carcinoma renal metastásico de localización atípica. Revisión de la literatura. *Actas Urol Esp.* 2005;29:621-30.
2. Kassabian A, Stein J, Jabbour N, Parsa K, Skinner D, Parekh D, et al. Renal cell carcinoma metastatic to the pancreas: a single-institution series and review of the literature. *Urology.* 2000;56:211-5.
3. Tanis PJ, van der Gaag NA, Busch OR, van Gulik TM, Gouma DJ. Systematic review of pancreatic surgery for metastatic renal cell carcinoma. *Br J Surg.* 2009;96:579-92. June Review.
4. Sweeney AD, Fisher WE, Wu MF, Hilsenbeck SG, Brunnicardi FC. Value of pancreatic resection for cancer metastatic to the pancreas. *J Surg Res.* 2010;160:268-76.
5. Aimoto T, Uchida E, Yamahatsu K, Yoshida H, Hiroi M, Tajiri T. Surgical treatment for isolated multiple pancreatic metastases from renal cell carcinoma: report of a case. *J Nippon Med Sch.* 2008;75:221-4.
6. Hijioka S, Hifumi M, Mekky MA, Takekuma Y, Kawaguchi T, Yokomizo H, et al. Total pancreatectomy for metastatic renal cell carcinoma with marked extension into the main pancreatic duct. *Intern Med.* 2010;49:557-62.
7. Machado NO, Chopra P. Pancreatic metastasis from renal carcinoma managed by Whipple resection. A case report and literature review of metastatic pattern, surgical management and outcome. *JOP.* 2009;10:413-8.
8. Eidt S, Jergas M, Schmidt R, Siedek M. Metastasis to the pancreas - an indication for pancreatic resection? *Langenbecks Arch Surg.* 2007;392:539-42. Epub.
9. Thompson L, Heffess C. Renal cell carcinoma to the pancreas in surgical pathology material. *Cancer.* 2000;89:1076-88.
10. Goto T, Dohmen T, Yoneyama K. Pancreatic metastasis from renal cell carcinoma. *Clin Gastroenterol Hepatol.* 2007;5:A26.