

Image of the month

Migration of a Sternum Fixation Bar to the Abdominal Cavity[☆]

Migración de una barra de fijación esternal hacia la cavidad abdominal

Marta Martínez Míguez,^a María Teresa García Martínez,^a Montserrat Blanco Ramos,^{b,*}
John Christian Durán Toconas^b

^aServicio de Cirugía General, Hospital Clínico Universitario de Vigo, Vigo, Spain

^bServicio de Cirugía Torácica, Hospital Clínico Universitario de Vigo, Vigo, Spain

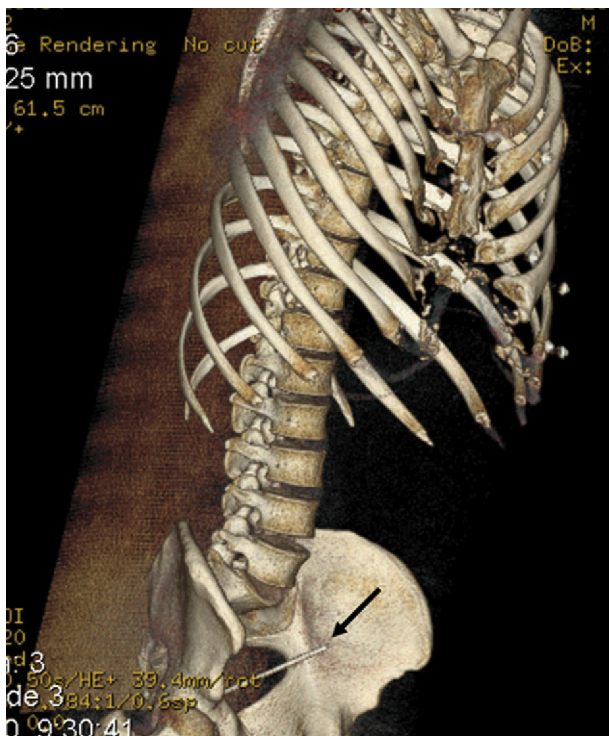


Fig. 1

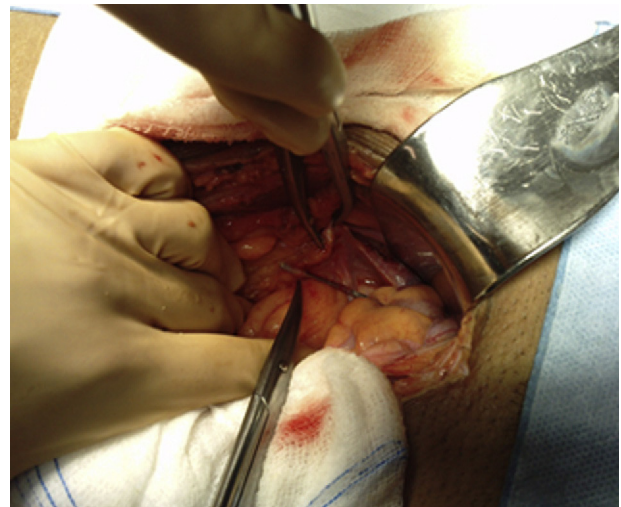


Fig. 2

A 34-year-old male was assessed in our department due to abdominal pain that had developed over several days. He had undergone surgery for pectus excavatum repair with the Ravitch procedure in 1995. He reported no previous history of chest trauma. Abdominal CT revealed a metallic foreign object

in the pelvic area that corresponded to a broken fragment of the fixation bar used to correct the pectus disorder (Fig. 1). In June of 2010, the patient underwent a midline laparotomy to remove the foreign object, which was lodged at the bottom of the Douglas pouch (Fig. 2).

[☆] Please cite this article as: Martínez Míguez M, et al. Migración de una barra de fijación esternal hacia la cavidad abdominal. Cir Esp. 2013;91:194.

* Corresponding author.

E-mail address: montseblancoramos@hotmail.com (M. Blanco Ramos).
2173-5077/\$ – see front matter © 2011 AEC. Published by Elsevier España, S.L. All rights reserved.