

## Image of the Month

## Acute Anuria and a Giant Inguinoscrotal Hernia of Sudden Growth<sup>☆</sup>

### Anuria aguda y hernia inguinoescrotal gigante de crecimiento súbito

Montiel Jiménez Fuertes,<sup>a,\*</sup> David Costa Navarro,<sup>a</sup> Azahara Illán Riquelme,<sup>a</sup>  
Jose Antonio Cánovas Ivorra<sup>b</sup>

<sup>a</sup> Servicio de Cirugía General y Digestiva, Hospital Marina Baixa, Alicante, Spain

<sup>b</sup> Servicio de Urología, Hospital Marina Baixa, Alicante, Spain

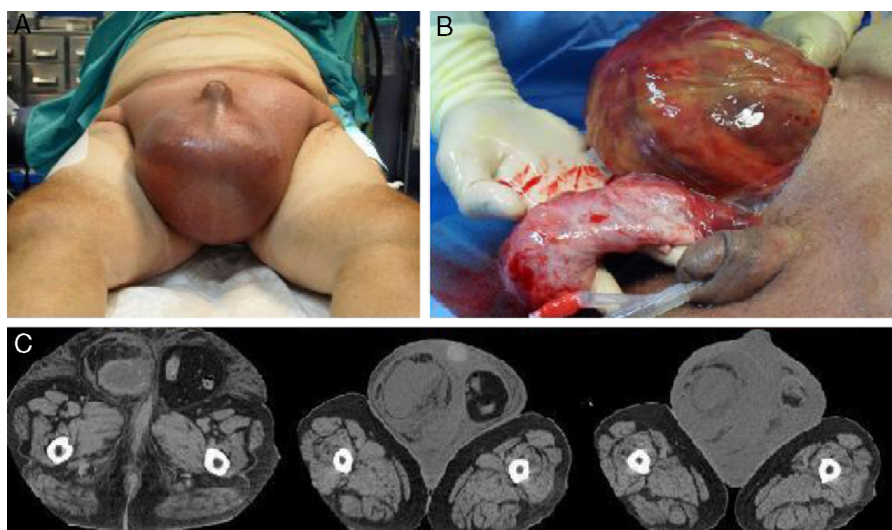


Fig. 1

A 70-year-old man consulted for oligoanuria of 48 h duration, and a sudden increase in size of the scrotum. On physical examination he presented an important increase in the volume of the scrotum with skin tension (Fig. 1A).

CT scan (Fig. 1C): Large right inguinal hernia containing the bladder, with an irregular outline compatible with rupture or lesion, and abundant fluid in the sac.

Emergency surgery was performed, that showed a distended bladder herniated in the sac (Fig. 1B). No bladder lesion was found, and a hernioplasty and testicular pexy was performed with a favourable outcome.

Diagnosis: Inguinoscrotal bladder hernia.

<sup>☆</sup> Please cite this article as: Jiménez Fuertes M, Costa Navarro D, Illán Riquelme A, Cánovas Ivorra JA. Anuria aguda y hernia inguinoescrotal gigante de crecimiento súbito. Cir Esp. 2013;91:e27–e27.

\* Corresponding author.

E-mail address: montieljf@hotmail.com (M. Jiménez Fuertes).