

Image of the month

Pancreatic Pseudocyst Fistulised to Pleural Space: A Rare Cause of a Massive Pleural Effusion[☆]

Pseudoquiste pancreático fistulizado a cavidad pleural. Una rara causa de derrame pleural masivo

Eugenia Caballero Rodríguez,^{a,*} M. Araceli Hidalgo Rodríguez,^b Jorge Herrero Collantes,^c
Carlos Enrique García Franco^c

^a Servicio de Cirugía Gral. y del Aparato Digestivo, Hospital Universitario Nuestra Señora de Candelaria, Santa Cruz de Tenerife, Spain

^b Servicio de Radiodiagnóstico, Hospital Universitario Nuestra Señora de Candelaria, Santa Cruz de Tenerife, Spain

^c Servicio de Cirugía Torácica, Hospital Universitario Nuestra Señora de Candelaria, Santa Cruz de Tenerife, Spain

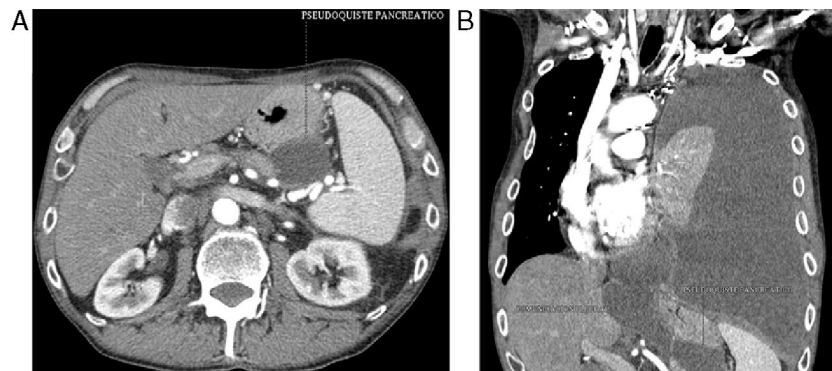


Fig. 1

A 50 year old man with a prior history of smoking and moderate alcohol use came to the Emergency Department due to progressive respiratory difficulty. A chest X-ray revealed a massive left pleural effusion, and a thoracocentesis was performed, revealing an amylase-rich fluid. A chest CT scan (Fig. 1) revealed a left pleural effusion with pulmonary collapse and a communication of this effusion with the abdomen through a fistulous tract originated in a pancreatic pseudocyst. A pleural drain was placed, but no spontaneous pulmonary re-expansion was seen ("trapped lung"). The patient was operated on and a pulmonary decortication was performed. He presented a favourable clinical course and was discharged without complications.

[☆] Please cite this article as: Caballero Rodríguez E, Hidalgo Rodríguez MA, Herrero Collantes J, García Franco CE. Pseudoquiste pancreático fistulizado a cavidad pleural. Una rara causa de derrame pleural masivo. Cir Esp. 2013;91:335–335.

* Corresponding author.

E-mail address: eugenia0005@gmail.com (E. Caballero Rodríguez).