

Original Article

Use of Gastrografin[®] in the Management of Adhesion Intestinal Obstruction[☆]

Laura Mora López,^{*} Xavier Serra-Aracil, Heura Llaquet Bayo, Salvador Navarro Soto

Servicio de Cirugía General y del Aparato Digestivo, Corporació Sanitària i Universitària Parc Taulí, Sabadell, Barcelona, Spain

ARTICLE INFO

Article history:

Received 18 August 2012

Accepted 6 October 2012

Available online 21 November 2013

Keywords:

Intestinal obstruction

Adhesions

Gastrografin[®]

A B S T R A C T

Background: Adhesions are the most important cause of intestinal obstruction. Approximately 25% of surgical admissions for acute abdominal conditions are due to intestinal obstruction. Better diagnostic and treatment methods of intestinal obstruction could potentially reduce mortality rate to 5%–10%. Gastrografin[®] could contribute to this achieve this.

Aim: To present a protocol to treat adhesion intestinal obstruction with Gastrografin[®] that is safe, and allows shorter hospital stays and shorter time between admission and surgery.

Material and methods: All patients with adhesion intestinal obstruction without symptoms of strangulation were treated with Gastrografin[®], intravenous fluids and nasogastric tube. Those in whom contrast reach the colon in 8, 12 or 24 h were considered to have partial obstruction, and were fed orally. If Gastrografin[®] failed in the following 24 h, a laparotomy was performed.

Results: Out of a total of 211 episodes (164 patients), 170 episodes received contrast and in 142 cases Gastrografin[®] reached the colon (104 episodes at 8 h, 11 at 12 h, and 27 at 24 h). A laparotomy was required in 28 patients because of failed treatment, and in another 5 for other causes.

Conclusions: A management protocol for adhesion intestinal obstruction with Gastrografin[®] is safe, reduces morbidity and mortality, and leads to a shorter hospital stay.

© 2012 AEC. Published by Elsevier España, S.L. All rights reserved.

El uso de Gastrografin[®] en el manejo del cuadro de oclusión intestinal adherencial

R E S U M E N

Introducción: Las adherencias son la causa más importante de oclusión intestinal, suponen un 25% de las consultas por dolor abdominal. Con un correcto manejo de este cuadro, la mortalidad asociada puede ser menor de un 5–10%. El Gastrografin[®] puede ayudar a ello. **Objetivo:** La aplicación de un protocolo de manejo de la oclusión intestinal adherencial con Gastrografin[®] es segura y permite disminuir la estancia hospitalaria y el tiempo de indicación de cirugía por fallo del tratamiento conservador.

Palabras clave:

Oclusión intestinal

Adherencias

Gastrografin[®]

[☆] Please cite this article as: Mora López L, Serra-Aracil X, Llaquet Bayo H, Navarro Soto S. El uso de Gastrografin[®] en el manejo del cuadro de oclusión intestinal adherencial. Cir Esp. 2013;91:384–388.

^{*} Corresponding author.

E-mail address: Lmora@tauli.cat (L. Mora López).

2173-5077/\$ – see front matter © 2012 AEC. Published by Elsevier España, S.L. All rights reserved.

Material y método: Estudio prospectivo observacional, siguiendo un protocolo preestablecido. Una vez diagnosticado el cuadro, descartadas otras causas de oclusión y la presencia de sufrimiento intestinal, se administra Gastrografin® y se inicia tratamiento conservador. Si el Gastrografin® pasa al colon en el control de las 8, 12 o 24 h posteriores a su administración, se considera la oclusión como parcial, se inicia dieta oral y se evalúa el alta. Si no pasa el contraste a las 24 h, se indica cirugía.

Resultados: Desde enero de 2009 hasta diciembre de 2011, se trataron 211 episodios (164 pacientes). En 170 episodios se administró contraste con llegada del mismo al colon en 142 episodios (104 episodios a las 8 h, 11 a las 12 h y 27 a las 24 h) Se intervienen a 28 pacientes por fallo del tratamiento conservador y a 5 por otras causas.

Conclusiones: La aplicación de un protocolo en el que se incluye el uso de Gastrografin® en la oclusión intestinal adherencial es seguro y permite tomar decisiones terapéuticas con mayor celeridad y con una menor estancia hospitalaria.

© 2012 AEC. Publicado por Elsevier España, S.L. Todos los derechos reservados.

Introduction

Intestinal obstruction is a frequently seen entity in the Emergency Department that represents 25% of abdominal pain consultations.¹ The most frequent causes of intestinal obstruction are postoperative adhesions followed by neoplasms and hernias.² The estimated rate of adhesions is around 94%–95% after laparotomy. It has recently been demonstrated that this rate is much lower in laparoscopic procedures, although the exact percentage is not known.³ Before the 1990s, the mortality rate associated with intestinal obstruction was 30%–50%, depending on the series.⁴ Nowadays, the correct diagnosis of symptoms and adequate treatment can lower the mortality rate to 3%–5%.^{4–6}

During the management of intestinal obstruction, the patient should initially be made to fast and intravenous therapy should be administered, in addition to intestinal decompression with a nasogastric tube. Most of the symptoms will respond to conservative treatment. The indication for surgery is clear when there are data to suspect ischemia or intestinal suffering: fever, tachycardia, abdominal pain, peritonitis and acidosis. The problem lies in knowing how much time should pass before we decide whether the patient is responding to conservative treatment and, therefore, when surgery should be indicated.

There have been several attempts at trying to improve the management of this entity: one of the most well-known has been the administration of water-soluble contrast.⁷ The use of these contrasts gives a more precise diagnosis of the partial or complete obstruction⁴ according to whether the contrast passes into the colon and, therefore, facilitates the decision for surgery in those obstructions that do not improve with medical treatment.⁸ The therapeutic effect of these water-soluble contrasts is not clear, although some studies say they can demonstrate it when the contrasts are administered more than 24 h after the conservative treatment.⁹ Based on these studies, our department has used an algorithm for cases of adhesive intestinal obstruction (AIO) in order to demonstrate that it provides safe management of the symptoms, is able to improve surgical indication time and also improves hospitalization times, without increasing adverse effects.

Material and Methods

This descriptive, prospective and observational study was carried out from January 2009 to December 2011. Following the protocol described in Fig. 1 at our hospital, when a patient presents with clinical symptoms compatible with intestinal obstruction (Fig. 2) and has a history of surgery, the first suspected diagnosis is AIO. All patients undergo detailed abdominal examination in order to rule out the presence of other causes for the obstruction. Afterwards, an abdominal radiograph is ordered along with analyses including blood work-up, biochemistry and acid-base balance. If the patient fulfills the inclusion criteria (symptoms and radiology compatible with obstruction and history of abdominal surgery with an interval of more than one month), he/she is included in the AIO protocol. If, contrarily, the patient presents exclusion criteria (Table 1), he/she is not included in the

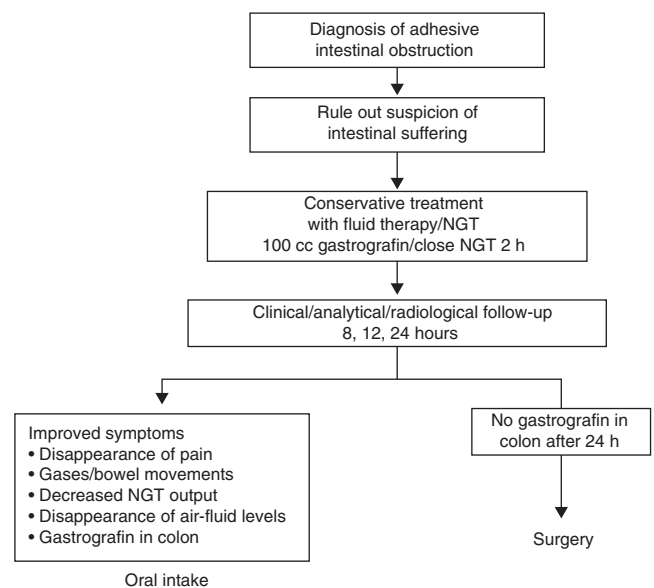


Fig. 1 – Flowchart of the protocol in cases of intestinal obstruction due to adhesions.

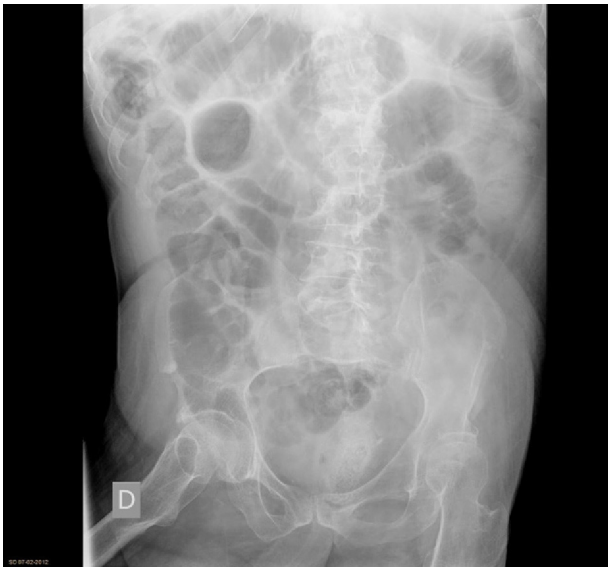

Fig. 2 – Initial image of intestinal obstruction due to adhesions.

protocol and management is determined by the characteristics of each case.

In cases of AIO, the water-soluble contrast Gastrografin® was administered in our center. Prior to the administration of Gastrografin®, gastric decompression was performed with the placement of a nasogastric tube for approximately 2 h in order to reduce the risk of vomiting and aspiration after the administration of the contrast. At the follow-up controls (at 8, 12, 24 h), oral intake was initiated when the patient presented passage of the contrast material to the colon (Fig. 3), regardless of the time of the control.

The variables that were collected and analyzed were: age, sex, types and number of previous surgical interventions, need for surgery, need for intestinal resection during the episode and hospital stay.

For the statistical analysis, we used the SPSS 17.0 program. The quantitative variables are reported by means and standard deviation or median and range when the distribution was not normal. The categorical variables are described in absolute numbers and percentages.

Results

During the study period, 211 episodes of AIO were diagnosed in our hospital in 164 patients: 61 ♀ and 103 ♂, with a mean age of 70 (range 24–93).

Table 1 – Exclusion Criteria of the Protocol.

1. Age < 18
2. Gestation
3. Iodine allergy
4. Previous radiotherapy
5. Digestive vascular disease
6. Early post-operative obstruction
7. Incarcerated ventral hernia

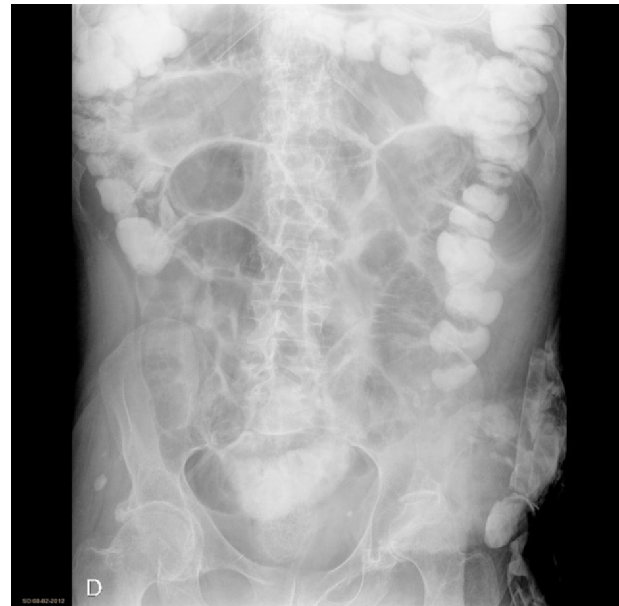

Fig. 3 – Intestinal obstruction after the administration of Gastrografin® with resolution of symptoms.

As recorded in the medical files of the 164 patients, 105 (64.6%) had undergone lower abdominal surgery, 25 (40%) had a single previous surgery and only 4 patients out of the 164 (2.4%) had had prior laparoscopic surgery (Table 2).

The time between the surgery and the episode of intestinal obstruction was very variable, ranging from 1 month to 10 years with a mean of 55 months.

Mean hospital stay was 5.5 days, and 48 h in those patients in whom the contrast passed into the colon.

Contrast material was administered in 170 of the cases diagnosed. In the 41 episodes when contrast was not used, the causes were: rapid resolution of the symptoms in 29 episodes (72%), deterioration of the patient with signs of intestinal ischemia in 5 episodes (12%), transfer of the patient or voluntary hospital discharge in 6 cases (14%) and contrast allergy in one patient (2%). No adverse effects were observed related to the administration of the contrast.

Table 2 – Patient Characteristics.

Total	211 episodes
Sex	61 ♀/103 ♂
Mean age	70 (24–93)
Surgical history	
Lower abdomen	105 episodes (64.4%)
Single surgery	25 episodes (40%)
Laparoscopic surgery	4 episodes (2.4%)
Time since surgery – AIO	1 month–10 years
Mean hospital stay	
Global	5.5 days
Passage of contrast	48 h

Table 3 – Results of Application of the AIO Protocol.

Administration of contrast (170 episodes)	
Contrast in colon (142 episodes, 83%)	
8 h control	104 episodes (73%)
12 h control	11 episodes (8%)
24 h control	27 episodes (19%)
No contrast in colon after 24 h (28 episodes, 17%)	
No administration of contrast (41 episodes)	
Rapid resolution AIO: 29 episodes (72%)	
Signs of intestinal ischemia: 5 episodes (12%)	
Transfer or voluntary discharge: 6 episodes (14%)	
Allergy to iodinated contrast: 1 episode (2%)	

In the 170 episodes in which contrast was administered, it passed to the colon in 142 (83%). The contrast was observed in the colon after 8 h in 104 episodes out of the 142 (73%), after 12 h in 11 episodes (8%) and after 24 h in 27 episodes (19%). In 28 episodes out of the 170 (17%), the contrast had not passed into the colon after 24 h and the patients presented no improvement in their symptoms, requiring surgery (Table 3).

Table 4 reports the recurrence of the obstructive symptoms in our group.

Thirty-three patients required surgery: 28 cases due to failure of the conservative treatment and 5 cases in which, upon hospitalization or during their stay in the ER, the patients presented clinical or analytical signs of intestinal ischemia. Surgical findings included the presence of a solitary adhesion/band in 16 episodes out of 33 (48%) and multiple adhesions in 17 episodes (52%). Intestinal resection was only needed in 5 patients out of the 33 (3%).

Discussion

We know that AIO is a frequent pathology seen in the Emergency Department. It presents an important mortality rate that can be reduced to 3%–5% with proper management of symptoms.⁴⁻⁶ It initially requires a conservative management with fluid therapy, fasting and decompression. More than 70% of cases will have a good response to this initial conservative management.¹⁰⁻¹²

When we observe the results obtained with the application of the protocol, we can confirm that our results corroborate the results of studies that administer water-soluble contrast medium after the diagnosis of AIO. The most important studies on the application of water-soluble media in intestinal

obstruction due to bands and adhesions were initiated in the 1990s, and studies still continue today.¹³ They all try to demonstrate the diagnostic utility of contrasts and also their therapeutic utility. As for the diagnostic utility of these contrast materials, the studies all concur that they are able to determine the type of obstruction (either partial or complete) with a high sensitivity, specificity and positive and negative predictive value (87.5, 100, 100 and 97.9%, respectively).¹⁴ This high diagnostic precision enables physicians to improve the management of AIO from its initial diagnosis.

In these studies, there are differences with regard to radiological control times after the administration of the contrast. Some studies indicate surgery in the first radiological control after 4 h.¹⁵ This seems an aggressive measure, however, especially when studies with a longer waiting period,¹⁶⁻¹⁹ like our study, have observed that most patients (104 patients out of 142 [73%]) who present partial obstruction respond within the first 8 h. But there is a percentage, 28 episodes out of 142 (17%), that may respond within the first 24 h and, therefore, surgery may be avoided in these cases. It is not recommended to lengthen the control times for longer than 24 h because this has not been shown to improve the results and may increase patient morbidity and mortality.¹⁶

The diagnostic effect is able to streamline the treatment of partial obstructions, which shortens the hospital stays of patients, as observed in our case and in reports by other groups.^{20,21} Furthermore, the adverse effects related with hospital stay are also minimized. With regard to complete obstruction, the use of these contrasts is able to shorten the time between the hospitalization of the patient until the indication of surgery.²² Until now, contrast material has not been shown to have a therapeutic effect (meaning that they reduce the number of episodes requiring surgery), although in some studies it seems to do so.^{9,23} What we can affirm is that, although the reduction in the number of surgeries in this pathology is not clear, we do see a reduction in the number of patients requiring intestinal resection. Only 5 out of the 33 surgical patients (3%) required intestinal resection. This may be related to the rapid indication of surgery when conservative treatment fails. In our study, the patients who required surgery presented solitary as well as multiple bands with similar percentages.

Until now, we have not seen any adverse effects related with the administration of contrast material in our patients. Allergic reactions and aspiration pneumonitis have been reported²⁴ related with the use of orally administered water-soluble contrast media. Of all the studies reviewed, there was only one report of an allergic reaction.²⁵ We can therefore confirm that the administration of water-soluble contrast material in the management of AIO is safe.²⁶

In conclusion, the protocol that we apply in our hospital is a safe protocol that provides proper management of AIO. In cases of partial obstruction, it reduces hospital stays and, in cases of total obstruction, it shortens the time before the indication of surgery. This leads to a lower percentage of intestinal resection in cases requiring surgery.

Table 4 – Recurrences.

No. of Episodes	Patients	Surgery
1	135	31 (22%)
2	17	2 (12%) ^a
3	3	0
4	5	0
5	1	0

All patients were treated according to the AIO protocol.

^a Both after the second episode.

Conflict of Interest

The authors declare that they have no conflicts of interest.

Acknowledgements

We would like to thank all the members of the General Surgery Department, and especially the on-call teams, for their collaboration in carrying out this protocol. Thanks also to the Diagnostic Radiology Department for their participation in the radiological controls of these patients.

REFERENCES

- Sosa J, Gardner B. Management of patients diagnosed as acute intestinal obstructions secondary to adhesions. *Am Surg.* 1993;63:367-71.
- Mucha Jr P. Small intestinal obstruction. *Surg Clin North Am.* 1987;67:597-620.
- Bamparas G, Branco BC, Schüriger B, Lam L, Inaba K, Demetriades D. The incidence and risk factors of post-laparotomy adhesive small bowel obstruction. *J Gastrointest Surg.* 2010;14:1619-28.
- McEntee G, Pender D, Mulvin D, McCullough M, Naeeder S, Farah S, et al. Current spectrum of intestinal obstruction. *Br J Surg.* 1987;74:976-80.
- Miller G, Boman J, Shrier I, Gordon PH. Natural history of patients with adhesive small bowel obstruction. *Br J Surg.* 2000;87:124-1247.
- Fevang BT, Fevang J, Stangeland L, Soreide O, Svanes K, Viste A. Complications and death after surgical treatment of small bowel obstruction. *Ann Surg.* 2000;231:529-37.
- Zer M, Kaznelson D, Feigenberg Z, Dintsman M. The value of gastrografin in the differential diagnosis of paralytic ileus versus mechanical intestinal obstruction: a critical review and report of two cases. *Dis Colon Rectum.* 1977;20:573.
- Branco BC, Bamparas G, Schnüriger B, Inaba K, Chan LS, Demetriades D. Systematic review and meta-analysis of the diagnostic and therapeutic role of water-soluble contrast agent in adhesive small bowel obstruction. *Br J Surg.* 2010;97:470-8.
- Fevang BT, Jensen D, Fevang J, Søndena K, Ovrebø K, Rokk O, et al. Upper gastrointestinal contrast study in the management of small bowel obstruction: a prospective randomised study. *Eur J Surg.* 2000;166:39-43.
- Menzies D, Ellis H. Intestinal obstruction from adhesions: how big is the problem? *Ann Coll Surg Engl.* 1990;72:60.
- Bass KN, Jones B, Buckley GB. Current management of small bowel obstruction. *Adv Surg.* 1997;31:1.
- Brolin RE. Partial small bowel obstruction. *Surgery.* 1984;95.
- Di Saverio S, Catena F, Ansaloni L, Gavioli M, Valentino M, Pinna AD. Water-soluble contrast medium (Gastrografin) value in adhesive small intestine obstruction (ASIO): a prospective, randomized, controlled clinical trial. *World J Surg.* 2008;32:2293-304.
- Farid M, Fikry A, El Nakeeb A, Fouda E, Elmetwally T, Yousef M, et al. Clinical impacts of oral gastrografin follow-through in adhesive small bowel obstruction (SBO). *J Surg Res.* 2010;162:170-6.
- Joyce WP, Delaney PV, Gorey TF, Fitzpatrick JM. The value of water-soluble contrast radiology in the management of acute small bowel obstruction. *Ann R Coll Surg Engl.* 1992;74:422-5.
- Feigin E, Seror D, Szold A, Carmon M, Allweis TM, Nissan A, et al. Water-soluble contrast material has no therapeutic effect on postoperative small-bowel obstruction: results of a prospective, randomized clinical trial. *Am J Surg.* 1996;171:227-9.
- Chen SC, Lin FY, Lee PH, Yu SC, Wang SM, Chang KJ. Water-soluble contrast study predicts the need for early surgery in adhesive small bowel obstruction. *Br J Surg.* 1998;85:1692-4.
- Onoue S, Katoh T, Shibata Y, Matsuo K, Suzuki M, Chigira H. The value of contrast radiology for postoperative adhesive small bowel obstruction. *Hepatogastroenterology.* 2002;49:1576-8.
- Choi HK, Law WL, Ho JW, Chu KW. Value of Gastrografin in adhesive small bowel obstruction after unsuccessful conservative treatment: a prospective evaluation. *World J Gastroenterol.* 2005;11:3742-5.
- Burge J, Abbas SM, Roadley G, Donald J, Connolly A, Bissett IP, et al. Randomized controlled trial of Gastrografin in adhesive small bowel obstruction. *ANZ J Surg.* 2005;75:672-4.
- Abbas S, Bissett IP, Parry BR. Meta-analysis of oral water-soluble contrast agent in the management of adhesive small bowel obstruction. *Br J Surg.* 2007;94:404-11.
- Assalia A, Schein M, Kopelman D, Hirshberg A, Hashmonai M. Therapeutic effect of oral Gastrografin in adhesive, partial small-bowel obstruction: a prospective randomized trial. *Surgery.* 1994;115:433-7.
- Abbas S, Bissett IP, Parry BR. Oral water soluble contrast for the management of adhesive small bowel obstruction. *Cochrane Database Syst Rev.* 2007;CD004651. Review.
- Ridley LJ. Allergic reactions to oral iodinated contrast agents: reactions to oral contrast. *Australas Radiol.* 1998;42:114-7. Review.
- Kapoor S, Jain G, Sewkani A, Sharma S, Patel K, Varshney S. Prospective evaluation of oral Gastrografin in postoperative small bowel obstruction. *J Surg Res.* 2004;131:256-60.
- Biondo S, Parés D, Mora L, Martí Ragué J, Jaurrieta E. Randomized clinical study of Gastrografin administration in patients with adhesive small bowel obstruction. *Br J Surg.* 2003;90:542-6.