

## Image of the month

Primary Retroperitoneal Hydatid Cyst<sup>☆</sup>

## Quiste hidatídico retroperitoneal primario

Martin Vallverdú Scorza,\* Rubens Neirotti

Clínica Quirúrgica F. Hospital de Clínicas, Facultad de Medicina, Montevideo, Uruguay

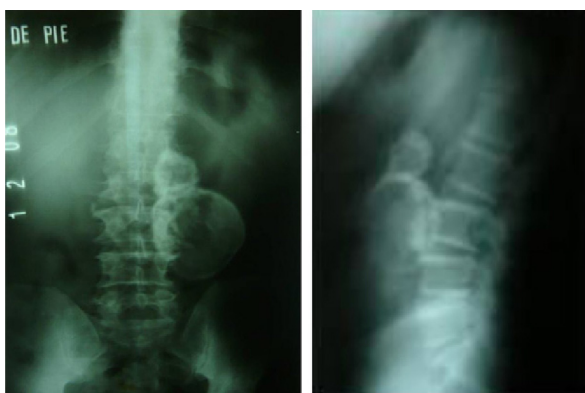

Fig. 1

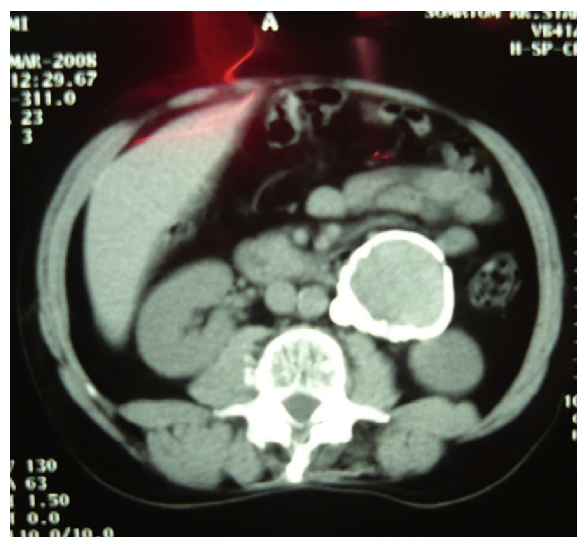


Fig. 2

The patient is a 53-year-old man who lived in a rural setting. Over the course of the previous 6 months, he had experienced left lumbar pain, which was interpreted as being osteoarticular in origin. Radiography of the lumbar spinal column showed an hourglass-shaped calcified image in the left paravertebral region (Fig. 1). CT demonstrated a process measuring 80 mm with an inhomogeneous density, solid, cystic and calcified in the retroperitoneum, under the body of the pancreas outside the large vessels (Fig. 2). Serology for hydatid cyst was negative. A midline laparotomy was performed with complete resection of the cyst. Pathology studies confirmed hydatid cyst, and the patient has had no relapse in 3 years of follow-up.

<sup>☆</sup> Please cite this article as: Vallverdú Scorza M, Neirotti R. Quiste hidatídico retroperitoneal primario. Cir Esp. 2013;91:e39.

\* Corresponding author.

E-mail address: [mvall@adinet.com.uy](mailto:mvall@adinet.com.uy) (M. Vallverdú Scorza).