

appropriate for venous thrombectomy; and (c) in cases of extensive ischemic compromise, no resection should be done.^{1,3,5,6}

Factors that seem to alter early survival are early diagnosis and anticoagulation,^{3,6} associated diseases and patient age.^{1,6} The relapse rate is high; thus, when a hereditary hypercoagulable state is detected, prolonged systemic anticoagulation should be maintained, while in other pro-thrombotic conditions 6 months of treatment provide adequate coverage.^{3,6}

In summary, in patients with abdominal pain that has developed over several days or weeks with no demonstrated cause, MVT should be considered since early treatment can avoid mesenteric ischemia or a fatal outcome.

REFERENCES

- Rhee RY, Glociczki P, Mendonca CT, Petterson TM, Serry RD, Sarr MG, et al. Mesenteric venous thrombosis: still a lethal disease in the 1990. *J Vasc Surg.* 1994;20:688-97.
- Kim HS, Patra A, Khan J, Arepally A, Streiff MB. Transhepatic catheter-directed thrombectomy and thrombolysis of acute superior mesenteric venous thrombosis. *J Vasc Interv Radiol.* 2005;168:151-69.
- Lui AG, Poniachik TJ, Quera PR, Bermúdez EC. Trombosis venosa mesentérica: manifestaciones clínicas, terapia y evolución. *Rev Méd Chile.* 2005;133:17-22.
- Muñoz S, Cubo P, González-Castillo J, Nuevo JA, García-Lamberechts EJ, Sanz A. Trombosis de vena mesentérica superior: estudio retrospectivo de trece casos. *Rev Esp Enferm Dig.* 2004;96:385-94.
- Morasch MD, Ebaugh JL, Chiou AC, Matsumura JS, Pearce WH, Yao JST. Mesenteric venous thrombosis. *J Vasc Surg.* 2001;34:680-4.
- Warshauer DM, Lee JKT, Mauro MA, White GC. Superior mesenteric vein thrombosis with radiologically occult cause: a retrospective study of 43 cases. *Am J Radiol.* 2001;177:837-41.
- Soulier K, Delèveaux I, André M, Du LTH, Dupond JL, Piette JC, et al. Thromboses veineuses mésentériques: apports diagnostiques du scanner abdominal et de la recherche d'une coagulopathie. Six observations. *Rev Méd Interne.* 2001;22:699-705.
- Domínguez-Comesaña E, Nicolás-Jiménez R, Tomé-Espiñeira C, Estévez-Fernández S. Trombosis postoperatoria del eje venoso esplenoportomesentérico. *Cir Esp.* 2010;87:251.
- Cho YP, Jung SM, Han MS, Jang HJ, Kim JS, Kim YH, et al. Role of diagnostic laparoscopy in acute mesenteric venous thrombosis. *Surg Laparosc Endosc Percutan Tech.* 2003;13:215-7.
- Kim JH, Ha HK, Sohn MJ, Kim AY, Kim TK, Kim PN, et al. CT findings of phytobezoar associated with small bowel obstruction. *Eur Radiol.* 2003;13:299-304.

Arturo Del Rey-Moreno^{a,*}, Juan José Jiménez-Martín^b, Juan Doblaz-Fernández^a, Ricardo Marín-Moya^a, Juan García-Hirschfeld^b

^aCirugía General y del Aparato Digestivo, Hospital de Antequera, Antequera, Málaga, Spain

^bAnatomía Patológica, Hospital de Antequera, Antequera, Málaga, Spain

*Corresponding author.

E-mail address: arturodelreymoreno@gmail.com

(A. Del Rey-Moreno).

2173-5077/\$ – see front matter

© 2010 AEC. Published by Elsevier España, S.L. All rights reserved.

Therapeutic Management of Juxtapapillary Duodenal Diverticulum

Manejo terapéutico del divertículo duodenal yuxtapapilar

Duodenal diverticula are acquired lesions that generally appear in the second duodenal portion,^{1,2} with a prevalence in the general population that is around 20% and increases with age.¹⁻⁴ Although they may present as a potentially fatal emergency complication, duodenal diverticula are usually either asymptomatic or manifest as recurring choledocholithiasis.¹⁻³ Therefore, surgical bilioenteric bypass could be considered a safe, effective treatment.

We present the case of a 75-year-old woman with a medical history of arterial hypertension, mild mitral insufficiency and laparoscopic cholecystectomy in 2007 due to non-complicated symptomatic cholelithiasis. One year after cholecystectomy, she was diagnosed with choledocholithiasis due to dyspepsia

and altered liver function, requiring endoscopic retrograde cholangiopancreatotomy (ERCP) with sphincterotomy on 2 separate occasions. The endoscopic procedure revealed evidence of the presence of a juxtapapillary duodenal diverticulum (JDD). Afterwards, she presented isolated episodes of mild abdominal pain. In November 2010, the patient came to our Emergency Department complaining of intense sudden-onset epigastric pain that radiated toward both flanks of 12 h duration, with no jaundice or other symptoms. The work-up demonstrated moderately high transaminases (AST/ALT: 339/183 IU/L). Abdominal ultrasound showed pneumobilia and a 12 mm common bile duct with a hyperechogenic image in the interior compatible with lithiasis. It was

* Please cite this article as: Beisani M, Espin F, Dopazo C, Quiroga S, Charco R. Manejo terapéutico del divertículo duodenal yuxtapapilar. *Cir Esp.* 2013;91:463-465.

decided to hospitalize the patient and an abdominal computed tomography was performed, as it was impossible to carry out magnetic resonance tests due to claustrophobia. Oblique multiplanar reconstruction revealed a dilated common bile duct with important pneumobilia and the presence of a non-complicated duodenal diverticulum measuring 36 mm×20 mm in apparent relation with the dilation of the extrahepatic bile duct (Fig. 1). After clinical improvement with medication and normalization of blood tests, we decided to operate with intraoperative cholangiography, which confirmed the findings of bile duct dilation and giant juxtapaillary duodenal diverticulum with an anterior-superior projection. We therefore proceeded with complete dissection of the bile duct, distal ligation and bilioenteric bypass by means of Roux-en-Y hepaticojejunostomy. The patient presented a non-eventful post-op recovery, and she currently has satisfactory outpatient follow-ups with no recurrence of the previous gastrointestinal symptoms.

The point of least resistance in the duodenal wall is at the ampulla of Vater because it is at this point where the circular configuration of the duodenal musculature becomes less structured in order to integrate with the sphincter of Oddi. It is assumed that this is why most duodenal diverticula appear in the juxtapaillary region, and may even encompass the papilla.² Whether the presence of a JDD conditions significant dysfunction at the sphincter of Oddi is still controversial since there are contradictory manometric studies in the literature.^{5,6} There is no evidence of local histologic fibrous or inflammatory changes,⁴ nor has any specific association been reported between JDD and neoplastic disease.⁷

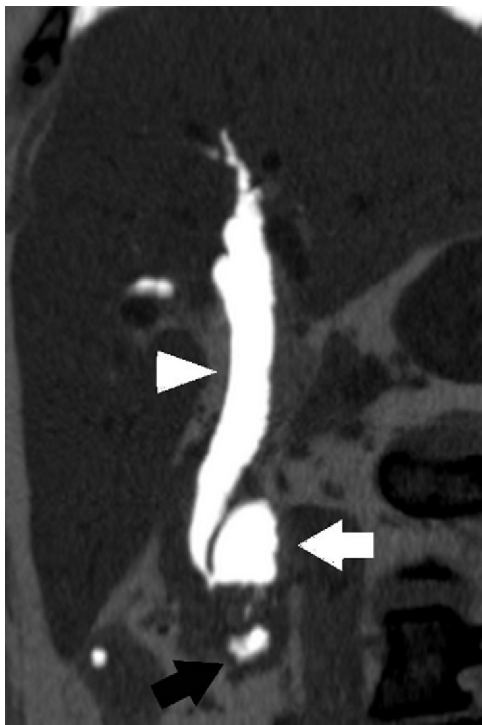

Fig. 1 – Multidetector computed tomography; oblique multiplanar reconstruction at minimum intensity projection showing air in the common bile duct (white arrowhead), juxtapaillary duodenal diverticulum (white arrow) and horizontal portion of the duodenum (black arrow).

It does seem to be proven, however, that the existence of JDD correlates with the appearance of painful biliopancreatic disease in the upper hemi-abdomen, choledocholithiasis, cholangitis or acute pancreatitis.¹⁻⁴ The proposed mechanisms for this association are extrinsic compression of the bile duct (Lemmel's syndrome) and the colonization of the JDD by β -glucuronidase-producing bacteria.⁸ These bacteria would ascend through the bile duct, decomposing the bilirubin conjugated into glucuronic acid and unconjugated bilirubin, which would later transform into calcium bilirubinate, precipitating to form the brown-pigmented gallstones that characteristically appear in the lithiasis associated with JDD. These cases of choledocholithiasis, even cholangitis secondary to Lemmel's syndrome,⁹ may be treated satisfactorily with endoscopy. Although the cannulation of the papilla may be more laborious, the most recent studies do not demonstrate an increase in the risk of complications associated with ERCP with sphincterotomy and/or extraction of calculi.^{2,3,9,10} Nonetheless, the recurrence of choledocholithiasis after effective endoscopy is greater than in patients without JDD (6% vs 1.5%).¹⁰

Duodenal diverticula have also been associated with potentially fatal complications, such as upper gastrointestinal tract bleeding, intestinal obstruction or perforation of the diverticulum (generally retroperitoneal). These complications can evolve into very serious conditions, including sepsis or massive hemorrhage. There is no doubt about the need for emergency surgery in these situations, and diverticulectomy is proposed as the surgical technique of choice. Nevertheless, it should be kept in mind that this procedure presents a mortality of up to 30%.¹

In summary, no intervention is necessary when asymptomatic JDD is an incidental finding.^{1,2} Cases with associated choledocholithiasis can be initially treated with standard endoscopic techniques.³ When recurring symptoms occur, however, we believe that the surgical option should be considered. Although the limited number of patients in whom surgery could play a role makes it difficult to establish conclusions, it seems coherent to think that this should be centered on the bypass of the bile duct, either by hepaticojejunostomy as in most cases or, as an exception, by means of choledocoduodenostomy. The derived morbidity and mortality and the absence of neoplastic association do not justify diverticulectomy or extensive resection of the bile duct in non-complicated situations.

REFERENCES

1. Mathis KL, Farley DR. Operative management of symptomatic duodenal diverticula. *Am J Surg.* 2007;193:305-8. discussion 308-9.
2. Egawa N, Anjiki H, Takuma K, Kamisawa T. Juxtapaillary duodenal diverticula and pancreatobiliary disease. *Dig Surg.* 2010;27:105-9.
3. Tham TCK, Kelly M. Association of periampullary duodenal diverticula with bile duct stones and with technical success of endoscopic retrograde cholangiopancreatography. *Endoscopy.* 2004;36:1050-3.
4. Kimura W, Nagai H, Kuroda A, Muto T. No significant correlation between histologic changes of the papilla of Vater and juxtapaillary diverticulum. Special reference to the pathogenesis of gallstones. *Scand J Gastroenterol.* 1992;27:951-6.

5. Ponce J, Garrigues V, Sala T, Pertejo V, Del Val A, Hoyos M. Motor pattern of the sphincter of Oddi in patients with juxtapapillary diverticula. *J Clin Gastroenterol.* 1990;12:162-5.
6. Løtveit T, Osnes M, Aune S, Larsen S. Studies of the choledocho-duodenal sphincter in patients with and without juxta-papillary duodenal diverticula. *Scand J Gastroenterol.* 1980;15:875-80.
7. Pan SY, Morrison H. Epidemiology of cancer of the small intestine. *World J Gastrointest Oncol.* 2011;3:33-42.
8. Løtveit T. The composition of biliary calculi in patients with juxtapapillary duodenal diverticula. *Scand J Gastroenterol.* 1982;17:653-6.
9. Chiang T-H, Lee Y-C, Chiu H-M, Huang S-P, Lin J-T, Wang H-P. Endoscopic therapeutics for patients with cholangitis caused by the juxtapapillary duodenal diverticulum. *Hepatogastroenterology.* 2006;53:501-5.
10. Zoepf T, Zoepf DS, Arnold JC, Benz C, Riemann JF. The relationship between juxtapapillary duodenal diverticula

and disorders of the biliopancreatic system: analysis of 350 patients. *Gastrointest Endosc.* 2001;54:56-61.

Marc Beisani*, Francisco Espin, Cristina Dopazo, Sergi Quiroga, Ramón Charco

Servicio de Cirugía Hepatobiliopancreática y Trasplante, Hospital Universitari Vall d'Hebrón, Barcelona, Spain

*Corresponding author.

E-mail address: mbeisani@gmail.com (M. Beisani).

2173-5077/\$ – see front matter

© 2010 AEC. Published by Elsevier España, S.L. All rights reserved.

Eosinophilic Cholecystitis

Colecistitis eosinofílica

Eosinophilic cholecystitis (EC) was described for the first time in 1949 by Albot.¹ Its etiology is not always well defined, and can be due to allergies, parasitosis, hypereosinophilic syndrome, eosinophilic gastroenteritis, eosinophilia-myalgia syndrome and drugs.^{2,3} Peripheral eosinophilia is not present in the majority of cases and the diagnosis is established by the presence of infiltrate in the gallbladder wall with more than 90% eosinophils,⁴ because clinically it presents with the classic symptoms of acute cholecystitis. Treatment is cholecystectomy and the diagnosis is confirmed by the pathology study.

We present a case of EC that was treated with laparoscopic cholecystectomy. The patient is a 65-year-old male with a history of type 2 diabetes mellitus in treatment with oral antidiabetes medication, nephrolithiasis and lumbar arthrodesis, with no history of allergy to any medication. He came to our Emergency Room complaining of epigastric abdominal and right upper quadrant pain during the previous 48 h, with no other symptoms. On examination, palpation was painful in the right upper quadrant, with a positive Murphy's sign. Blood tests showed a leukocyte count of 10,500 leukocytes/mm,³ 70.5% segmented and 3.6% eosinophils (normal reference values, 0%-5%). Total serum bilirubin was 1.3 mg/dl; liver enzymes were moderately elevated (AST: 503 U/l, ALT: 239 U/l, GGT: 818 U/l, AP: 402 U/l). Abdominal ultrasound showed findings compatible with acute cholecystitis and a normal main bile duct, and emergency cholecystectomy was decided upon. This was performed laparoscopically with no complications. The pathology study revealed diffuse inflammation of the gallbladder wall with tissue eosinophilia >90% and absence of calculi (Figs. 1 and 2). The patient had a favorable postoperative course and was discharged from the hospital 48 h after surgery.

EC is a rare entity described by Albot in 1949,¹ and there are only 30 cases published in the scientific literature²⁻⁴; it generally presents in the absence of gallbladder lithiasis.⁵ When it presents as acute cholecystitis, it is difficult to suspect the diagnosis before the histologic study of the specimen, unless there is peripheral eosinophilia. CE can present in patients with hypersensitivity or allergy to medication (such as penicillin or erythromycin³), eosinophilia-myalgia syndrome, immunosuppression, parasitosis by *Echinococcus*, *Clonorchis sinensis* or *Ascaris lumbricoides*,⁴ gastrointestinal eosinophilic infiltration (eosinophilic gastroenteritis, eosinophilic granulomatous hepatitis or eosinophilic ascites),⁵ infections due to cytomegalovirus or cryptosporidium, Crohn's disease, sarcoi-

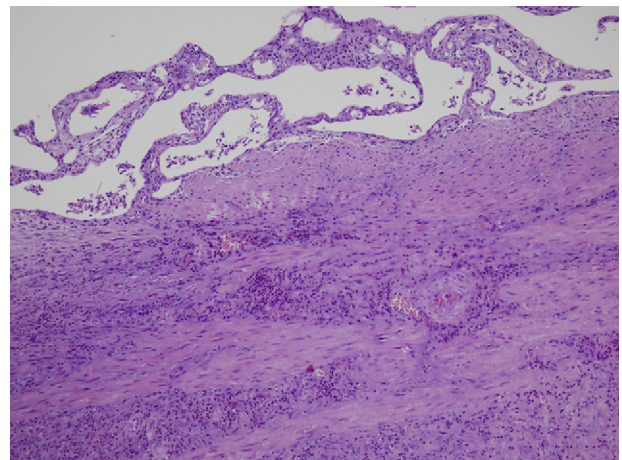


Fig. 1 – Gallbladder wall with intense fibrosis and inflammatory infiltrate (H-E, 10X).

* Please cite this article as: Fernández Santiago R, Fontanillas Garmilla N, Gutiérrez Fernández G, Fernández Fernández F, Gómez Fleitas M. Colecistitis eosinofílica. *Cir Esp.* 2013;91:465-466.