

## Image of the Month

## Perineal Hernia Following Abdominoperineal Amputation and Myocutaneous Flap<sup>☆</sup>

### Hernia perineal tras amputación abdominoperineal y colgajo miocutáneo

Lander Gallego Otaegui, José M. Enríquez-Navascués,\* Yolanda Saralegui Ansorena

Servicio de Cirugía General y Digestiva, Hospital Universitario de Donostia, San Sebastián, Gipúzcoa, Spain

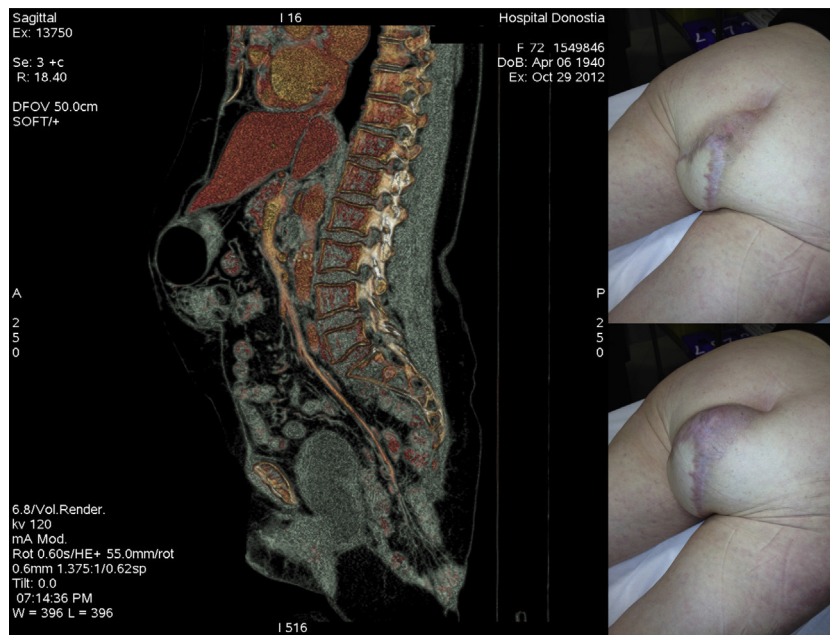


Figure 1

Perineal hernia after infralevator posterior pelvic exenteration due to adenocarcinoma of the lower rectum with genital invasion: a *rectus abdominis* myocutaneous flap was used to repair the defect and reconstruct the vagina. The donor abdominal fascia area was reinforced with bio-absorbable mesh (BioA<sup>®</sup>-Gore).

On CT, ileal loops were observed with elongated mesentery in the pelvis and perineum, and “donor” parietal weakness (without sac) (Fig. 1).

The myocutaneous flap itself was not able to prevent the development of a perineal hernia after abdominal-perineal resection, nor did absorbable mesh avoid the parietal defect created by removing the anterior fascia of the rectal muscle.

<sup>☆</sup> Please cite this article as: Gallego Otaegui L, Enríquez-Navascués JM, Saralegui Ansorena Y. Hernia perineal tras amputación abdominoperineal y colgajo miocutáneo. *Cir Esp*. 2013;91:534.

\* Corresponding author.

E-mail address: [josemaria.enriqueznavascues@osakidetza.net](mailto:josemaria.enriqueznavascues@osakidetza.net) (J.M. Enríquez-Navascués).  
2173-5077/\$ – see front matter © 2013 AEC. Published by Elsevier España, S.L. All rights reserved.