

Image of the Month

Diffuse Gastric Polyposis[☆]

Poliposis gástrica difusa

Izaskun Badiola,^{*} Miguel Corcostegui, Begoña Estraviz, Francisco Javier Ibañez

Servicio de Cirugía General y del Aparato Digestivo, Hospital Galdakao-Usansolo, Spain

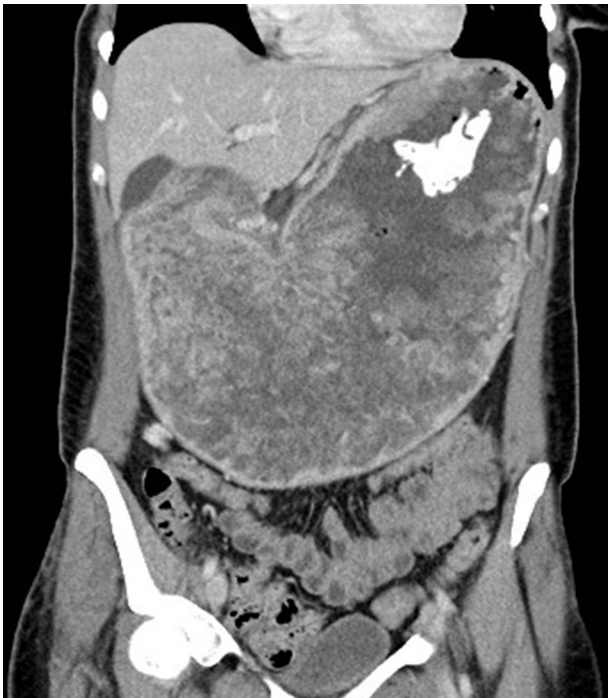

Figure 1

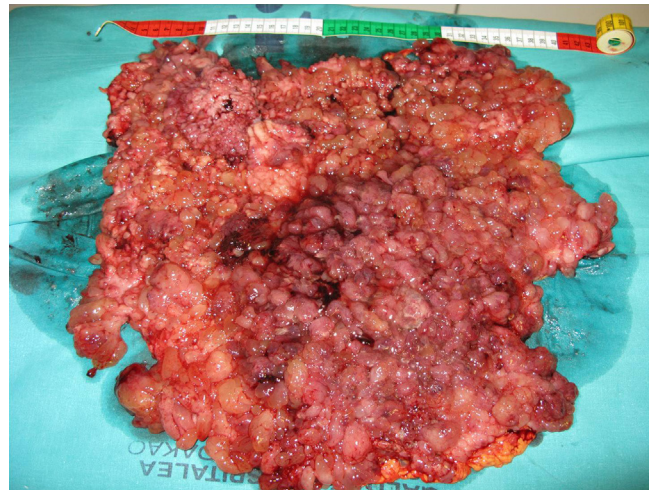


Figure 2

A 37-year-old woman presented with vomiting, hypokalemia (1.9 mEq/l) and anemia (Hct: 8.4%). Gastroscopy and CT (Fig. 1) revealed diffuse gastric polyposis. Colonoscopy revealed 5 polyps that were resected with no signs of degeneration. Total gastrectomy was performed after intraoperative diagnosis of adenocarcinoma (Fig. 2). Histopathological examinations confirmed the diagnosis of gastric adenocarcinoma pT2aN2 and diffuse multiple hyperplastic polyposis. The immunohistochemical study did not detect loss of expression of DNA repair genes (MLH1, MSH2, MSH6, PMS2). Treatment was completed with 6 cycles of 5-fluorouracil and leucovorin. After 7 months, the patient showed tumor progression in the cervical and abdominal lymph nodes and died nine months after diagnosis.

[☆] Please cite this article as: Badiola I, Corcostegui M, Estraviz B, Ibañez FJ. Poliposis gástrica difusa. Cir Esp. 2013;91:e51.

^{*} Corresponding author.

E-mail address: izaskunbadiola@hotmail.com (I. Badiola).