

Image of the month

Giant Liver Abscess. Primary Surgical Treatment[☆]

Absceso hepático gigante. Tratamiento quirúrgico primario

Francisco Javier González Rodríguez,^{a,*} Elías Domínguez Comesaña,^a
José Luis Portela Serra,^a Miguel Ángel Piñón Cimadevila^b

^aUnidad de Cirugía Hepatobiliopancreática, Servicio de Cirugía, Complejo Hospitalario de Pontevedra, Pontevedra, Spain

^bServicio de Cirugía, Complejo Hospitalario de Pontevedra, Pontevedra, Spain

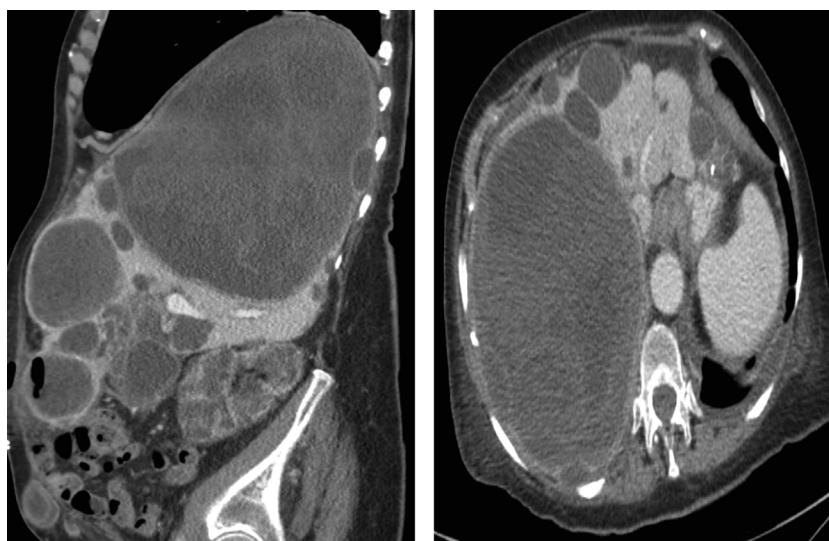


Fig. 1

A 77-year-old patient with hepatorenal polycystic disease and chronic renal failure on hemodialysis came to our emergency department due to abdominal pain in the right upper quadrant. The symptoms had been developing over the previous week, including a fever of 39 °C with localized pain and tenderness in the right upper quadrant. Palpation revealed a large mass that occupied the entire right hemi-abdomen. Blood work-up and biochemistry showed leukocytosis $21 \times 10^9/L$ with neutrophilia $9.7 \times 10^9/L$, anemia Hb 8.7 g/dL, no alteration in liver function tests (GPT 10 U/L; GGT 25 U/L; GOT 21 U/L; Bb 0.6 mg/dl), and procalcitonin 7.37 ng/mL. Abdominal CT showed evidence of multiple cystic formations, the largest measuring 20 cm in the right hepatic lobe, very heterogeneous, with multiple septa and dense areas that showed no uptake of contrast (Fig. 1). The patient underwent emergency surgery to drain the multiple liver abscesses (culture positive for *Escherichia coli*) and cholecystectomy was performed. The patient had a postoperative biliary fistula that was resolved endoscopically with the placement of an endoprosthesis.

[☆] Please cite this article as: González Rodríguez FJ, Domínguez Comesaña E, Portela Serra JL, Piñón Cimadevila MÁ. Absceso hepático gigante. Tratamiento quirúrgico primario. Cir Esp. 2013;91:e47.

* Corresponding author.

E-mail address: fran.padroso@gmail.com (F.J. González Rodríguez).