

8. Koea J, Holden A, Chau K, McCall J. Differential diagnosis of stenosis lesions at the hepatic hilus. *World J Surg.* 2004;28:466-70.
9. Khan SA, Davidson BR, Goldin RD, Heaton N, Karani J, Pereira SP, et al. Guidelines for the diagnosis and treatment of cholangiocarcinoma: an update. *Gut.* 2012.
10. Davidson B, Gurusamy K. Is preoperative histological diagnosis necessary for cholangiocarcinoma? *HPB.* 2008;10:94-7.

Fabio Vergara Suárez^{a*}, Rafael López Andújar^a,
Eva Montalvá Orón^a, Carolina Ramírez Ribelles^b,
Judith Pérez Rojas^c

^aUnidad de Cirugía Hepatobiliopancreática y Trasplante, Hospital Universitario y Politécnico La Fe, Valencia, Spain

^bServicio de Radiodiagnóstico, Hospital Universitario y Politécnico La Fe, Valencia, Spain

^cServicio de Anatomía Patológica, Hospital Universitario y Politécnico La Fe, Valencia, Spain

*Corresponding author.

E-mail address: fvergara@aecirujanos.es (F. Vergara Suárez).

2173-5077/\$ – see front matter

© 2013 AEC. Published by Elsevier España, S.L. All rights reserved.

Complications After Conservative Management of Blunt Liver Trauma: Biliary Fistula, Hemobilia and Biloma

Complicaciones en el manejo conservador del traumatismo hepático cerrado: fístula biliar, hemobilia y biloma

The liver is the organ of the abdominal cavity that is most affected by both penetrating and blunt abdominal trauma. Up to 85% of patients suffering from blunt liver trauma may be candidates for conservative treatment. Nonsurgical management has led to a decrease in mortality, although this approach may give rise to a considerable number of complications.

We present the case of a 34-year-old male who had sustained multiple injuries in a motorcycle accident. Eco-FAST upon admission showed free fluid in the abdomen. Since the patient was hemodynamically stable, a computed tomography (CT) scan was performed (Fig. 1).

The patient was admitted to the Intensive Care Unit and remained hemodynamically stable. On the 5th day, abdominal ultrasound showed reorganization of the parenchymal

hematoma and extensive free fluid. Intra-abdominal pressure increased progressively, reaching 36 mmHg on the 10th day of hospitalization. Hemoglobin and hematocrit levels were stable, although leukocyte and PCR levels were high. Abdominal tomography demonstrated a significant increase in the amount of free fluid in the abdomen. Paracentesis was performed, and a choleperitoneum was diagnosed.

Emergency laparotomy confirmed the choleperitoneum, without revealing the origin of the bile leak after the administration of methylene blue through a cannula into the gallbladder. There was no disruption of the parenchyma. We proceeded with lavage and drainage, and a 400 cc biliary fistula became evident within the first 24 h.

ERCP was performed, which showed a non-dilated bile duct with extravasation of contrast at the proximal right hepatic

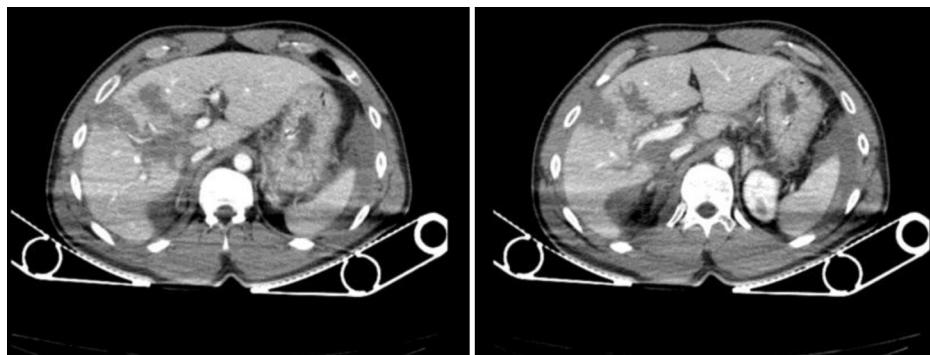


Fig. 1 – Hypodense lesions in the right liver lobe associated with grade III-IV lacerations of the liver, as well as a moderate amount of generalized free fluid.

* Please cite this article as: Casado Maestre MD, Bengoechea Trujillo A, Lizandro Crispín A, Rodríguez Ramos C, Fernández Serrano JL. Complicaciones en el manejo conservador del traumatismo hepático cerrado: fístula biliar, hemobilia y biloma. *Cir Esp.* 2013;91:537-539.

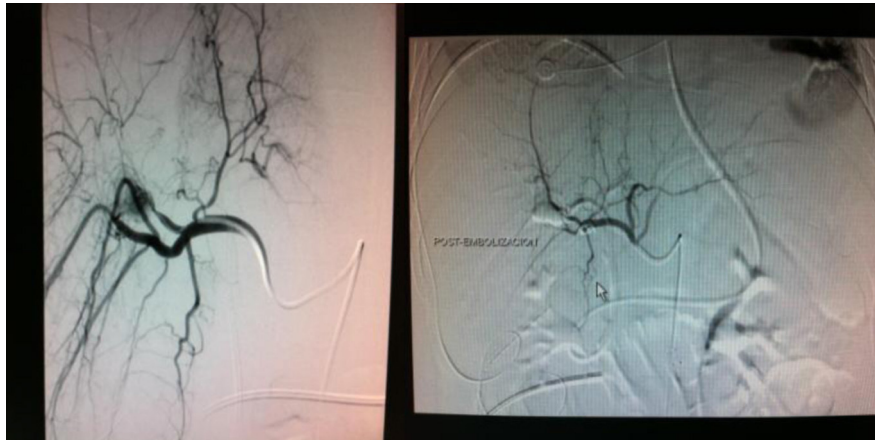

Fig. 2 – Pseudoaneurysm filled by branches of the right hepatic artery (arteries of segments VII and VIII). Endovascular coil embolization was performed. Right image: arteriography where no evidence of contrast leak is observed after embolization.

duct, which quickly passed to the subhepatic bed and the abdominal drainage catheter. A 7Fr/12 cm plastic prosthesis was inserted distal to the lesion.

The fistula output volume decreased to 200 cc in 24 h and remained without change on successive days. Thus, we decided on performing another ERCP, with decreased leak from the proximal right hepatic duct. A plastic 8.5Fr/10 cm prosthesis was inserted. After this procedure, there was no bile output through the subhepatic drain.

On the 28th day of hospitalization, the patient started to have bloody discharge through the nasogastric tube and hyperbilirubinemia (5 mg/dl). Upper gastrointestinal tract endoscopy revealed a clot from the second portion of the duodenum suggestive of hemobilia and biliary stent migration. A nasobiliary drainage catheter (7Fr) was inserted. Bleeding persisted, causing hemodynamic instability, and angiography was performed (Fig. 2).

After a few days, the patient started to have pain in the right hypochondrium, fever and leukocytosis. CT scan revealed an intraparenchymal abscess in segment VI that measured 7 cm×7.5 cm. Percutaneous drainage confirmed the diagnosis of infected biloma. A new ERCP revealed an intraparenchymatous leak in the right lobe. A plastic prosthesis was placed (8.5Fr and 10 cm). The drainage catheter was withdrawn on the 7th day.

Between 2.8% and 7.4% of patients treated with conservative management of liver trauma develop biliary complications.¹ When peritoneal irritation is suspected, CT is the diagnostic technique of choice in hemodynamically-stable abdominal trauma.^{2,3} In cases with inconclusive findings, diagnostic paracentesis or diagnostic peritoneal lavage may clarify the diagnosis.⁴

In patients with high-grade liver injuries that are managed conservatively, CT should be repeated 7–10 days after hospitalization; the repetition of this test is unnecessary in low-grade lesions (I-II-III AAST).⁵

The presence of a well-defined lesion with low attenuation suggests a biloma, which could be managed conservatively in most cases, or with percutaneous drainage if symptomatic (<1%).⁴

In those cases in which a biliary fistula develops, ERCP with biliary stent placement can achieve a resolution rate of 90%–100% of cases.^{6–8} Biliary stents have been shown to be superior to sphincterotomy in several published studies.¹

The presence of choleperitoneum and high intra-abdominal pressure require drainage of the abdominal cavity. One wonders whether abdominal percutaneous drainage would have been enough, although this option was ruled out in this case because of the time of development and the inability to determine associated injuries. Could laparoscopy have been a valid alternative? The answer is yes: the value of diagnostic laparoscopy in blunt abdominal trauma remains to be defined, but in selected patients it may contribute to the diagnosis and to performing therapeutic procedures.⁴

As for the prevalence of delayed bleeding during conservative management of closed liver trauma, this is seen in between 1.7% and 5.9% of cases and is usually associated with infectious liver complications or the formation of aneurysms.¹ Arteriography is the method of choice for hemobilia. Mohr et al. studied the complications that appear after angioembolization and found a rate of morbidity approaching 58%; biliary fistula, hepatic abscess and ischemic necrosis were the most frequent processes.⁹ The combination of liver trauma and ischemic necrosis predisposes the patient to biliary complications.¹

REFERENCES

1. Bala M, Gazalla SA, Faroja M, Bloom AI, Zamir G, Rivkind AI, et al. Complications of high grade liver injuries: management and outcome with focus on bile leaks. *Scand J Trauma Resusc Emerg Med.* 2012;20:20.
2. Gibson DE, Canfield CM, Levy PD. Selective nonoperative management of blunt abdominal trauma. *J Emerg Med.* 2006;31:215–21.
3. Stuhlfaut JW, Anderson SW, Soto JA. Blunt abdominal trauma: current imaging techniques and CT findings in patients with solid organ, bowel, and mesenteric injury. *Semin Ultrasound CT MR.* 2007;28:115–29.
4. Casanova D, Figueras J, Pardo F. *Traumatismo hepático en guía clínica de la Asociación Española de Cirujanos. Cirugía hepática.* Madrid: Ed. Arán; 2004: 299–314.

5. Ortega-Deballón P, Delgado-Millán MA, Jover-Novalón JM, Limones-Esteban M. Manejo diagnóstico en el tratamiento conservador del traumatismo abdominal. *Cir Esp.* 2003;73:233-43.
6. Singh V, Narasimhan KL, Verma GR, Singh G. Endoscopic management of traumatic hepatobiliary injuries. *J Gastroenterol Hepatol.* 2007;22:1205-9.
7. Lubezky N, Konikoff FM, Rosin D, Carmon E, Kluger Y, Ben-Haim M. Endoscopic sphincterotomy and temporary internal stenting for bile leaks following complex hepatic trauma. *Br J Surg.* 2006;93:78-81.
8. Anand RJ, Ferrada PA, Darwing PE, Bochicchio GV, Scalea TM. Endoscopic retrograde cholangiopancreatography is an effective treatment for bile leak after severe liver trauma. *J Trauma.* 2011;71:480-5.
9. Mohr AM, Lavery RF, Barone A, Bahramipour P, Magnotti LJ, Osband AJ, et al. Angiographic embolization for liver injuries; low mortality, high morbidity. *J Trauma.* 2003;55:1077-82.

María Dolores Casado Maestre^{a,*}, Ander Bengoechea Trujillo^a, Armando Lizandro Crispín^a, Claudio Rodríguez Ramos^b, José Luis Fernández Serrano^a

^aUnidad de Gestión Clínica de Cirugía General y del Aparato Digestivo, Hospital Universitario Puerta del Mar, Cádiz, Spain

^bServicio de Aparato Digestivo, Hospital Universitario Puerta del Mar, Cádiz, Spain

*Corresponding author.

E-mail address: chicacasado@hotmail.com (M.D. Casado Maestre).

2173-5077/\$ – see front matter

© 2012 AEC. Published by Elsevier España, S.L. All rights reserved.

Hybrid Transvaginal Ventral Hernia Repair

Eventroplastia transvaginal híbrida

The development of new techniques such as natural orifice surgery seeks to improve clinical and aesthetic results in different fields. It has been successfully used to performed procedures such as appendectomies, cholecystectomies, and oncologic colon resections.¹ Nevertheless, there are few published reports about the use of this approach in the management of ventral hernias.^{2,3}

We present the case of a 58-year-old woman with hypothyroidism, 2 vaginal deliveries and surgery for epigastric hernia who consulted for pain and a mass along the scar of the previous surgery. Abdominal examination discovered a recurrent hernia, which was reductible, along with an aponeurotic defect measuring 4 cm in diameter. We proceeded with the repair using a hybrid transvaginal approach, starting with the preoperative administration of 2 g of amoxicillin-clavulanate and perineal/vaginal lavage of diluted povidone-iodine solution.

With the patient in the modified Lloyd-Davies position, the surgeon stood on the left and the assistant surgeon stood between the patient's legs. Pneumoperitoneum was created with a transumbilical Veress needle, and then a 5-mm trocar was inserted in the left flank for the later use of forceps and the stapler to attach the prosthesis. Through the orifice of the Veress needle, a 3-mm trocar was introduced to provide access for mini-instruments (Fig. 1).

The patient was placed in forced Trendelenburg position. With the laparoscope (5 mm 0° optics, through the 5-mm port) an extra-long optical trocar (150 mm) was inserted through the posterior vaginal fornix (12 mm EndoPath[®] Xcel[™]), which we later used to insert the mesh and optics (10 mm and 30°). The transvaginal trocar was protected with a sterile plastic

sheath and the pouch of Douglas was washed with a povidone-iodine solution (Fig. 2). After releasing the omental adhesions of the hernia sac using the 2 abdominal ports as working channels and the transvaginal trocar to insert the 30° optic, we proceeded with the mesh placement (Ethicon Physiomesh[™] Flexible Composite Mesh). The patch was rolled up for insertion through the vaginal trocar without any further protection and subsequently fixed with 2 crowns of absorbable straps (Ethicon Securestrap[™] 5 mm Absorbable Strap Fixation Device) (Fig. 1). Afterwards, the 3 and 10 mm trocars were removed under direct vision (5 mm 0° optic through the trocar of the left flank) and the vaginal opening was closed vaginally with 2 polyglactin sutures (910 2/0) and the abdominal skin with monofilament (3/0). The patient had a favourable postoperative course and was discharged from the hospital 36 h after surgery and continued to be asymptomatic one month later.

The benefits of the laparoscopic approach in the treatment of ventral and abdominal wall hernias have been demonstrated in several studies, including lower risk of wound infection and shorter hospital stay, with recurrence rates that are lower than open surgery in many reports.⁴ Furthermore, in order to minimize parietal aggression, mini-instruments have been developed, which allow for dissecting, resecting and manipulating different structures within the abdominal cavity through minimal 2-3 mm incisions with accuracy and safety. The transvaginal approach aims to avoid abdominal incisions and provide aesthetic, pain-related and structural benefits.⁵

Thus, the combination of the benefits of these treatment approaches for abdominal wall disease is the basis for the

* Please cite this article as: Bruna M, Noguera J, Martínez I, Oviedo M. Eventroplastia transvaginal híbrida. *Cir Esp.* 2013;91:539-541.