

## Image of the month

Giant Hydatid Cyst. Nenuphar Sign<sup>☆</sup>

## Quiste hidatídico gigante. Signo del nenúfar

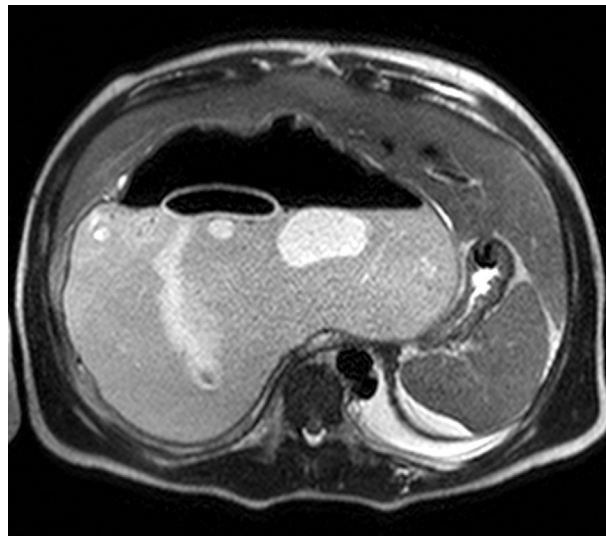
Teresa Marquina,<sup>a,\*</sup> Juan José Fondevila,<sup>b</sup> Mikel Prieto,<sup>a</sup> Andrés Valdivieso<sup>a,c</sup><sup>a</sup> Servicio de Cirugía General y del Aparato Digestivo, Hospital Universitario de Cruces, Barakaldo, Bizkaia, Spain<sup>b</sup> Servicio de Radiodiagnóstico, Hospital Universitario de Cruces, Barakaldo, Bizkaia, Spain<sup>c</sup> Unidad de Cirugía Hepatobiliar y Trasplante Hepático, Hospital Universitario de Cruces, Barakaldo, Bizkaia, Spain

Figure 1

The patient is a 17-year-old male from Morocco with a history of hydatid cyst that had been treated surgically in 2006. He was admitted to our Emergency Department due to abdominal pain, vomiting and fever. Physical examination revealed a palpable mass in the right hypochondrium. Abdominal MRI demonstrated a large hydatid cyst that appeared to be complicated, showing the characteristic image of the “water-lily sign” (Fig. 1). He was scheduled for surgery, and pericystectomy and segmentectomy were carried out with resection of sections I, V, VI and VII. During the postoperative period, the patient presented stenosis of the left suprahepatic vein that was resolved by inserting a stent by interventional radiology, with a favorable course.

<sup>☆</sup> Please cite this article as: Marquina T, Fondevila JJ, Prieto M, Valdivieso A. Quiste hidatídico gigante. Signo del nenúfar. Cir Esp. 2013;91:605.

\* Corresponding author.

E-mail address: [teresa.marquinatobalina@osakidetza.net](mailto:teresa.marquinatobalina@osakidetza.net) (T. Marquina).

2173-5077/\$ – see front matter © 2013 AEC. Published by Elsevier España, S.L. All rights reserved.