

Image of the month

Massive Hepatic Abscess in a Liver Transplant Patient Secondary to a Late Arterial Graft Thrombosis[☆]

Absceso hepático masivo en paciente trasplantado hepático secundario a trombosis arterial tardía del injerto

Rebeca Sanabria,^{*} Alejandro Manrique, Naim Fakh, Carlos Jimenez

Servicio de Cirugía General y Digestivo y Trasplante de Órganos Abdominales, Madrid, Spain

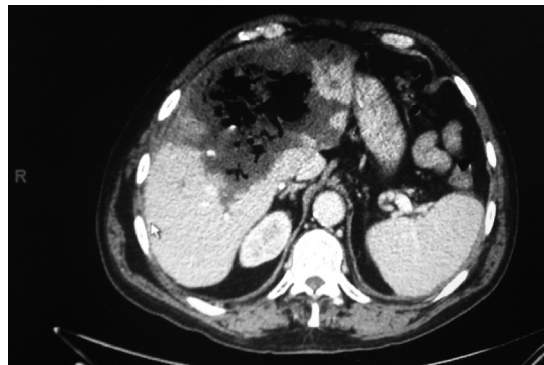


Figure 1

The following is the case of a 61-year-old man who had a liver transplant due to alcoholic liver disease in February 2011. He presented with a two-week history of fever and diarrhea, with continuous hypotension and with no additional pathological products. Laboratory tests showed the presence of leukocytosis, a marked increase of transaminases and deterioration of liver function. An abdominal CT scan revealed a complete arterial thrombosis of the liver transplant with a massive hepatic abscess of the left hepatic lobule with extension to the anterior segment of the right lobule and bilateral pneumobilia. This was evacuated successfully awaiting a liver retransplant (Fig. 1).

[☆] Please cite this article as: Sanabria R, Manrique A, Fakh N, Jimenez C. Absceso hepático masivo en paciente trasplantado hepático secundario a trombosis arterial tardía del injerto. Cir Esp. 2013;91:e61.

^{*} Corresponding author.

E-mail address: rebecasanabria@gmail.com (R. Sanabria).