

Review article

Disconnected Pancreatic Duct Syndrome[☆]Jose Manuel Ramia,^{a,*} Joan Fabregat,^b Manuel Pérez-Miranda,^c Joan Figueras^d^aUnidad de Cirugía Hepatobiliopancreática, Servicio de Cirugía General y Aparato Digestivo, Hospital Universitario de Guadalajara, Guadalajara, Spain^bUnidad de Cirugía Hepatobiliopancreática, Servicio de Cirugía General y Aparato Digestivo, Hospital Universitario de Bellvitge, Barcelona, Spain^cServicio de Gastroenterología, Hospital Río Hortega, Valladolid, Spain^dUnidad de Cirugía Hepatobiliopancreática, Servicio de Cirugía General y Aparato Digestivo, Hospital Josep Trueta, Gerona, Spain

ARTICLE INFO

Article history:

Received 6 February 2013

Accepted 19 February 2013

Available online 14 February 2014

Keywords:

Disconnected pancreatic duct syndrome

Pancreas

Surgery

Pancreatitis

Review

A B S T R A C T

Disconnected pancreatic duct syndrome (DPDS) is characterised by disruption of the main pancreatic duct with a loss of continuity between the pancreatic duct and the gastrointestinal tract caused by ductal necrosis after severe acute necrotising pancreatitis treated medically, by percutaneous drainage, or necrosectomy.

There are no clear epidemiological data on the real incidence of DPDS; approximately 10%–30% of patients with severe acute pancreatitis could develop DPDS. The existing literature is scarce, the terminology is confusing and therapeutic algorithms are not clearly defined. Both endoscopic management and surgical management have been described.

We have performed a systematic review of the literature on DPDS.

© 2013 AEC. Published by Elsevier España, S.L. All rights reserved.

Síndrome del ducto pancreático desconectado

R E S U M E N

La desconexión del ducto pancreático, o síndrome del ducto pancreático desconectado (SDPD), es una entidad clínica que consiste en la existencia de una situación anatómica en la que hay ausencia de la continuidad del conducto pancreático entre el tejido pancreático viable y el tracto gastrointestinal, causada por necrosis ductal tras pancreatitis aguda grave tratada mediante necrosectomía, drenaje percutáneo o médicamente.

No hay datos epidemiológicos claros sobre la incidencia real de SDPD. Se ha postulado que entre un 10 y un 30% de los pacientes con pancreatitis aguda grave desarrollan un SDPD.

La literatura existente sobre este tema es escasa, los términos empleados son confusos y los algoritmos terapéuticos son poco claros. Las opciones terapéuticas son endoscópicas y quirúrgicas.

Hemos efectuado una revisión sistemática de la literatura sobre SDPD.

© 2013 AEC. Publicado por Elsevier España, S.L. Todos los derechos reservados.

Palabras clave:

Síndrome del ducto desconectado

Páncreas

Cirugía

Pancreatitis

Revisión

[☆] Please cite this article as: Ramia JM, Fabregat J, Pérez-Miranda M, Figueras J. Síndrome del ducto pancreático desconectado. Cir Esp. 2014;92:4-10.

* Corresponding author.

E-mail address: jose_ramia@hotmail.com (J.M. Ramia).

2173-5077/\$ – see front matter © 2013 AEC. Published by Elsevier España, S.L. All rights reserved.

A clinical entity, which had already been referred to in medical literature, consisting of an anatomical situation where there is no continuity of the pancreatic duct between viable pancreatic tissue and the gastrointestinal tract, caused by duct necrosis after severe acute pancreatitis and treated medically, by percutaneous drainage or by necrosectomy,¹⁻⁸ was named for the first time by Kozarek et al. as disconnection of the pancreatic duct or disconnected pancreatic duct syndrome in 1991. The isolated viable pancreatic segment continues its exocrine function, causing inflammatory intra or peripancreatic collections or an external pancreatic fistula.⁵⁻¹¹

In addition to acute pancreatitis, other possible aetiologies of DPDS could be chronic pancreatitis, pancreatic trauma, pancreas divisum and other causes.^{2,9,12,13} Other terms used to define this syndrome are: disconnected pancreatic tail syndrome and disconnected left pancreatic remnant.²

There are no clear epidemiological data on the real incidence of DPDS; approximately 10% and 30% of patients with severe acute pancreatitis could develop DPDS. The incidence of patients diagnosed with DPDS is increasing.¹¹ Existing literature is scarce; the terminology is confusing and therapeutic algorithms are not clearly defined.^{2,4,7,9} We have performed a systematic review of the literature on DPDS.

Search

We carried out a search on Pubmed (1966–2012) for articles in English and Spanish using the terms «disconnected pancreatic duct syndrome» (17) and «disconnected pancreas» (29) and only 15 of the articles we revised were relevant. Given the few citations, the references of these articles were revised for more information on this subject which had not been included in the search terms. Finally, we revised a total of 23 articles. There are no randomised trials, clinical guides or meta-analysis of DPDS.

Definition

In acute pancreatitis, pancreatic glandular necrosis has traditionally been considered a determinant of severity. However, in some patients, necrosis of the ductal epithelium is more severe and significant than glandular necrosis.⁶ DPDS occurs after a variable percentage of pancreatic parenchyma has necrosed, usually in a central location, which causes a ductal lesion that results in the distal remnant becoming disconnected from the pancreatic duct and its exocrine production being unable to drain into the gastrointestinal tract. All of this results in the formation of an intra-abdominal collection or external pancreatic fistula (EPF).^{5,6,14} When there is an EPF there is usually no communication between the fistula and the proximal duct and the fistula is exclusively fed by the distal remnant.¹⁴ In Howard's series of 27 patients with DPDS, 70% present with EPF and 30% with intra-abdominal collection.⁵

DPDS usually occurs after surgical necrosectomy due to acute pancreatitis or walled-off pancreatic necrosis (WOPN) (50%–75% of patients with DPDS).² 15%–25% of patients who have undergone necrosectomy present EPF.^{14,15} If these data

are real, the question is why do we not find more patients with DPDS,^{2,9} since it can occur in patients treated with percutaneous drainage as well as in operated patients. It is likely that paucisymptomatic or wrongly diagnosed patients are the reason for the low number of patients diagnosed with DPDS.² The existence of unoperated cases indicates that the cause of DPDS is the ductal damage caused by pancreatitis per se and not surgical or percutaneous intervention.

Diagnosis

Correctly diagnosing DPDS is essential, as its treatment is different from that used in other post-pancreatitis intra or peripancreatic collections, pseudocysts, for example, or post-necrosectomy EPF necrosectomies caused by ductal obstruction which can be resolved with a transpapillary prosthesis placed using ERCP,^{7,15} and from so-called partial disruptions of the duct, which should not be considered DPDS as they are not really ductal disconnections.¹³ This difficulty in diagnosis makes it enormously complicated to reach conclusions when results are compared, as it is likely that wrongly diagnosed patients have been included in the series.⁸

The existence on computerised axial tomography (CT) of a thin and small bridge of viable pancreatic tissue, compressed on the lower or posterior side, can suggest the possibility of a misdiagnosis of DPDS as this is showing us a partial disruption.⁵ Fluid collections which compress the gland usually displace the duct that enters them at an oblique, not a straight, angle to the collection wall, as occurs in DPDS.⁶

Methods used for diagnosing DPDS are: CT, nuclear magnetic resonance (MRI) and endoscopic retrograde cholangio-pancreatography (ERCP).^{2,6,16} It has been suggested that ERCP be replaced with nuclear magnetic cholangio resonance (MRC) with secretin stimulation, but the former is more sensitive in demonstrating ductal leakage, although it is more invasive.^{5,6,9,10,13,14,16} Fistulography can be useful in some cases where there is EPF to differentiate between a terminal and lateral fistula.⁵

The traditional diagnostic criteria for DPDS are: discontinuity of the main pancreatic duct with evidence of viable distal pancreatic tissue and presence of a persistent fluid collection in the imaging methods, or discontinuity of the main pancreatic duct on ERCP and the impossibility of accessing or cannulating the distal duct.^{4,7-9,11,14} A priori and traditionally, when the endoscopist was unable to cross the disconnected area with a guide or drain it was evidence that the duct was completely disconnected and not merely disrupted, although nowadays technical sophistication sometimes makes it possible for the disconnected distal remnant to be cannulated.^{8,9,11}

More specific criteria have been proposed so that we have a DPDS if:

- The CT shows necrosis or a collection in the neck or body of the pancreas of at least 2 cm of pancreas and viable distal pancreatic tissue from the area of necrosis, or a pancreatic duct entering the collection at an angle of 90°.^{2,6,14}
- Extravasation of contrast material injected into the pancreatic duct in the pancreatography obtained by ERCP,

endoscopic or intraoperative ultrasound, or complete section/disconnection of the duct in the distal remnant.^{2,6,14}

In a CT scan performed two weeks after the onset of acute pancreatitis, some details suggestive of DPDS could already be recognised, but they were not definite.⁸ The distal pancreatic duct can be seen to be either dilated or otherwise in the different imaging tests.⁶ Necrosis of less than 2 cm with no initial ductal lesion can heal without involving the duct but subsequently fibrosis and tissue scarring can cause stenosis of the pancreatic duct which can result in recurrent pancreatitis, although this cannot be referred to as DPDS.^{2,6,8}

The most common location of DPDS is the neck of the pancreas, especially in gallstone pancreatitis; this might be due to this area of the pancreas being particularly vascular.^{2,9,10} Only the dorsal pancreatic artery feeds this area, whereas other regions of the pancreas are vascularised by more than one artery. A disruption of blood flow during pancreatitis causes necrosis and it is possible for DPDS to develop as a result of a ductal lesion.⁸ Although the anatomical disposition with sharp angulation of the duct from upward anterior to transverse posterior can also contribute towards this being the most affected area.¹⁰

Clinical Features

The existence of a collection or EPF after a necrosectomy or drainage of infected pancreatic necrosis which does not resolve within a reasonable period of time should suggest the possibility of DPDS.⁴ The volume of the fistula dictates the amount of viable pancreatic tissue.⁴

The clinical features are not specific and the following symptoms have been described: abdominal pain, nausea and vomiting, dietary intolerance and weight loss.²

Lithiasis is the most frequent aetiology in pancreatitis which causes DPDS.² 50% of patients with WOPN treated using percutaneous drainage develop DPDS.^{3,17}

Patients with DPDS are at greater risk of diabetes mellitus, metabolic and nutritional problems due to loss of proteins and electrolytes, and portal hypertension.⁴ The following

complications associated with DPDS have been described: recurrent pancreatic fluid collections, ascites and pseudoaneurysms.³

Treatment

Traditionally, it was thought that DPDS should be treated with surgery.^{4,9} But there are currently many treatment options (Table 1).

DPDS can present as a peripancreatic collection or an EPF. Treatment is different in each case. If the patient presents with a collection which does not increase in size and is asymptomatic, in principle a wait-and-see approach can be taken although symptoms usually develop as the patient is monitored.¹⁰ If the collection presents symptoms (pain, fever, recurrent pancreatitis) these must be treated, usually with endoscopic techniques if is feasible (internal drainage [cystogastric or cystoduodenostomies] or a prosthesis up to the ductal remnant). Puncture by percutaneous drainage must be avoided as this will cause an EPF which will be difficult to resolve.¹³

In the case of an EPF due to DPDS the steps are: medical stabilisation, establishing the anatomy of the ductal disruption and implementing medical, endoscopic or surgical treatment.^{10,17} Medical management (nutrition and somatostatin analogues) is slow and has a low success rate; endoscopic techniques are complex and are not always feasible; and surgery is technically difficult.^{4,15,17} EPF usually occurs through one of the necrosectomy drains or previous percutaneous drainage.^{2,10} There are no guidelines on the optimal treatment for EPF due to DPDS. It usually starts with medical treatment, then endoscopic techniques are used and if these fail, surgery is considered.⁹

We need to wait for at least six weeks before considering surgical treatment as we postpone surgery until pancreatic inflammation has subsided and the EPF is firmly established.^{5,10,14,18} Pearson et al. consider surgery in the case of a fistula greater than 100 ml/day which persists three months after the onset of DPDS.⁴

We have summarised the various endoscopic and surgical techniques:

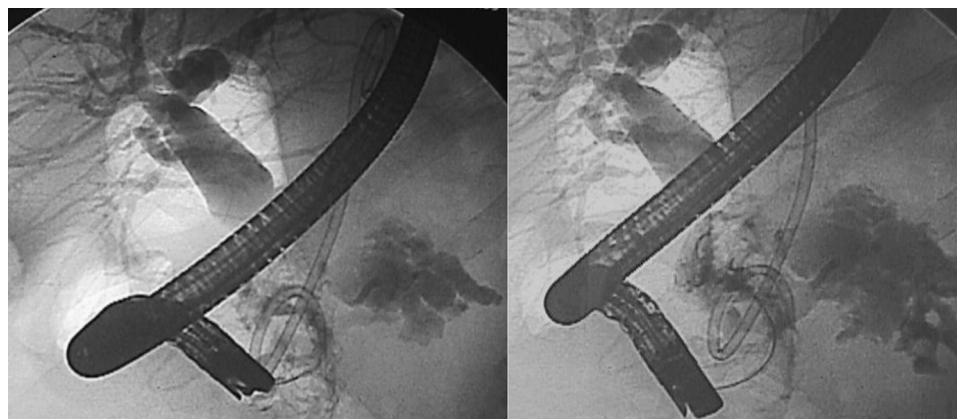


Fig. 1 – SDPD:ERCP:biliary tract dilatation and leak in pancreatic body.

Endoscopic Techniques

Endoscopic techniques are not diagnostic but are now therapeutic for DPDS.^{4,9} Furthermore, when they do not completely resolve the DPDS they can serve as a bridge prior to surgery and improve the patient's local and general conditions.¹⁴ The success rate of older series, without clearly defining DPDS, varies between 25% and 37% but has currently improved reaching 61%–75%. The results are particularly good when there are collections, but less good when there is EPF.^{2,4,9,11,17} Those who defend endoscopic techniques highlight good results, no mortality, low morbidity (25%) and although the relapse rate is close to 50% there is the possibility of repeating the procedure^{9,11,17} (Fig. 1).

The basic initial technique consists of ERCP and placement of a prosthesis but the distal remnant must be drained, which is usually very difficult. We should remember that simple transpapillary drainage is not helpful. As we have mentioned, traditionally it was considered that being unable to cannulate the distal remnant was diagnostic of DPDS; endoscopic techniques having been perfected, meaning that currently, in some patients, it is possible to cannulate the ductal remnant (10%–25%).^{9,16} And, as we have mentioned, ductal transpapillary drainage is very effective in lateral fistulas which are not true DPDS but it is not usually possible to resolve the terminal fistulas.¹⁴

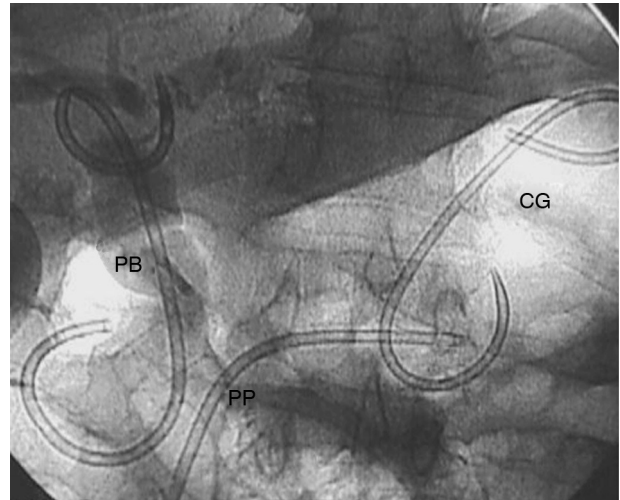


Fig. 2 – Patient Fig. 1. PP: pancreatic prosthesis. PB: biliary prosthesis. CG: cystogastrostomy.

When distal cannulation has not been feasible, there are other technical options in the literature based on internal drainage by ultrasound endoscopy; i.e., locating the collection and the duct by means of ultrasound endoscopy and then

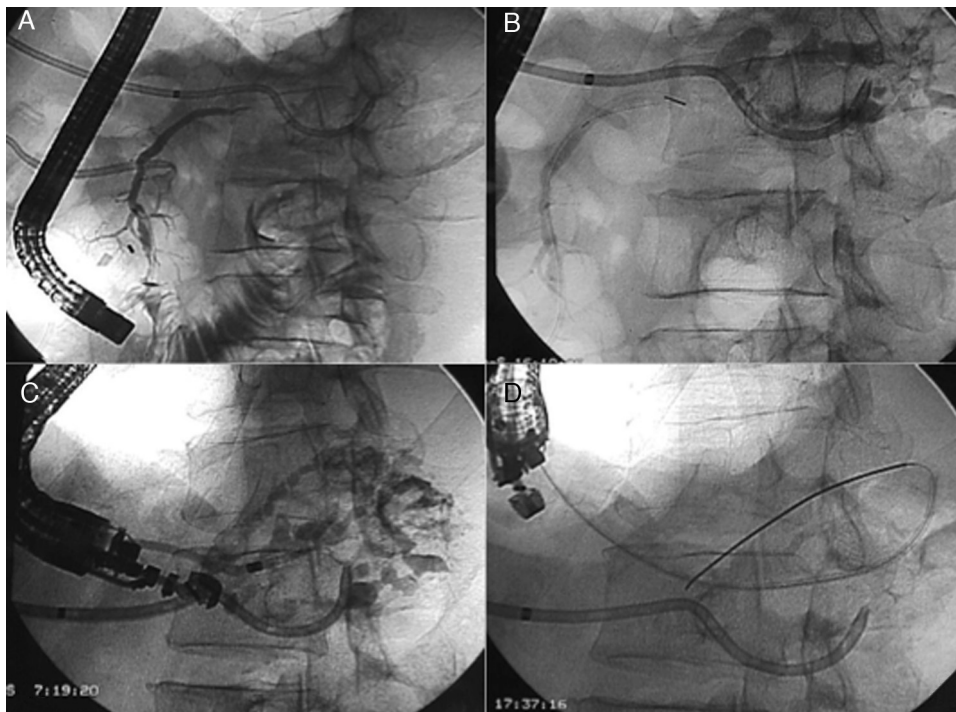


Fig. 3 – (A and B) Endoscopic retrograde pancreatography (ERCP): (A) Duct of Wirsung with complete transection in juxta-cephalic body with the head of the duct opacified, and no fill in body and tail. (B) Endoscopic catheter tip (sphincterometer) in the transection. Opacification of residual collection and Wirsung duct in the tail via percutaneous catheter. (C and D) Opacification of residual collection and Wirsung duct in the tail via the percutaneous catheter. (C and D) Endosonographic pancreatography (ESCP) via transgastric puncture. (C) Injection of contrast through a dilator introduced using transgastric Seldinger up to the duct of Wirsung in the tail. (D) Plastic pancreatogastric prosthesis, on guide (pancreatico-gastrostomy).

connecting it with the digestive tract (stomach or duodenum), placing a prosthesis which joins both.^{19,20} The different options are: performing transgastric pancreatography guided by endoscopic ultrasound to locate the duct and then drain the dilated duct via transgastric route^{9,20}; perform endoscopic ultrasound guided drainage from the fourth duodenal portion^{9,19,21} or use rendezvous techniques combining interventional and endoscopic radiology.¹⁷ 20%–50% of patients who have undergone endoscopic ultrasound drainage develop diabetes mellitus.⁹

In cases treated with internal drainage, there is no consensus on the type of drain that should be used. Permanent drains between the collection and the digestive tract have been used with good results, although there is the danger of migration or infection.^{3,17} Prostheses which are not permanent can become obstructed and cause therapeutic failures in the short or medium term.¹³

Embolisation of the distal pancreatic duct with cyanoacrylate has been performed in very few patients with acceptable results: although it does close the EFP, it does not solve the problem of the disconnected distal remnant.^{10,14,17,22,23}

Surgical Techniques

Surgery can be considered the definitive solution in the event that endoscopic techniques fail or as a first option.¹⁰ The surgical treatment of DPDS is criticised principally because of its rate of morbidity (0%–14%) and mortality (0%–8%); its main advantage is its 80% success rate.^{2,10,15} Resection techniques (distal pancreatectomy with or without splenectomy) and by-pass techniques (Roux-en-Y fistulojejunostomy, pancreaticojejunostomy or pancreaticogastrostomy) are possible surgical options.^{2,4,5,7,14} It is recommended that a cholecystectomy be performed if this has not taken place previously.⁵

By-pass techniques have several advantages: in theory they are simpler (less intraoperative bleeding, less transfusion and less operating time), they have a lower rate of postoperative complications (6%) and shorter average hospital stay, and they preserve endocrine and exocrine function with a lower rate of postoperative diabetes.^{2,5,12,14} Although in the series of Murage et al., they present a higher rate of intra-abdominal abscesses than resection techniques.² The average success rate of by-pass techniques as a whole is around 80%.² In the only series which combines the three by-pass options no differences are observed in terms of results using any one particular technique.²

In the series of Pearson et al. of seven fistulojejunostomies (FJ) there was no recurrence of pancreatitis, dilatation of the pancreatic duct, or exocrine insufficiency, but half the patients presented with moderate endocrine insufficiency, which was treated with oral anti-diabetic drugs.⁴ In another short series of FJ, there was a 77%–100% success rate.^{10,18} The authors of these series on FJ underline the need to have a well-formed fibrous tract in order to perform the FJ, it is therefore important to wait a reasonable amount of time before undertaking the operation.^{5,18} Murage et al. recommend using a duct-to-mucosa by-pass as they believe this to be better than FJ, although it is sometimes difficult to perform, as it calls for a small pancreatic resection.²

Table 1

Author	No.	Age	Gender (% males)	Aetiology, n (%)	Previous necrosectomy	Presentation of DLPR	Type of surgery/endo.	Morb. (%)	Mort. (%)	Success (%)	Follow-up (months)
<i>Surgical series</i>											
Howard (2001)	27	50	48	27 PA (100)	ND	Pseudocyst: 70% Pancreatic fistula: 30%	14 PD 13 DI	ND ND	8 PD 7 DI	93 PD 100 DI	PD: 19 DI: 17
Murage (2010)	76	52	57	59 PA (73) 17 PC (22)	42/59 (71%)	Pseudocyst: 53% Pancreatic fistula: 34% Pancr. obstructive: 13% Fistula: 100%	42 PD 34 DI	14 PD 6 DI	0	74 PD 82 DI	22
Pearson (2012)	7	62	71	7 PA (100)	7/7 (100%)		7 DI	15	0	85 DI	9
<i>Endoscopic series</i>											
Pelaez (2008)	31	53	48	31 PA (100)	ND	ND	26 endo 5 surgery	ND	0	73 endo	6.5
Irani (2012)	15	51	80	15 PA (100)	ND	Pancreatic fistula: 100%	15 endo	27	0	80	25

DI: internal bypass; Endo: endoscopy; ND: not available; PA: acute pancreatitis; PD: distal pancreatectomy.

The main disadvantage of pancreatic resection is the loss of pancreatic tissue, as this can further compromise exocrine and endocrine function which has often already been damaged, and the difficulty of a resection in an organ with prior pancreatitis, generally increasing the incidence of intraoperative bleeding and morbidity (19%) compared to by-pass techniques.^{4,10} Howard et al. recommend resection when there is thrombosis of the splenic vein or left portal hypertension, when malignancy cannot be ruled out and in patients with obstructive pancreatitis.^{2,8} Murage adds a further indication: a very small ductal remnant (<6 cm).² The success rate of resection techniques is approximately 75%.²

Recurrence of pancreatic fistula is greater in the pancreatectomy group.⁵ There is mixed data on the rate of re-laparotomy for both types of techniques in the few published series⁵ (Figs. 1-3; Table 1).

Conclusion

DPDS is a clinical entity that usually occurs after severe acute pancreatitis and which presents with the appearance of a collection or EFP. Correct diagnosis is essential and it should be distinguished, from pancreatic pseudocyst, partial ductal disruption, WOPN and other post pancreatitis symptoms by CT scan and MRC. Traditionally treatment was surgical but now it can be endoscopic, using either ERCP or, usually, internal endoscopic ultrasound guided drainage. Endoscopic techniques present low morbimortality but are less successful in the long term than surgical techniques. By-pass or resection surgery is more effective but has greater morbimortality. There are no internationally- agreed therapeutic algorithms but it is increasingly more common to use endoscopic techniques first and if they fail, consider surgery. DPDS is another disease where it has been demonstrated that multidisciplinary collaboration among radiologists, gastroenterologists and surgeons is fundamental for the care of patients with complex pancreatic disease.

Conflict of Interests

The authors have no conflict of interests to declare.

REFERENCES

1. Kozarek RA, Ball TJ, Patterson DJ, Freeny PC, Ryan JA, Traverso LW. Endoscopic transpapillary therapy for disrupted pancreatic duct and peripancreatic fluid collections. *Gastroenterology*. 1991;100:1362-70.
2. Murage KP, Ball CG, Zyromski NJ, Nakeeb A, Ocampo C, Sandrasegaran K, et al. Clinical framework to guide operative decision making in disconnected left pancreatic duct disruption (DLPR) following acute or chronic pancreatitis. *Surgery*. 2010;148:847-57.
3. Varadarajulu S, Wilcox M. Endoscopic placement of permanent indwelling transmural stents in disconnected pancreatic duct syndrome: does benefit outweigh the risks. *Gastrointest Endosc*. 2011;74:1408-12.
4. Pearson EG, Scaife CL, Mulhivill SJ, Glasgow RE Roux-en-Y drainage of a pancreatic fistula for disconnected pancreatic duct syndrome after acute necrotizing pancreatitis. *HPB*. 2012;14:26-31.
5. Howard TJ, Rhodes GJ, Selzer DJ, Sherman S, Fogel E, Lehman GA Roux-en-Y internal drainage is the best surgical option to treat patients with disconnected duct syndrome after severe acute pancreatitis. *Surgery*. 2001;130:714-21.
6. Sandrasegaran K, Tann M, Jennings SG, Maglinte DD, Peter SD, Sherman S, et al. Disconnection of the pancreatic duct: an important but overlooked complication of severe acute pancreatitis. *Radiographics*. 2007;27:1389-400.
7. Tann M, Maglinte D, Howard TJ, Sherman S, Fogel E, Madura JA, et al. Disconnected pancreatic duct syndrome: imaging findings and therapeutic implications in 26 surgically corrected patients. *J Comp Assist Tom*. 2003;27:577-82.
8. Howard TJ, Moore SA, Saxena R, Mathews DE, Schmidt CM, Wiebke EA. Pancreatic duct strictures are a common cause of recurrent pancreatitis after successful management of pancreatic necrosis. *Surgery*. 2004;136:909-16.
9. Pelaez-Luna M, Vege SS, Petersen BT, Chari ST, Clain JE, Levy MJ, et al. Disconnected pancreatic tail syndrome in severe acute pancreatitis: clinical and imaging characteristics and outcomes in a cohort of 31 cases. *Gastrointest Endosc*. 2008;68:91-7.
10. Morgan KA, Adams DB. Management of internal and external pancreatic fistulas. *Surg Clin N Am*. 2007;87:1503-13.
11. Lawrence C, Howell DA, Stefan AM, Conklin DE, Lukens FJ, Martin RF, et al. Disconnected pancreatic tail syndrome: potential for endoscopic therapy and results of long-term follow-up. *Gastrointest Endosc*. 2008;67:673-9.
12. Chinnery GE, Thomson SR, Ghimenton F, Anderson F. Pancreatico-enterostomy for isolated pancreatic duct disruption. *Injury*. 2008;39:50-6.
13. Deviere J, Antaki F. Disconnected pancreatic tail syndrome: a plea for multidisciplinary. *Gastrointest Endosc*. 2008;67:680-2.
14. Solanki R, Koganti SB, Bheerappa N, Sastry RA. Disconnected duct syndrome: refractory inflammatory external pancreatic fistula following percutaneous drainage of an infected peripancreatic fluid collection. A case report and review of the literature. *JOP*. 2011;12:177-80.
15. Boerma D, Rauws EAJ, van Gulik TM, Huijbregte K, Obertop H, Gouma DJ. Endoscopic stent placement for pancreaticocutaneous fistula after surgical drainage of the pancreas. *Br J Surg*. 2000;87:1506-9.
16. Gilliams AR, Kurzawinski T, Lees WR. Diagnosis of duct disruption and assessment of pancreatic leak with dynamic secretin-stimulated MR colangiopancreatography. *AJR*. 2006;186:499-506.
17. Irani S, Gluck M, Ross A, Gan I, Crane R, Brandabur JJ, et al. Resolving external pancreatic fistulas in patients with disconnected pancreatic duct syndrome: using rendezvous techniques to avoid surgery. *Gastrointest Endosc*. 2012;76:586-93.
18. Bassi C, Butturini G, Salvia R, Contro C, Valerio A, Falconi M, et al. A single-institution experience with fistulojejunostomy for external pancreatic fistulas. *Am J Surg*. 2000;179:203-6.
19. Zhong N, Topazlan M, Petersen BT, Baron TH, Charl ST, Gleeson FC, et al. Endoscopic drainage of pancreatic fluid collections into fourth portion of duodenum: a new approach to disconnected pancreatic duct. *Endoscopy*. 2011;43 Suppl.:E45-6. UCTN.

20. Will U, Fuehdner F, Goldamann B, Mueller AK, Wanzar I, Meyer F. Successful transgastric pancreaticography and endoscopic ultrasound-guided drainage of a disconnected pancreatic tail syndrome. *Ther Adv Gastroenterol.* 2011;4:213-8.
21. Topazian M. Endoscopic ultrasound-guided drainage of pancreatic fluid collections (with video). *Clin Endosc.* 2012;45:337-40.
22. Findeiss LK, Brandabur J, Traverso LW, Robinson DH percutaneous embolization of the pancreatic duct with cyanoacrylate tissue adhesive in disconnected duct syndrome. *J Vasc Interv Radiol.* 2003;14:107-11.
23. Seewald S, Brand B, Groth S. Endoscopic sealing of pancreatic fistula by using N-butyl-2-cyanoacrylate. *Gastrointest Endosc.* 2004;59:463-70.