

10. Molero R. Chronic pancreatitis. *Gastroenterol Hepatol.* 2006;29:85-90.

Antonio Palomeque Jiménez*, Beatriz Pérez Cabrera,
Francisco Navarro Freire, José Antonio Jiménez Ríos

Servicio de Cirugía General y del Aparato Digestivo, Unidad de
Cirugía Hepatobiliopancreática, Hospital Universitario San Cecilio,
Granada, Spain

*Corresponding author.

E-mail address: apalomeque2002@hotmail.com
(A. Palomeque Jiménez).

2173-5077/\$ – see front matter

© 2013 AEC. Published by Elsevier España, S.L. All rights reserved.

Laparoscopic Duodenojejunostomy as a Treatment for Superior Mesenteric Artery Syndrome



Duodenoyeyunostomía laparoscópica como tratamiento del síndrome de la arteria mesentérica superior

Wilkie's syndrome or superior mesenteric artery (SMA) syndrome was first described in 1842 by Rokitanski, although it was Wilkie who published the first series of 75 patients in 1927.¹ It is a rare cause of upper intestinal obstruction caused by compression of the third part of the duodenum between the abdominal aorta and superior mesenteric artery at its origin. We present the case of a patient with this syndrome who had initially been treated conservatively but later required surgical treatment due to persisting symptoms.

The patient is a 29-year-old woman, with no medical or surgical history of interest, who, over the course of the previous 18 months, had presented postprandial fullness and abdominal distension, accompanied by nausea and occasional vomiting.

She came to the Emergency Department due to intolerance to oral intake, epigastric pain and bilious vomiting, which had begun abruptly. She was hemodynamically stable with mild signs of dehydration. Abdominal examination was normal, and the work-up showed normal blood tests. Simple radiography (Fig. 1A) revealed gastric dilatation. Conservative treatment was started with no oral intake, nasogastric suction and fluid therapy. An upper gastrointestinal (GI) series (Fig. 1B) showed that the esophagus, stomach and duodenal bulb had normal characteristics. There was, however, difficult emptying in the third part of the duodenum, which was consistent with functional disorder or SMA. On magnetic resonance imaging (MRI) study, the angle between the SMA and aorta was observed to be 17°.

The patient evolved favorably and a clinical follow-up was scheduled. During the following year, however, the symptoms reappeared with greater intensity. At this stage, surgical treatment was decided on after an upper GI series that confirmed the diagnosis.

The patient was operated on laparoscopically using 4 trocars. The procedure included dissection of the duodenal c-loop with an infra-mesocolic approach and mechanical duodenojejunostomy between the second and third parts of the duodenum and the jejunum, about 25 cm away from the angle of Treitz (Fig. 2A and B) with a 45 mm linear endostapler using 2.5 mm staples (white load). The postoperative period was uneventful, and the patient was discharged on the third day post-op with normal digestive tolerance.

Another upper GI series performed 3 months after the surgical intervention showed that the contrast passed from the normal-sized duodenum to the jejunal loops, with no images of stenosis. Two years after the operation, the patient remains asymptomatic.

The possible causes of SMA syndrome are debilitating disease (AIDS, cancer), eating disorders, postoperative effects (orthopedic surgeries and adhesiolysis due to obstruction of the small intestine), severe trauma and spinal column deformities. Recently, cases have been reported related to rapid weight loss after bariatric surgery.²

The incidence of SMA syndrome is 0.2%. It may occur at any age, but is most common in adolescents and young adults, especially women (2:1).³

Symptoms are nonspecific and may include postprandial epigastric pain, bloating, early satiety, nausea and vomiting. The pain is alleviated in the knee-chest position and in left lateral decubitus.⁴ The causes of death are due to severe electrolyte alterations, gastric perforation, obstructive bezoar or gastric or portal pneumatosis.³

Radiologic studies are essential. Historically, upper GI series and arteriography were the standard diagnostic tests, but more recently, CT angiography and MRI have shown greater sensitivity.

* Please cite this article as: Etxebarria Beitia E, Díez del Val I, Loureiro González C, González Serrano C, Bilbao Axpe JE. Duodenoyeyunostomía laparoscópica como tratamiento del síndrome de la arteria mesentérica superior. *Cir Esp.* 2014;92:129-131.

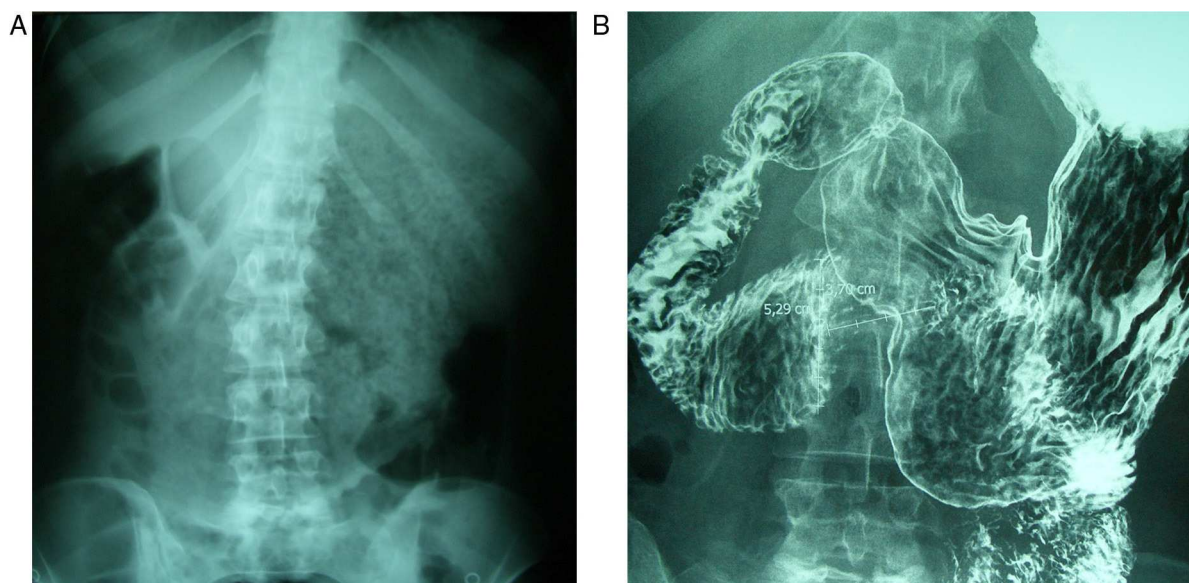


Fig. 1 – (A) Simple abdominal radiograph showing the stomach with important food retention; (B) upper GI study demonstrating the difficult emptying in the third part of the duodenum.

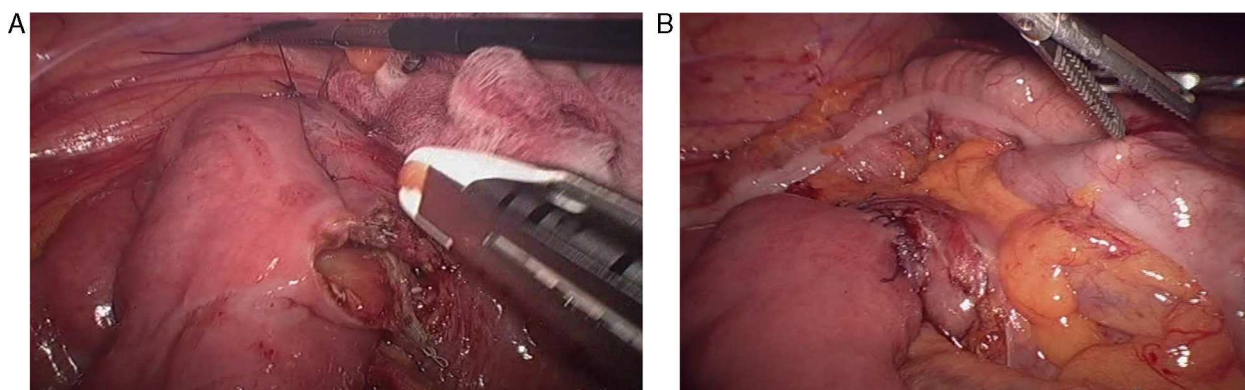


Fig. 2 – (A and B) Intraoperative images of the laparoscopic duodenojejunostomy.

Classic upper GI study findings are dilatation of the first and second parts of the duodenum, antiperistaltic flow of the barium proximal to the obstruction, delayed gastrointestinal transit and relief of the obstruction with patient position changes.⁴

In angiographic studies, patients with SMA syndrome present an aortomesenteric angle of 7–22° (normal: 28–65°) and the distance between the aorta and the SMA is 2–8 mm (normal: 10–34 mm).

The treatment of SMA syndrome is generally conservative and is initially aimed at the correction of hydroelectrolytic and metabolic alterations, decompression of the gastrointestinal tract (including the use of posture maneuvers) or the placement of a nasogastric tube and recovery of the nutritional state. The use of prokinetics may be effective.^{2,4,5} As in the case of our patient, those with acute SMA syndrome almost always respond to conservative treatment; chronic symptoms, however, usually require surgical intervention after a period of refeeding.³

Surgical treatment is indicated when either medical treatment fails or the duodenal dilatation is persistent and progressive.²

The surgical techniques used are Strong's procedure, vascular re-implantation and gastrointestinal bypass.⁶ Strong's operation involves dissecting the ligament of Treitz and extensive mobilization of the duodenum in order to displace it from the aortomesenteric angle.

Transposition of the SMA at the infrarenal aorta is a standardized technique for the treatment of chronic ischemia that can be effective in SMA syndrome by thus avoiding disruption of the intestine.^{6,7}

In patients with important gastric distension, gastrojejunostomy is a valid option, but it may cause bile reflux and anastomotic ulcer. Roux-en-Y and side-to-side duodenojejunostomy are the most frequently used surgical procedures, with a success rate of 90%. Nonetheless, they present a risk of intestinal stenosis and fistula.⁶ The laparoscopic approach, as described by Gersin and Heniford in 1998, provides definitive

treatment by means of a minimally invasive technique, with its intrinsic advantages.⁷⁻⁹ Therefore, from our standpoint and in light of the case presented, it should currently be considered the treatment of choice.

REFERENCES

- Gustafsson L, Falk A, Lukes PJ, Gamklou R. Diagnosis and treatment of superior mesenteric artery syndrome. *Br J Surg*. 1984;71:499-501.
- Jo JB, Song KY, Park CH. Laparoscopic duodenojejunostomy for superior mesenteric artery syndrome: Report of a case. *Surg Laparosc Endosc Percutan Tech*. 2008;18:213-5.
- Fernández MT, López MJ, Bardasco ML, Álvarez P, Rivero MT, García G. Síndrome de Wilkie: a propósito de un caso. *Nutr Hosp*. 2011;26:646-9.
- Agrawal GA, Johnson PT, Fishman EK. Multidetector row CT of superior mesenteric artery syndrome. *J Clin Gastroenterol*. 2007;41:62-5.
- Makam R, Chamany T, Potluri VK, Varadaraju PJ, Murthy R. Laparoscopic management of superior mesenteric artery syndrome: a case report and review of literature. *J Minim Access Surg*. 2008;4:80-2.
- Pourhassan S, Grottemeyer D, Fürst G, Rudolph J, Sandmann W. Infrarenal transposition of the superior mesenteric artery: a new approach in the surgical therapy for Wilkie syndrome. *J Vasc Surg*. 2008;47:201-4.
- Sánchez Abuín J, Fernández Fernández JC, Rodríguez Sáenz de Buruaga V, Egaña Barrenechea JM. Tratamiento de la compresión vascular del duodeno mediante reimplante de la arteria mesentérica superior. *Cir Esp*. 2010;87:124-5.
- Gersin KS, Heniford BT. Laparoscopic duodenojejunostomy for treatment of superior mesenteric artery syndrome. *JSL*. 1998;2:281-4.
- Richardson WS, Surowiec WJ. Laparoscopic repair of superior mesenteric artery syndrome. *Am J Surg*. 2001;181:377-8.

Eider Etxebarria Beitia*, Ismael Díez del Val, Carlos Loureiro González, Carmen González Serrano, José Esteban Bilbao Axpe

Hospital Universitario Basurto, Bilbao, Spain

*Corresponding author.

E-mail addresses: eider.etxebarriabeitia@osakidetza.net, Heineck_5@hotmail.com (E. Etxebarria Beitia).

2173-5077/\$ – see front matter

© 2013 AEC. Published by Elsevier España, S.L. All rights reserved.

Obstructive Jaundice Caused by a Mucinous Adenocarcinoma of the Appendix in a Patient With Intestinal Malrotation



Ictericia obstructiva por adenocarcinoma mucinoso de apéndice en paciente con malrotación intestinal

Appendiceal mucocele is a rare disease with an incidence that ranges between 0.2% and 0.4% of all appendectomies.¹⁻⁴ It is generally asymptomatic and is an incidental finding. When it causes symptoms, the most common are abdominal pain or a palpable mass in the RLQ.

We report the case of a 62-year-old male patient with a history of arterial hypertension and hyperuricemia. He reported symptoms that had been developing over the past 4 months characterized by postprandial fullness and epigastric pain. These symptoms had also been associated with weight loss, jaundiced skin and mucous membranes the week prior to being treated in the Gastroenterology Department.

Laboratory tests showed: bilirubinemia 6.6 mg/dl, direct bilirubin 5.03 mg/dl, and other parameters (including CA 19-9

and CEA) were within normal range. A CT of the chest and abdomen revealed a lesion in the second portion of the duodenum that measured 4.9 × 4.1 cm and was compatible with a neoplastic process. This produced dilatation of the intra- and extrahepatic biliary tract with moderate gastric distension; there was no evidence of liver or lung metastases.

Upper gastrointestinal endoscopy revealed a malignant-looking stenotic lesion in the second portion of the duodenum, suggestive of extrinsic origin. Biopsies showed no evidence of malignant disease.

The patient was transferred to our General Surgery Department for scheduled surgery. During the procedure, we observed a retroperitoneal tumor infiltrating the duode-

* Please cite this article as: Álvarez Seoane R, García Novoa A, Gómez Gutierrez M. Ictericia obstructiva por adenocarcinoma mucinoso de apéndice en paciente con malrotación intestinal. *Cir Esp*. 2014;92:131-133.