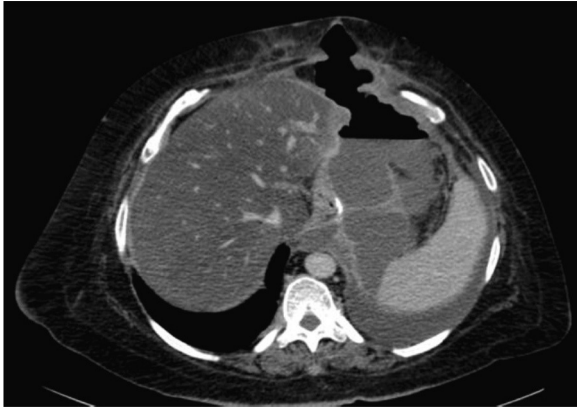

**Fig. 2 – Abdominal CT with a large perigastric collection and left pleural effusion secondary to the gastric fistula.**

should be the use of flexible covered stents<sup>5,9,10</sup> in an attempt at creating a “temporary bypass” of the fistula. Other proposed treatments include the endoscopic use of adhesives (surgical glues),<sup>5,7</sup> which has provided controversial results. In cases that do not respond to any treatment, the possibility of treating the distal stenosis (if there is any) with endoscopic dilatations should be assessed. If there is no other option left except for surgery, simple fistula closure should be avoided and gastric intraluminal pressure should be reduced by converting the technique to gastric bypass.

#### REFERENCES

1. Serra C, Pérez N, Bou R, Bengochea M, Martínez R, Baltasar A. Gastrectomía tubular laparoscópica. Una operación bariátrica con diferentes indicaciones. *Cir Esp.* 2006;75:289–92.
2. Marceau P, Cabanac M, Frankham PC, Hould FS, Lebel S, Marceau S, et al. Accelerated satiation after duodenal switch. *Surg Obes Relat Dis.* 2005;1:408–12.

3. Aggarwal S, Kini SU, Herron DM. Laparoscopic sleeve gastrectomy for morbid obesity: a review. *Surg Obes Relat Dis.* 2007;3:189–94.
4. Burgos AM, Braghetto I, Csendes A, Maluenda F, Korn O, Yarmuch J, et al. Gastric leak after laparoscopic-sleeve gastrectomy for obesity. *Obes Surg.* 2009;19:1672–7.
5. Casella G, Soricelli E, Rizello M, Trentino Fiocca F, Fantini A, et al. Nonsurgical treatment of staple line leaks after laparoscopic sleeve gastrectomy. *Obes Surg.* 2009;19:821–6.
6. Gonzalez R, Nelson L, Gallagher S, Murr M. Anastomotic leaks after laparoscopic gastric bypass. *Obes Surg.* 2004;14:1299–307.
7. Ferrer Márquez M, Ferrer Ayza M, Belda Lozano R, Rico Morales MM, García Díez JM, Belda Poujoulet R. Gastric leak after laparoscopic sleeve gastrectomy. *Obes Surg.* 2010;20:1306–11.
8. De Aretxabala X, Leon J, Wiedmaier G, Turu I, Ovalle C, Maluenda F. Gastric leak after sleeve gastrectomy: analysis of its management. *Obes Surg.* 2011;21:1232–7.
9. Serra C, Baltasar A, Andreo L, Pérez N, Bou R, Bengochea M, et al. Treatment of gastric leaks with coated self-expanding stents after sleeve gastrectomy. *Obes Surg.* 2007;17:866–72.
10. Eubanks S, Edwards CA, Fearing NM, Ramaswamy A, de la Torre RA, Thaler KJ, et al. Use of endoscopic stents to treat anastomotic complications after bariatric surgery. *J Am Coll Surg.* 2008;206:935–8.

Manuel Ferrer Márquez\*, Ricardo Belda Lozano, María José Solvas Salmerón, Manuel Ferrer Ayza

Hospital Torrecárdenas, Almería, Spain

\*Corresponding author.

E-mail address: [Manuferrer78@hotmail.com](mailto:Manuferrer78@hotmail.com)

(M. Ferrer Márquez).

14 October 2012; accepted 23 December 2012

2173-5077/\$ – see front matter

© 2012 AEC. Published by Elsevier España, S.L. All rights reserved.

## Catamenial Pneumothorax: A Heterogeneous Syndrome<sup>☆</sup>

### Neumotórax catamenial: un síndrome heterogéneo

#### Introduction

Catamenial pneumothorax (CP) is pneumothorax that occurs 3 days before or after menstruation.<sup>1</sup> It is the most frequent manifestation of intrathoracic endometriosis, as described by Maurer in 1958.<sup>2</sup> There are several theories about its

etiopathogenesis and treatments, which have provided varying results. We present four cases of CP.

Patient 1 is 31 years old and presented with chest pain, dyspnea and a right hemothorax. She had a history of previous episodes of pneumothorax: episode 1 was treated with drainage; episode 2 was treated with the resection of apical bullae and abrasive pleurodesis by video-assisted thoracos-

<sup>☆</sup> Please cite this article as: Mier Odiozola JM, Fibla Alfara Molins L JJ, Molins López-Rodó L. Neumotórax catamenial: un síndrome heterogéneo. *Cir Esp.* 2014;92:366–368.

copy (VATS); and in the third episode a chest drain was used. The presentation always coincided with menstruation and the patient also reported fertility problems. Surgery was proposed, and an axillary thoracotomy was performed with decortication of the upper parietal pleura and abrasion pleurodesis. After surgery, the patient received hormone therapy. During a 5-year follow-up, she has had no recurrence of the pneumothorax and has carried a pregnancy to full term.

Patient 2 is 35 years old with a history of 3 episodes of right pneumothorax. She experienced menstrual pain and dyspnea as well as infertility due to endometriosis. VATS surgery included resection of right apical bullas and abrasion pleurodesis. One month later, she presented right recurrence. Axillary thoracotomy and parietal pleural decortication were performed, demonstrating pleural endometrial tissue. After surgery and hormone treatment, the patient did not present another pneumothorax and was able to carry a pregnancy to term. Three years after surgery, she presented partial left pneumothorax treated with chest drainage and suction. Five months later, she has presented no recurrences.

Patient 3 is a 40-year-old woman who was hospitalized with right pneumothorax that had been demonstrated radiologically on 2 occasions, along with dysmenorrhea, dyspnea and occasional chest pain during the menstrual period. Right apical bullae were resected with partial parietal decortication by VATS, which demonstrated pleural endometriosis. One month later, she presented basal lamina pneumothorax, which was treated without drainage and has presented no recurrence in 6 months.

Patient 4 is 35 years old and has had 4 menstrual episodes of right pneumothorax, two of which were treated with drainage. Right apical bullae were resected, followed by VATS abrasion pleurodesis and chemical pleurodesis with talc. Intraoperatively, 3 orifices were observed in the diaphragm, which were no larger than 10 mm (Fig. 1). Four months later, she has had no recurrence.

Approximately 61% of the patients with CP present signs of pelvic endometriosis.<sup>3</sup> The average age is 32–37.<sup>3</sup> The prevalence of CP is from 1 to 5% in women who present menstrual pneumothorax.<sup>4</sup> The usual presentation is pain and dyspnea, most frequently on the right side.

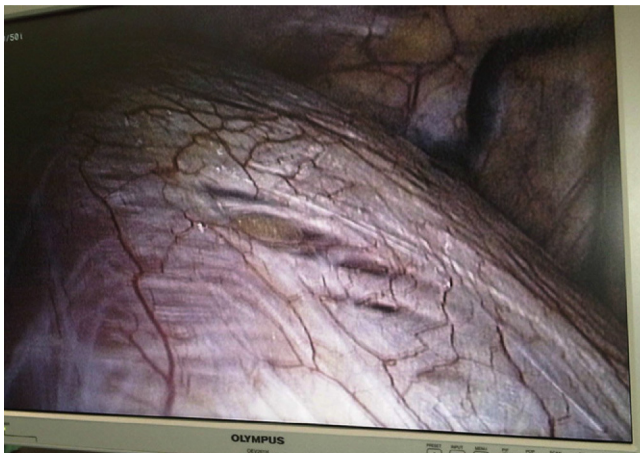


Fig. 1 – Orifices in the diaphragm.

There are several theories about the pathophysiology of CP. Congenital diaphragm orifices are most frequent on the right side, so the thought is that endometrial tissue could migrate through the peritoneum from the uterus and enter into the thorax through these orifices. There are many publications that demonstrate this,<sup>5</sup> and in our review of cases, case 4 had such orifices.

The hormonal theory by Rossi<sup>6</sup> proposes that high levels of prostaglandin F<sub>2</sub> produced during ovulation could cause vasospasms that trigger a pulmonary ischemic process that would lead to alveolar rupture, and therefore CP. This would explain why in some patients no diaphragm orifices or visible endometrial implants were able to be identified despite having been surgically evaluated. In contrast with this theory is the fact that prostaglandin inhibitors have failed as an effective treatment for CP.<sup>7</sup> What supports this theory is that some patients improve when treated with drugs that inhibit ovulation and therefore reduce circulating prostaglandin levels.<sup>8</sup>

Another theory has to do with the anatomical changes of the cervix caused by menstruation. During the menstrual period, the cervix opens to allow the endometrial tissue to flow out, which pulls away and diminishes the mucus layer that protects against the entry of external agents, including the outer air, which could use this pathway into the uterus and pass through the Fallopian tubes to the abdomen and through the diaphragm orifices to the thorax. This would explain why some patients with CP present pneumoperitoneum.<sup>9</sup> Treatments such as tubal ligation have been proposed to impede the retrograde passage of air and tissue.<sup>10</sup> Evidence against this is that there have been some cases of CP after hysterectomy.<sup>11</sup>

As the theories of the etiology are varied, so are the therapeutic options<sup>12</sup>:

- (a) If there are visible bullae, these should be resected.
- (b) If there is tissue suspicious of being ectopic endometrium, this should be resected together with decortication of the parietal pleura as extensively as possible in order to eliminate microscopic implants.
- (c) If diaphragmatic fenestrations are observed, these should be repaired or sealed.

Other surgical alternatives, such as tubal ligation, hysterectomy, oophorectomy or mesh placement in the orifices of the diaphragm,<sup>13</sup> should be used with caution. Hormone therapy after surgery is not only effective in the prevention of CP recurrence, but also in other patient problems, such as infertility. In our series, two cases were infertile and, after surgery and hormone replacement therapy, they were able to carry pregnancies to term.

In summary, CP is a syndrome with uncertain etiology that requires detailed patient information as well as radiological studies of the pneumothorax. Surgical treatment is always necessary and the type of intervention depends on the intraoperative findings.

#### REFERENCES

1. Peikert T, Gillespie DJ, Cassivi SD. Catamenial pneumothorax. *Mayo Clin Proc.* 2005;80:677–80.

2. Maurer ER, Schaal JA, Mendez Jr FL. Chronic recurring spontaneous pneumothorax due to endometriosis of the diaphragm. *JAMA*. 1958;168:2013-4.
3. Joseph J, Sahn SA. Thoracic endometriosis syndrome: new observation from an analysis of 110 cases. *Am J Med*. 1996;100:164-70.
4. Nakamura H, Konishike J, Sugamura A, Takeno Y. Epidemiology of spontaneous pneumothorax in women. *Chest*. 1986;89:378-82.
5. Sánchez-Lorente D, Gómez-Caro A, García Reina S, María Gimferrer J. Treatment of catamenial pneumothorax with diaphragmatic defects. *Arch Bronconeumol*. 2009;45:414-5.
6. Rossi NP, Goplerud CP. Recurrent catamenial pneumothorax. *Arch Surg*. 1974;109:173-6.
7. Dattola RK, Toffe RC, Lewis MJ. Catamenial pneumothorax: a case report. *J Reprod Med*. 1990;35:734-6.
8. Korom S, Canyurt H, Missbach A, Schneider D, Kurrer MO, Haller U, et al. Catamenial pneumothorax revisited: clinical approach and systematic review of the literature. *J Thorac Cardiovasc Surg*. 2004;128:502-8.
9. Roth T, Alifano M, Schussler O, Magdaleinat P, Regnard JF. Catamenial pneumothorax: chest X-ray sing and thoracoscopic treatment. *Ann Thorac Surg*. 2002;74:563-5.
10. Härkki P, Jokinen JJ, Salo JA, Sihvo E. Menstruation-related spontaneous pneumothorax and diaphragmatic endometriosis. *Acta Obstet Gynecol Scand*. 2010;89:1192-6.
11. Lee CY, Di Loreto PC, Beaundoin J. Catamenial pneumothorax. *Obstet Gynecol*. 1974;44:407-11.
12. Alifano M. Catamenial pneumothorax. *Curr Opin Pulm Med*. 2010;16:381-6.
13. Majzlin G, Stevens FL. Meigs' syndrome: case report and review of literature. *J Int Coll Surg*. 1964;42:625-30.

José Manuel Mier Odiozola\*, Juan José Fibla Alfara Molins L, Laureano Molins López-Rodó

Servicio de Cirugía Torácica, Hospital Universitari Sagrat Cor, Barcelona, Spain

\*Corresponding author.

E-mail address: [jmmo50@hotmail.com](mailto:jmmo50@hotmail.com) (J.M. Mier Odiozola).

2173-5077/\$ – see front matter

© 2012 AEC. Published by Elsevier España, S.L. All rights reserved.

## Pneumoperitoneum Secondary to Barotrauma Following a Diving Accident

## Neumoperitoneo secundario a barotrauma tras accidente de buceo

We present the case of a 35-year-old male patient who came to our consultation with abdominal distension that had been developing over the previous 10 h, with no other symptoms. The distension had begun immediately after free-diving to a depth of 39 m. His personal history included left inguinal hernioplasty. On physical examination, the patient was in good general condition: no fever, hemodynamically stable and eupneic. The abdomen was soft, with great distension and generalized hyperresonance as well as crepitus upon palpation of the umbilical region, which presented a non-complicated umbilical hernia. The patient had no pain during abdominal palpation or any signs of peritoneal irritation. Air-fluid levels were detected. The remaining physical exploration was unremarkable.

Blood analysis showed 14,490 leukocytes (normal formula), GOT 53 U/l, GPT 74 U/l, CPK 208 U/l, CKMB 40 U/l and myoglobin 46.49 ng/ml. The remaining determinations, including coagulation and venous blood gases, had values within normal ranges.

When we observed the shape of the transverse colon wall on standing chest and abdominal radiographs (Figs. 1 and 2), a

normal intraluminal hydro-air pattern was seen with extraluminal free air accumulated in the subdiaphragm region as well as displacement of the lung bases and viscera of the upper abdomen. In addition to the voluminous pneumoperitoneum pushing the abdominal content in the posterior direction and umbilical hernia with fat and gas content, thoracoabdominal CT also revealed pulmonary laminar atelectasis due to compression and minimal pericardial effusion. No intraperitoneal free fluid, intravascular gas or disruption of hollow organs was observed. Electrocardiogram was normal.

Given the good general status of the patient, the lack of significance found in the analyses and the lack of evidence of perforation, we opted for conservative management with no oral intake, parenteral nutrition, normobaric high-flow oxygen therapy (MV at 35%-8 lpm) and low-molecular-weight heparin at a prophylactic dosage. Oral tolerance was started 48 h later, and enteral nutrition was reinstated without complications after 72 h. During hospitalization, the patient passed gas and had normal bowel movements with no pathologic production. He presented isolated fever (38.1 °C) on the third day after hospitalization, which responded to the

\* Please cite this article as: Rosado Dawid NZ, Peraza Casajús JM, Bodega Quiroga I. Neumoperitoneo secundario a barotrauma tras accidente de buceo. *Cir Esp*. 2014;92:368-370.