

Image of the month

Infected Gluteal Hydatid Cyst^{☆,☆☆}

Quiste hidatídico glúteo sobreinfectado

Isabel Belda González,^{a,*} Daniel Soliva Martínez,^a Sagrario Relanzon Molinero,^a
María José Cantero Ayllon^b

^a Servicio de Radiodiagnóstico, Hospital Virgen de la Luz, Cuenca, Spain

^b Servicio de Cirugía General y del Aparato Digestivo, Hospital Virgen de la Luz, Cuenca, Spain

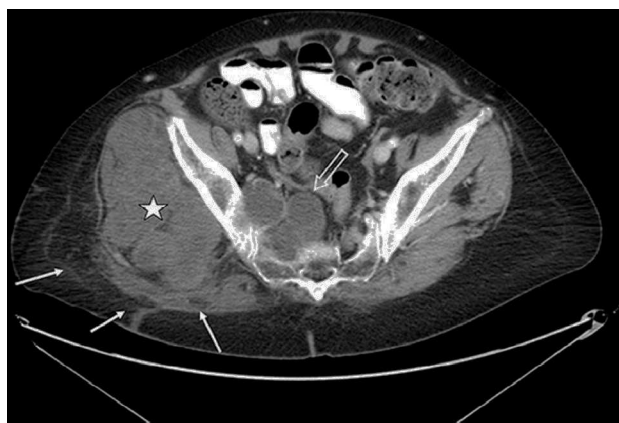

Fig. 1

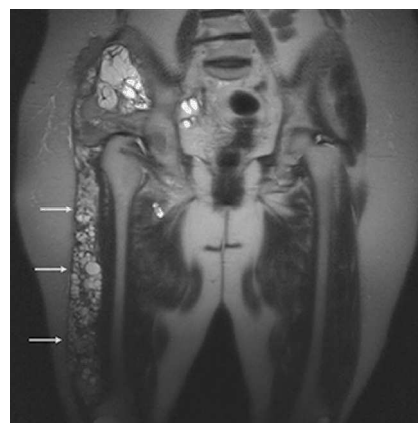


Fig. 2

A 77-year-old woman, who had had a previous gluteal hydatid cyst that had been treated surgically years before, came to our Emergency Department due to suppuration through the scar, where daughter vesicles and purulent material were observed. Complementary tests were performed, and both CT and MRI demonstrated multivesicular hydatid cysts in the right gluteal muscle (Fig. 1), that affected the adjacent muscles and extended to the pelvis (Fig. 2), with alteration of the adjacent fat, possibly due to infection. With the diagnosis of infected extensive musculoskeletal hydatidosis, the patient was treated with debridement and resection of the accessible lesions, with a subsequent favorable evolution.

[☆] The content of this paper has been partially published as a poster presentation at the European Congress of Radiology held in Viena on March 7 - 11, 2013, under the title "Imaging findings in complicated hydatid disease". The figures are original.

^{☆☆} Please cite this article as: Belda González I, Soliva Martínez D, Relanzon Molinero S, Cantero Ayllon MJ. Quiste hidatídico glúteo sobreinfectado. Cir Esp. 2014;92:e37.

* Corresponding author.

E-mail address: isa_belda@yahoo.es, tenguardia@hotmail.com (I. Belda González).