

Original article

Prospective, Randomized Comparative Study Between Single-port Laparoscopic Appendectomy and Conventional Laparoscopic Appendectomy^{☆,☆☆}



Rafael Villalobos Mori,^{*} Jordi Escoll Rufino, Fernando Herrerías González, M. Carmen Mias Carballal, Alfredo Escartin Arias, Jorge Juan Olsina Kissler

Servicio de Cirugía, Hospital Universitari Arnau de Vilanova, Lérida, Spain

ARTICLE INFO

Article history:

Received 31 May 2013

Accepted 6 December 2013

Available online 12 July 2014

Keywords:

Laparoscopic appendectomy

Single port surgery

Acute appendicitis

Laparoscopy

Minimally invasive surgery

A B S T R A C T

Introduction: Laparoscopic appendectomy is probably the technique of choice in acute appendicitis. Single port laparoscopic surgery (SILS) has been proposed as an alternative technique. The objective of this study is to compare the safety and efficacy of SILS against conventional laparoscopic appendectomy (LA).

Material and methods: From January 2011 to September 2012, 120 patients with acute appendicitis were prospectively randomized; 60 for SILS and 60 for LA. Patients between 15 and 65 years were selected, with onset of symptoms less than 48 h. We compared BMI, surgery time, start of oral intake, hospital stay, postoperative pain, pathology, and costs.

Results: The median age, BMI, sex, and time of onset of symptoms to diagnosis were similar. There were no statistically significant differences in the operative time, start of oral intake, or hospital stay. There was a significant difference in postoperative pain being higher in SILS (4 ± 1.3) than in LA (3.3 ± 0.5) with a $P=.004$. Flemonous appendicitis predominated in both groups in a similar percentage. A total of 3 cases with intra-abdominal abscess (SILS 2, LA 1) required readmission and resolved spontaneously with intravenous antibiotic treatment. One case of SILS required assistance by a 5 mm trocar in the RLC for drainage placement. The cost was higher in SILS due the single port device.

Conclusion: SILS appendectomy is safe, effective, and has similar results to LA in selected patients, and although the cost is greater, the long term results will determine the future of this technique.

© 2013 AEC. Published by Elsevier España, S.L.U. All rights reserved.

^{*} Please cite this article as: Villalobos Mori R, Escoll Rufino J, Herrerías González F, Mias Carballal MC, Escartin Arias A, Olsina Kissler JJ. Estudio comparativo prospectivo aleatorizado entre apendicectomía laparoscópica por puerto único y apendicectomía laparoscópica convencional. Cir Esp. 2014;472-477.

^{☆☆} Part of this manuscript was presented at the 6th International Notes Wider (Barcelona, December 3-4, 2012): Natural orifice transluminal endoscopic surgery.

^{*} Corresponding author.

E-mail address: rafovilla26@gmail.com (R. Villalobos Mori).

2173-5077/\$ – see front matter © 2013 AEC. Published by Elsevier España, S.L.U. All rights reserved.

Estudio comparativo prospectivo aleatorizado entre apendicectomía laparoscópica por puerto único y apendicectomía laparoscópica convencional

RESUMEN

Palabras clave:

Apendicectomía laparoscópica
Cirugía por puerto único
Apendicitis aguda
Laparoscopia
Cirugía mínimamente invasiva

Introducción: La apendicectomía laparoscópica es probablemente en la actualidad la técnica de elección en las apendicitis agudas. La cirugía laparoscópica por puerto único (PU) ha intentado instalarse como técnica alternativa. El objetivo de este estudio es comparar la seguridad y eficacia del PU frente a la apendicectomía laparoscópica convencional (LC). **Material y métodos:** De enero del 2011 a septiembre del 2012 se aleatorizó prospectivamente a 120 pacientes con apendicitis aguda (PU 60, LC 60). Se seleccionó a pacientes entre 15 y 65 años con inicio de síntomas < 48 h comparándose el IMC, tiempo operatorio, inicio de ingesta, estancia hospitalaria, dolor postoperatorio, anatomía patológica y costes.

Resultados: La edad media, IMC, sexo y tiempo de inicio de síntomas hasta el diagnóstico fueron similares. No se encontraron diferencias del tiempo operatorio, inicio de ingesta ni estancia hospitalaria. Se evidenciaron diferencias en el dolor postoperatorio siendo mayor en el PU ($4 \pm 1,3$) que en la LC ($3,3 \pm 0,5$) con una $p = 0,004$. La apendicitis flemonosa predominó para ambos grupos. Hubo 3 reingresos por absceso intraabdominal (PU 2, LC 1) que requirieron tratamiento antibiótico intravenoso. Un caso del PU requirió asistencia intraoperatoria de un trocar de 5 mm en FID por necesidad de drenaje. El coste fue mayor en el PU debido al dispositivo empleado.

Conclusión: La apendicectomía por PU es segura, eficaz con resultados similares a la LC en pacientes seleccionados y, aunque el coste es mayor, serán los resultados obtenidos a largo plazo los que determinen el futuro de esta técnica.

© 2013 AEC. Publicado por Elsevier España, S.L.U. Todos los derechos reservados.

Introduction

Laparoscopic appendectomy is probably the current technique of choice for acute complicated or uncomplicated appendicitis. Since Semm performed the first laparoscopic appendectomy in 1983, a large variety of papers have been published, noting the advantages of this technique compared to open appendectomy.¹⁻³ However, in an effort to “minimize” the incision in the abdominal wall, laparoscopic surgery through a single port is now being used, commonly known as SILS (*Single-Incision Laparoscopic Surgery*). This relatively new concept started over 15 years ago in pediatric surgery,⁴⁻⁸ evolving to the present day with the development of devices and medical graspers that have helped the surgeon to extend its application to other diseases.⁹ SILS-based appendectomy tries to position itself as an alternative technique compared to conventional laparoscopy (CL), with emphasis on the publication of studies with better cosmetic results,^{10,11} considering that it is usually performed through the umbilicus and the scar is almost invisible.

This is a prospective randomized study comparing CL-based appendectomies to SILS-based appendectomies. Parameters are analyzed such as surgery time, start of oral intake, hospital stay, post-surgery pain, post-surgery complications, pathology, and costs.

Materials and methods

In January 2011, a prospective randomized study was initiated, aiming to compare SILS to CL. The study included 60 patients

for each technique, with the following inclusion criteria: patients aged between 15 and 65 years, with BMI < 30, onset of symptoms less than 48 h, absence of previous abdominal surgery, ASA anesthesia risk I, presence of a surgeon trained in both techniques and signed informed consent (Table 1). The age range of patients was based on that of the economically active population, given that it is a well-defined population sector and relevant to the statistical study. Another factor for inclusion was non-obese patients, i.e. with a BMI < 30, because a higher value would increase the possibility of complications.^{12,13} Appendicitis cases with a time of onset of symptoms of less than 48 h were selected, predictably uncomplicated (no perforation, no diffuse or localized peritonitis). Pain was assessed with a visual analog scale (VAS) on discharge. Another important factor to note was the motivation of the surgeon to perform this type of technique; therefore, 3 surgeons were considered who were interested in learning and developing it. These surgeons had no previous experience with SILS-based appendectomies, but did with CL, which made it easier on their learning curve.¹⁴ All the patients included were informed and accepted the randomized study;

Table 1 – Inclusion Criteria.

Age between 15–65 years
BMI < 30
Onset of symptoms < 48 h
ASA I
Surgeons trained in SILS
No previous abdominal surgery
Signed informed consent

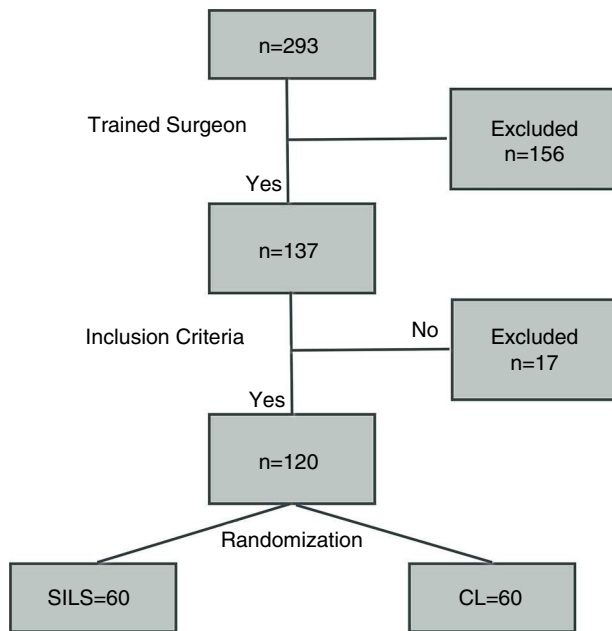


Fig. 1 – Randomization algorithm.

none of them had previous abdominal surgery. Informed consent was signed by all patients who accepted both techniques.

A performance algorithm was developed as shown in Fig. 1. Randomization was performed by closed envelope in a box where 60 envelopes were placed for each technique.

The CL material used was a Hasson trocar, one of 11 mm, and another one of 5 mm. 30° 10 mm optics, graspers (2), scissors, hook, endoloops (2), endoclip. For SILS, the single port device (Covidien SILS port) was used[®], 5 mm and 30° optics, articulated grasper (Covidien Roticulator Endo Grasp[®]), scissors, endoloops (2), endoclip and in some cases, for the two techniques, Covidien Ligasure[®] and endostapler (Covidien Endo-GIA[®]).

Conventional laparoscopic appendectomy was performed with a 1 cm approximately periumbilical incision to place the

Hasson and where the optics were inserted, another 5 mm incision in FII and 11 mm approx. in the suprapubic region. All appendices were bagged and removed through the umbilical incision under direct vision with 11 mm trocar-inserted optics. The aponeuroses of the umbilical and suprapubic incisions were closed with 0 long-duration absorbable suture (Ethicon PDS[®]) and staples for skin.

SILS-based appendectomy was performed via an approximately 2.5–3 cm transumbilical incision where the SILS port was inserted[®]. This device has 4 orifices, one for inserting the gas, another for optics, and the other 2 for surgeon's manipulations. It is important to place the optics in the orifice closest to the surgeon, allowing better vision and to avoid interfering with the assistant (Fig. 2). In 39 cases (No.=60), there was no need to use the articulated grasper. To bag the appendix, a collection bag was used, after the placing the 12 mm trocar in the orifice most distal to the surgeon. The aponeurosis was closed with 0 long-duration absorbable suture (Ethicon PDS[®]), with interrupted sutures, followed by one 3-0 fast-absorbing intradermal suture (Ethicon Vicryl Rapid[®]).

Neither of the techniques used anesthetic infiltration to avoid errors in measuring post-surgery pain. Surgeries were performed with the patient in slight Trendelenburg, inclined to the left, which facilitated the procedure. For our hospital protocol (for easier Douglas viewing, and to avoid bladder injury) only patients undergoing CL-based appendectomy received a urinary catheter, which was removed at the end of the surgery.

The results were entered into a database and analyzed using the SPSS application[®]. For quantitative variables, the Student t test was used, and the chi square test for non-quantitative variables. $P < .05$ was accepted as the level of statistical significance.

Results

Between January 2011 and September 2012, surgery was conducted on 293 acute appendicitis patients overall, of which

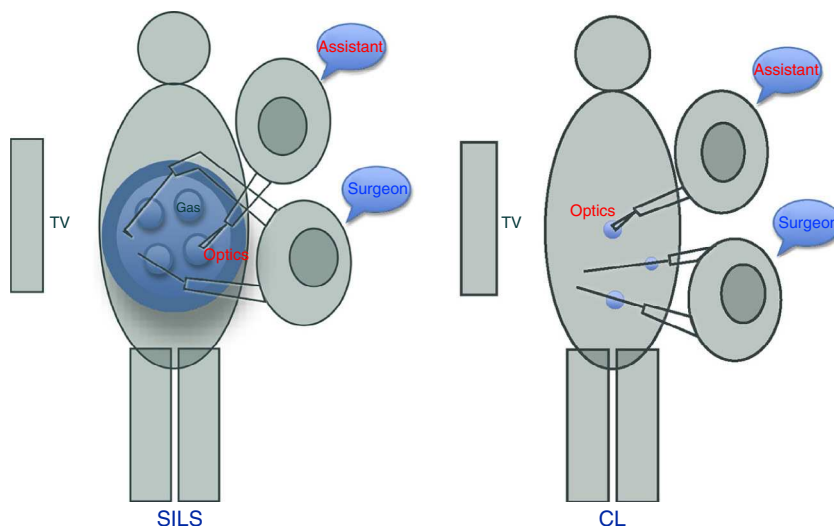


Fig. 2 – Laparoscopic techniques.

Table 2 – Variables According to Surgery Technique.

Variables	SILS (60)	CL (60)	P
Age (years)	28.1±9.3	30±9.2	>.3
BMI	24.6±3.0	24.4±2.1	
Onset of symptoms (h)	12.5±2.7	14.1±3.4	
Gender (M/F)	42/18	34/26	.49
Surgery time (min)	49.1±12	45.5±13	.21
Diet start (h)	13±11	12±11	.77
Hosp. stay (days)	1.9±1.2	2.5±1.9	.05
Pain (VAS)	3.9±1.3	3.3±0.5	.004

120 met the study inclusion criteria (Table 2). No significant differences were observed for all these parameters between the two groups. In addition, surgery time was similar for the two groups, as well as the start of fluid intake and hospital stay. Post-surgery pain was measured using the VAS scale (0–10), with higher readings for SILS with a statistically significant difference ($P=.004$; SILS 4 ± 1.3 ; CL 3.3 ± 0.5). The pathological study revealed the following groups: unaltered appendix, acute catarrhal, phlegmonous or suppurative, and gangrenous appendicitis. The findings were similar for each group, predominantly for phlegmonous appendicitis; SILS (73%) and CL (77%) did not show significant differences ($P=.21$).

There were 13 post-surgery complications with SILS (22%), and 12 with CL (20%), with a $P=.78$. Notably, for SILS, there were 2 intra-abdominal abscess cases requiring hospitalization for IV antibiotics, and only one case for CL. In the two groups, the collections were located in the right iliac fossa, without the need for additional surgery or puncture-drainage, due to good response to antibiotic treatment. Intraoperative lavage data were collected as well (SILS 16 and CL 19; $P=.49$), anticipating that its excess could be a condition for having an intra-abdominal abscess.¹⁵ Other complications such as post-surgery ileus or surgical wound infection, among others, showed no significant differences (Table 3).

The cost, depending on the type of technique used, was adjusted to the prices provided by the purchasing department of our hospital (Table 4), listing specified additional material used in some cases, depending on intra-operational circumstances.

Post-surgery follow-up was performed between 6 and 24 months; there were 2 hernia cases for SILS, and none for CL. Only one case was correlated to surgical wound infection.

Discussion

SILS-based laparoscopic appendectomy arises in a context in which CL-based appendectomy was becoming the technique

Table 3 – Post-surgery Complications.

Complications	SILS (13/60) (%)	CL (10/60) (%)
Surgical wound infection	2 (3.3)	2 (3.3)
Intra-abdominal abscess	2 (3.3)	1 (1.6)
Post-surgery ileus	2 (3.3)	3 (5)
Hernia	2 (3.3)	–
Other	5 (8.4)	4 (6.7)
Total	13 (21.6)	10 (16.6)

Table 4 – Costs According to Technique.

Material	SILS (€)	CL (€)
Single incision system	305.83	
Hasson		60.78
Trocar 11 mm		46.43
Trocar 5 mm		58.54
Suture (PDS and polyglactin)	12.72×2	12.72×2
Endoclip	187.36	187.36
Endoloop	13.17×2	13.17×2
Collection bag	15.74	15.74
Endograsp Roticulator [®]	220 (21 cases)	
Ligasure ^{®a}	702 (10 cases)	702 (8 cases)
Endo-GIA ^{®a}	399.61 (1 case)	399.61 (2 cases)
Price per surgery without ER	560.71	420.63
Price per surgery with ER	780.71	

ER: endograsp roticator.

^a Not included in final cost, since they were used in special cases.

of choice compared to open appendectomy. Despite the latter being the gold standard for appendicitis treatment in recent years, new randomized prospective papers have been published in addition to practice guidelines clearly showing benefits from laparoscopic surgery,^{16–18} progressively leading to the change of option by most surgeons. Technological development, the urge to be less aggressive in the incisions and to improve esthetic results, along with the inherent concern of most surgeons, have boosted the development of SILS-based appendectomy. This technique may have some benefits over CL due to the smaller incision, resulting in an almost imperceptible scar for the patient. SILS as a novel technique has been the focus of all kinds of criticism, especially due to how complicated and expensive it is; this situation is similar to that which occurred with laparoscopic surgery when it emerged in the late 1980s.¹⁹ However, the latter is currently the gold standard technique in multiple surgeries. Our study included only patients without factors altering the implementation of the technique, such as obesity, complicated acute appendicitis or patients with previous abdominal surgery. From the results obtained, the patient population was found to be homogeneous for both groups.

Although the SILS-based appendectomy surgery time turned out to be greater than that for CL, no statistically significant differences were detected ($P=.21$), showing that this minimal difference was due to the increased time spent placing the single port, and during closure of the incision. Furthermore, the added difficulty of triangulation in the SILS technique that could prolong surgery was not as significant as almost 2/3 of the patients who underwent the SILS-based surgery (39) with straight forceps. This is due to the topographic characteristics of the appendix and its mesentery, which often have a plane perpendicular to the forceps, allowing work in parallel. Covidien roticator grasping forceps were used when this appendix-mesentery plane was different[®]. Based on selection criteria, our study did not include complicated appendicitis. In some patients, we had difficulty with dissection, which can explain our complication rate. Some studies²⁰ do not find statistically significant differences in complicated appendicitis with regard to surgery time. Other studies^{19,21} do find differences, however, not between uncomplicated appendicitis and appendicitis

with normal characteristics. Our study showed a difference of about 5 min between the two techniques; in clinical practice, this would have no impact on patient outcomes.

There was no difference in hospital stay; the two groups started oral intake at 5 h after surgery and early mobilization between 6 and 8 h after surgery. Although some series show greater post-surgery satisfaction with SILS-based surgery,¹⁶ post-surgery pain was significantly higher in this group ($P=.004$), coinciding with other authors.²²⁻²⁵ Pain was assessed using the VAS nursing record and the surgeon's assessment at discharge time, with the patient's postural movements, cough or Valsalva maneuver.

Although the sum of all wounds caused by trocars cannot be related to pain, it is important to take into account that the tissue injury of the abdominal wall in either of these 2 techniques would be virtually the same with regard to the extent or sum of lengths. The length of the incision with SILS is 2.5–3 cm, and for CL with 3 trocars is approximately 2.6 cm. Likewise, keep in mind that with SILS, only the aponeurosis is incised, while with CL muscles are traversed, incurring an increased risk of vascular damage, such as the epigastric arteries.²⁶ The use of bladeless trocars could further reduce the rate of post-surgery pain in the CL group.

Higher complication rates in patients with complicated appendicitis have been described. In our study, the major complications are derived from gangrenous appendicitis or more operating time due to difficulty in dissection. The surgical wound infection rate, strictly following the diagnostic criteria established by CDC (erythema, wound pain or turbid serous or purulent content excretion), was 3.3%, and although high, it is similar to some studies described in the literature.^{16,27} Of the 4 cases observed (2 for SILS and 2 for CL), incidence was lower than that reported by other authors,²⁸ and did not correlate with longer surgery time, difficulties in surgical procedure or contamination when removing the surgical specimen. It is known that the incidence of intra-abdominal abscess is higher in obese patients or those with complicated appendicitis; the study does not include this criteria. However, despite being uncomplicated appendicitis, we had 3 cases (2 for SILS and 1 for CL) that were associated with longer surgery time, difficulty with dissection, and greater manipulation of the surgical specimen.²⁹ For the 3 cases observed, 2 corresponded to suppurative appendicitis and one gangrenous case; abundant intra-abdominal lavage was performed without leaving a drain. Thus, uncontrolled intra-abdominal lavage in the context of a difficult appendectomy (loosening of adhesions, thickened meso appendix, suppurating or gangrenous appendix, retrocecal or retroileal appendix) may predispose to a higher incidence of intra-abdominal abscesses.¹⁵

There were 2 cases of hernia, one due to surgical wound infection and the other one probably due to technical or intrinsic factors related to the patient; nevertheless, there were no statistically significant differences ($P>.05$).

Costs were significantly higher ($P<.001$) for SILS, due to the use of the Covidien SILS Port[®], whose price was almost twice the cost of all 3 trocars used for CL, plus the Covidien roticator endograsping forceps[®].

In conclusion, SILS-based appendectomy is an effective, feasible, and safe procedure in selected patients with

uncomplicated acute appendicitis. Post-surgery pain was higher than that in CL, though probably more objective measurement criteria are required. Long-term studies will be needed to demonstrate whether there are differences in the incidence of hernias between SILS and CL. Finally, SILS-based appendectomy is currently more expensive than CL, and long-term results will determine the future of this technique.

Conflict of Interest

The authors have no conflicts of interest to declare.

REFERENCES

- Li X, Zhang J, Sang L, Zhang Z, Chu Z, Liu Y, et al. Laparoscopic versus conventional appendectomy. A meta-analysis of randomized controlled trials. *BMC Gastroenterol.* 2010;10:129–35.
- Vettoretto N, Agresta F. A brief review of laparoscopic appendectomy: the issues and the evidence. *Tech Coloproctol.* 2011;15:1–6.
- Tiwari MM, Reynoso JF, Tsang AW, Oleynikov D. Comparison of outcomes of laparoscopic and open appendectomy in management of uncomplicated and complicates apendicitis. *Ann Surg.* 2011;254:927–32.
- Kala Z, Hanke I, Newmann C. A modified technique in laparoscopic-assisted appendectomy, a transumbilical approach through a single port. *Rozhl Chir.* 1996;75:15–8.
- Esposito C. One-trocar appendectomy in pediatric surgery. *Surg Endosc.* 1998;12:177–8.
- Rispoli G, Armellino MF, Esposito C. One-trocar appendectomy. *Surg Endosc.* 2002;16:833–5.
- Pappaleone N, Tursini S, Marino N, Lisi G, Lelli Chiesa P. Transumbilical laparoscopic-assisted appendectomy (TULAA): a safe and useful alternative for uncomplicated apendicitis. *Eur J Pediatr Surg.* 2002;12:383–6.
- Meyer A, Preuss M, Roesler S, Lainka M, Omlor G. Transumbilical laparoscopic-assisted one trocar appendectomy – TULAA – as an alternative operation method in the treatment of apendicitis. *Zentralbl Chir.* 2004;129:391–5.
- Ahmed K, Wang TT, Patel VM, Nagpal K, Clark J, Ali M, et al. The role of single incision laparoscopic surgery in abdominal and pelvic surgery: a systematic review. *Surg Endosc.* 2011;25:278–96.
- Hong TH, Kim HL, Lee YS, Kim JJ, Park SM, et al. Transumbilical single-port laparoscopic appendectomy (TUSLA): scarless intracorporeal appendectomy. *Laparoendosc Adv Surg Tech A.* 2009;19:75–8.
- Bathia P, Sabharwal V, Kalhan S, John S, Deed JS, Khetan M. Single-incision multiport laparoscopic appendectomy: how I do it. *J Min Access Surg.* 2011;7:28–32.
- Fraser JD, Aguayo P, Shar SW, Snyder CL, Holcomb GW. Physiologic predictors of postoperative abscess in children with perforated appendicitis: subset analysis from a prospective randomized trial. *Surgery.* 2010;147:729–32.
- Sadr Azodi O, Lindstrom D, Adami J, Bellocco R, Linder S, Wladis A. Impact of body mass index and tobacco smoky on outcome alter open appendectomy. *Br J Surg.* 2008;95:751–7.
- Vidal O, Valentin M, Ginesta C, Benarroch G, García-Valdecasas JC. Apendicectomía laparoscópica urgente

- con una sola incisión umbilical (SILS): experiencia inicial. *Cir Esp.* 2009;85:315-24.
15. Hartwich JE, Carter RF, Wolfe L, Goretsky M, Heath K, Lanning DA, et al. The effects of irrigation on outcomes in cases of perforated appendicitis in children. *J Surg Res.* 2013;180:222-5.
 16. Li X, Zhang J, Sang L, Zhang W, Chu Z, Liu Y, et al. Laparoscopic versus convencional appendectomy – a meta-analysis of randomized controlled trials. *BMC Gastroenterol.* 2010;10:129.
 17. Korndorffer JR, Fellingner E, Reed W. SAGES guideline for laparoscopic appendectomy. *Surg Endosc.* 2009;24:757-61.
 18. Vettoretto N, Gobbi S, Corradi A, Belli F, Piccolo D, Pernazza G, et al. The Italian association of hospital surgeons: consensus conference on laparoscopic appendectomy: development of guidelines. *Colorectal Dis.* 2011;13:748-54.
 19. Frutos M, Abrisqueta J, Luján J, Abellán I, Parrilla P. Randomized prospective study to compare laparoscopic appendectomy versus umbilical single-incision appendectomy. *Ann Surg.* 2013;257:413-8.
 20. Lee JA, Sung KY, Lee JH, Lee DS. Laparoscopic appendectomy with a single incision in a single institute. *J Korean Soc Coloproctol.* 2010;26:260-4.
 21. St. Peter SD, Adibe OO, Juang D. Single incision versus 3 port laparoscopic appendectomy: a prospective randomized trial. *Ann Surg.* 2011;254:586-90.
 22. Park JH, Hyun KH, Park CH, Choi SY, Choi WH, Kim DJ. Laparoscopic vs transumbilical single-port laparoscopic appendectomy: results of prospective randomized trial. *J Korean Surg Soc.* 2010;78:213-8.
 23. Kim HJ, Lee JI, Lee SC, Kim SH, Lee IK, Lee YS. Single-port laparoscopic appendectomy. *J Korean Surg Soc.* 2010;78:338-42.
 24. Kang KC, Youn S, Baek D, Kim SH, Oh JT, Lee JK, et al. Application of single incision laparoscopic surgery for appendectomy in patients with complicated apendicitis. *J Korean Soc Coloproct.* 2010;26:388-94.
 25. Lee WS, Choi ST, Lee JN, Kim HK, Park YH, Lee WK, et al. Single-port laparoscopic appendectomy versus convencional laparoscopic appendectomy: a prospective randomized controlled study. *Ann Surg.* 2013;257:214-8.
 26. Saber AA, Meslemani AM, Davis R, Pimentel R. Safety zones for anterior abdominal wall entry during laparoscopy: a CT scan mapping of epigastric vessels. *Ann Surg.* 2004;239:182-5.
 27. D'Ouzou N. Appendicitis. *Clin Evid.* 2011;26:260-4.
 28. Nataraja RM, Teague WJ, Galea J, Moore L, Haddad MJ, Clarke SA, et al. Comparison of intraabdominal abscess formation after laparoscopic and open appendicectomies in children. *J Pediatr Surg.* 2012;47:317-21.
 29. Gupta R, Sample C, Bamehriz F, Birch DW. Infectious complications following laparoscopic appendectomy. *Can J Surg.* 2006;49:397-400.