

Image of the month

Lithopedion[☆]

Litopedion

Fernando Bazan,^{*} Aleksandar Radosevic, Guadalupe Aguilar, Juan Sanchez

Servicio de Radiodiagnóstico, Hospital del Mar, Barcelona, Spain

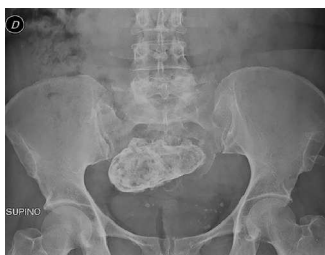

Fig. 1

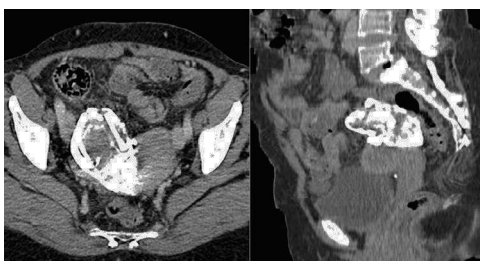


Fig. 2

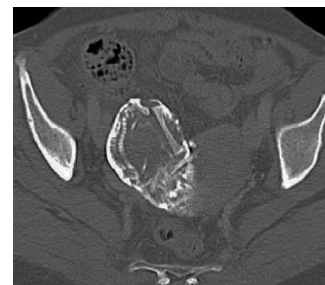

Fig. 3

A 48-year-old woman, who had had a previous right ectopic pregnancy that was operated on 25 years earlier, came to our hospital due to coxalgia. Radiography (Fig. 1) identified a calcified hypogastric mass. CT was performed due to suspected calcified uterine fibroid, teratoma, hydatid cyst or textiloma. A calcified tumor was detected that measured 9.5 cm×5.2 cm adjacent to the upper right side of the uterus (Fig. 2). On the bone window setting, the mass was seen to be a fetal skeleton that was at approximately 24 weeks of gestation (Fig. 3), compatible with lithopedion from an extrauterine pregnancy.

For now, the patient has decided not to undergo surgery as the possible complications are infection, bowel obstruction, fistulas and hemorrhage.

Funding

The authors have required no funding in the preparation of this publication.

Conflicts of Interest

The authors have no conflicts of interest to declare.

[☆] Please cite this article as: Bazan F, Radosevic A, Aguilar G, Sanchez J. Litopedion. Cir Esp. 2014;92:e45.

^{*} Corresponding author.

E-mail address: ferx.bazan@gmail.com (F. Bazan).