

## Image of the month

Hepatic Herniation After Sternotomy<sup>☆</sup>

## Eventración hepática tras esternotomía

Arantza Olaizola Ayerdi,<sup>a,\*</sup> Enrique Cormenzana Lizarribar,<sup>a</sup> Julio César Zeballos Quiroz,<sup>a</sup>  
José Ángel Torená Iburguren<sup>b</sup>

<sup>a</sup> Servicio de Cirugía General, Hospital Comarcal del Bidasoa, Hondarribi, Spain

<sup>b</sup> Servicio de Radiología, Hospital Comarcal del Bidasoa, Hondarribi, Spain

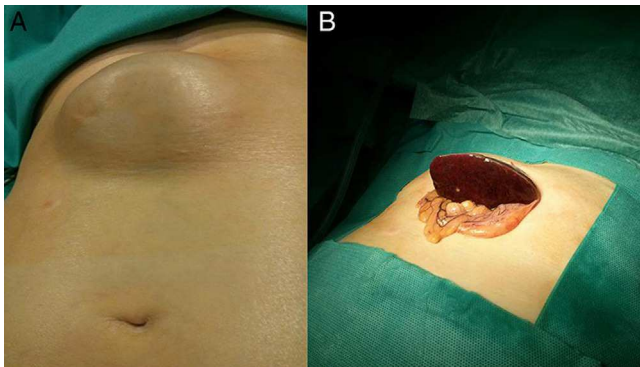


Fig. 1

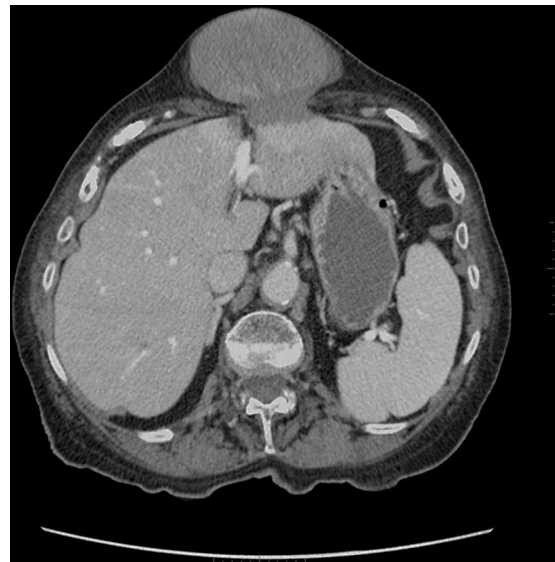

Fig. 2

The patient is a 90-year-old woman with a history of hypertension, AFib and sternotomy for a valve substitution in 2008. She reported a subxiphoid mass ever since the sternotomy, which it was decided not to treat because of the age of the patient. She consulted due to vomiting and epigastric pain, and upon examination a subxiphoid incisional hernia was detected (Fig. 1), which was irreducible and contained what appeared to be the liver. Lab work showed GPT 234 U/L and GOT 141 U/L. Abdominal CT (Fig. 2) showed partial herniation of the left liver lobe with compromised vascular function. The patient underwent emergency surgery, which entailed laparotomy, reduction of the herniated liver and repair of the defect with intraperitoneal dual-layer mesh. The patient was discharged on the 4th day post-op.

Diagnosis: hepatic herniation after sternotomy.

<sup>☆</sup> Please cite this article as: Olaizola Ayerdi A, Cormenzana Lizarribar E, Zeballos Quiroz JC, Torená Iburguren JÁ. Eventración hepática tras esternotomía. Cir Esp. 2014;92:625.

\* Corresponding author.

E-mail address: [arantza.olaizolaayerdi@osakidetza.net](mailto:arantza.olaizolaayerdi@osakidetza.net) (A. Olaizola Ayerdi).

2173-5077/\$ – see front matter © 2014 AEC. Published by Elsevier España, S.L.U. All rights reserved.