

Image of the month

Single Rib Metastasis of Follicular Thyroid Cancer[☆]

Metástasis costal única de cáncer folicular de tiroides

Clara Palomares Avilés,^a María D. Balsalobre Salmeron,^{b,*} María Aránzazu García Lopez,^b
Manuel Martín López^a

^a Servicio de Endocrinología y Nutrición, Hospital Universitario Santa Lucía, Cartagena, Murcia, Spain

^b Unidad de Cirugía Endocrina, Servicio de Cirugía General, Hospital Universitario Santa Lucía, Cartagena, Murcia, Spain

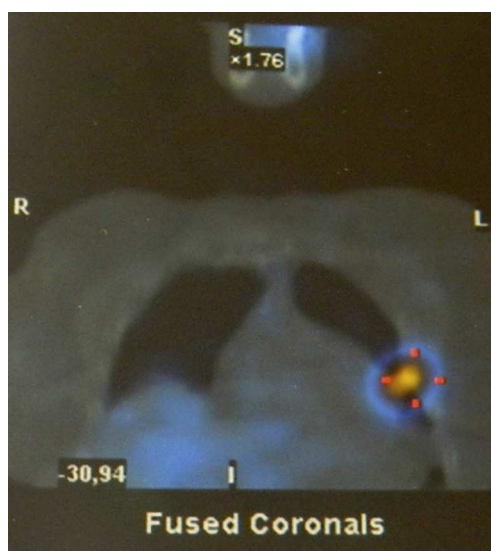


Fig. 1

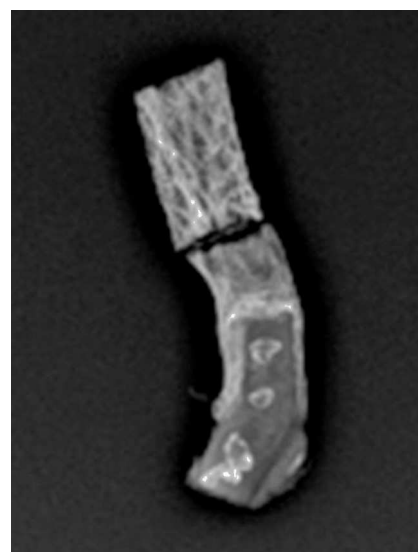


Fig. 2

The patient is a 64-year-old woman with a history of right hemithyroidectomy 35 years earlier due to follicular thyroid cancer. Thirty-three years later, the thyroidectomy was completed. The extension study at that time ruled out distant metastasis and the patient received an ablative dose of I^{131} (150 mCi). Two years afterwards, high thyroglobulin levels were detected with a tracking image of a single metastasis in the costal region (Fig. 1). The fifth rib on the left side was partially resected, and a radiograph of the resected area (Fig. 2) confirmed the presence of metastasis. The pathology study demonstrated bone metastasis of follicular thyroid cancer. Two months into follow-up, normalization of thyroglobulin levels was observed.

[☆] Please cite this article as: Palomares Avilés C, Balsalobre Salmeron MD, García Lopez MA, Martín López M. Metástasis costal única de cáncer folicular de tiroides. Cir Esp. 2014;92:e51.

* Corresponding author.

E-mail address: mariadolores.balsalobre2@um.es (M.D. Balsalobre Salmeron).