

REFERENCES

- Serra C, Baltasar A, Andreo L, Pérez N, Bou R, Bengochea M, et al. Treatment of gastric leaks with coated self-expanding stents after sleeve gastrectomy. *Obes Surg*. 2007;17:866-72.
- Casella G, Soricelli E, Rizzello M, Trentino P, Fiocca F, Fantini A, et al. Nonsurgical treatment of staple line leaks after laparoscopic sleeve gastrectomy. *Obes Surg*. 2009;19:821-6.
- Salinas A, Baptista A, Santiago E, Antor M, Salinas H. Self-expandable metal stents to treat gastric leaks. *Surg Obes Relat Dis*. 2006;2:570-2.
- Márquez MF, Ayza MF, Lozano RB, Morales Mdel M, Díez JM, Poujoulet RB. Gastric leak after laparoscopic sleeve gastrectomy. *Obes Surg*. 2010;20:1306-11.
- Evrard S, Le Moine O, Lazaraki G, Dormann A, El Nakadi I, Devière J. Self-expanding plastic stents for benign esophageal lesions. *Gastrointest Endosc*. 2004;60:894-900.
- Eloubeidi MA, Talreja JP, Lopes TL, Al-Awabdy BS, Shami VM, Kalaleh M. Success and complications associated with placement of fully covered removable self-expandable metal stents for benign esophageal diseases. *Gastrointest Endosc*. 2011;73:673-81.
- Van Boeckel PG, Sijbring A, Vleggaar FP, Siersema PD. Systematic review: temporary stent placement for benign rupture or anastomotic leak of the oesophagus. *Aliment Pharmacol Ther*. 2011;33:1292-301.
- Van Boeckel PG, Dua KS, Weusten BL, Schmits RJH, Surapaneni N, Timmer R, et al. Fully covered self-expandable metal stents (SEMS), partially covered SEMS and self-expandable plastic stents for the treatment of benign esophageal ruptures and anastomotic leaks. *BMC Gastroenterol*. 2012;12:19.
- Hirdes MMC, Vleggaar FP, Van der Linde K, Willems M, Totte E, Siersema PD. Esophageal perforation due to removal of partially covered self-expanding metal stents placed for benign perforation or leak. *Endoscopy*. 2011;43:156-9.
- Hirdes MM, Siersema PD, Houben MH, Weusten BL, Vleggaar FP. Stent-in-stent technique for removal of embedded esophageal self-expanding metal stents. *Am J Gastroenterol*. 2011;106:286-93.

Lorea Zubiaga^{a,*}, Jaime Ruiz-Tovar^a, Javier Sola-Vera^b, Francisco Uceda^b, Rafael Calpena^a

^aUnidad de Cirugía Bariátrica y Metabólica, Servicio de Cirugía General y del Aparato Digestivo, Hospital General Universitario de Elche, Elche, Alicante, Spain

^bSección de Endoscopias, Unidad de Cirugía Bariátrica y Metabólica, Servicio de Medicina Digestiva, Hospital General Universitario de Elche, Elche, Alicante, Spain

*Corresponding author.

E-mail address: loreazubiaga@gmail.com (L. Zubiaga).

2173-5077/

© 2014 AEC. Published by Elsevier España, S.L.U. All rights reserved.

Laparoscopic First Stage in a Two-Stage Hepatectomy[☆]

Primer tiempo laparoscópico en una cirugía hepática en 2 tiempos

The resection of hepatic metastasis (HM) of colorectal cancer increases survival, and in some cases the 5-year survival rate reaches 50%.¹⁻⁴ The major problem is that only 20%-25% of HM are initially resectable, which is usually due to insufficient future remnant liver volume.⁴⁻⁸ In patients with initially unresectable HM, there are several strategies used to increase resectability: *in situ* split, neoadjuvant chemotherapy, combined surgery and radiofrequency ablation, and two-stage (TS) surgery combined with portal embolization, developed by Adam et al.^{1,4-8}

In the first stage of TS surgery, the metastases located in the future remnant (usually the left liver) are resected.^{1,5-9} After portal vein ligation or embolization, the second stage of surgery involves major hepatectomy of the embolized lobe.^{1,5-8} TS surgeries are generally performed by means of laparo-

scopy. However, we present our experience using laparoscopy for the first stage.

We present the results of patients who had been treated with a TS liver surgery strategy in whom the first stage involved a laparoscopic approach in the period between January 2007 and December 2012. Fifty-seven patients underwent HM, and 6 were treated with a TS strategy (10.5%). All patients had synchronous bilobar liver metastases in whom, after CT volumetry, it was determined that there would not be sufficient remnant for one-stage liver surgery (<30%).

In 3 patients, the first stage of surgery was performed using a laparoscopic approach. In the remaining 3 patients, laparotomy was used due to the anatomical location of the HM. **Table 1** presents the clinical characteristics of the patients who were treated by laparoscopy. All the liver resections were performed in 20° reverse Trendelenburg lithotomy position. The approach utilized 3 trocars: one 5 mm in the right hypochondrium, one umbilical 11 mm trocar and one 12 mm in the left

[☆] Please cite this article as: Ramia JM, Adel F, de La Plaza R, Veguillas P, García-Parreño J. Primer tiempo laparoscópico en una cirugía hepática en 2 tiempos. *Cir Esp*. 2015;93:125-127.

Table 1 – Clinical Characteristics of Patients Who Were Treated by Laparoscopy.

Age	Gender	Colon tumor	pT/pN/pM	Total number of HM	Surgery type	1st stage of surgery	Liver surgery	Surgical piece (cm)	Lesion size (cm)	Weight (g)	Margen (mm)	Morb.	Hospital stay (days)
53	Male	Rectum	pT3pN2pM1	6: 2 left+4 right	Reverse	Hepatic	Wedge	3.5×2.0×2.0	1.5/1	38	5 mm	No	2
62	Female	Rectum	pT3pN2pM1	7: 2 left+5 right	Combined	Hepatic+colon (AR)	Wedge	4.5×2.5×1.8	1.5/1.1	12	5 mm	No	5
68	Male	Splenic angle	pT3pN1pM1	6: 2 left+4 right	Combined	Hepatic+colon (left hemi.)	Partial resection seg. 2 and 3	11×5×7	2/0.7	172	7 mm	No	6

HM: hepatic metastasis.

hypochondrium. The procedures included: 2 limited resections and 1 partial left lateral sectionectomy (Fig. 1). Afterwards, 2 trocars were added to perform the colorectal surgery.

In 2 patients, laparoscopic surgery of the colorectal tumor was combined with laparoscopic liver resection (anterior resection and left hemicolectomy). In the third patient, who had presented occlusive symptoms due to a rectal neoplasm, we inserted an auto-expandable stent using reverse surgery. Morbidity was 0%. The hospital stay was 2 days for the patient who only underwent liver surgery, and 5 and 6 days in the patients with combined laparoscopic colon resection. After 10 days, all 3 patients underwent percutaneous portal vein embolization, and right hepatectomy was performed one month later using laparotomy. In the second stage, the number of intraabdominal adhesences was minimal and hilar dissection was difficult.

It has been demonstrated that laparoscopic hepatectomies used to treat malignant lesions involve less bleeding, shorter hospitalizations and fewer complications. Quality of life is better than after laparotomy, with the same efficacy and oncologic safety.^{1,3,4,10}

There are very few published cases of totally/partially laparoscopic TS surgeries. In 2010, Machado et al. and Jain et al. published almost simultaneously one totally laparoscopic TS surgery each.^{1,4} Later, in 2012, Robles et al. published another 2 totally laparoscopic TS procedures.⁸ The longest reported experience is that of a series of 8 partially/totally laparoscopic TS strategies, 5 with an initial laparoscopic stage and a second laparotomy stage, one conversion to laparotomy, and only 2 completely laparoscopic cases.⁶

The first stage of TS can usually be completed laparoscopically as it generally entails minor hepatectomy of the left liver, which may or may not be associated with colon surgery and/or right portal vein ligation.^{2,6,11} Although it is feasible and provides good results, laparoscopic right portal ligation has been done in few patients.² The advantages of an initial laparoscopic stage are: fewer intraabdominal adhesences (but not hilar), correct staging, less pain, shorter hospitalization, faster recuperation, and maintained abdominal wall integrity.^{1,6,9} The second part of TS (major hepatectomy) can be done using either laparoscopy or laparotomy, but major laparoscopic hepatectomies require a high level of technical skill, and their use still has not become widespread.^{3,6}

Another point of debate is combined laparoscopic hepatic and colorectal surgery. Classically, in patients with synchronous HM, combined surgery was not performed as it was argued to have higher morbidity and mortality than sequential procedures, especially in rectal tumors or major hepatectomies.^{8,9} However, sequential surgeries also present disadvantages: longer hospitalization, 2 anesthesia times, delayed chemotherapy, etc.⁹ Several series have demonstrated that combined and sequential surgeries obtain similar results. Furthermore, if combined surgery is not used in patients with two-stage surgery, then 3 surgeries are needed.⁵ In 2010, Karoui et al. published a series of 33 patients with exclusively TS combined surgeries, which gave good results (morbidity 21% and mortality 0%).^{5,8,9} The combined laparoscopic approach of colorectal tumors and HM has certain advantages, including simpler access to both intraabdominal regions, abdominal wall preservation, postoperative recovery, hospital

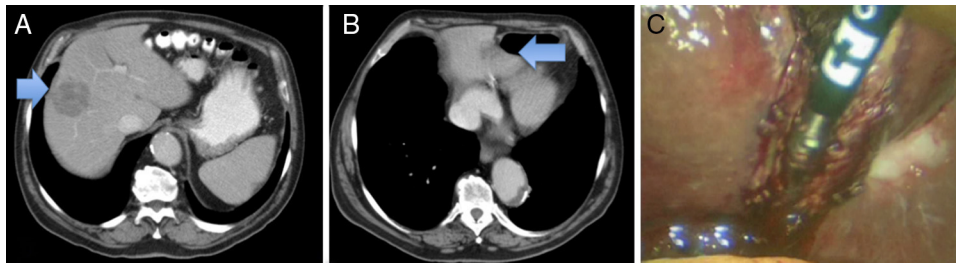


Fig. 1 – CT scan: (A) metastasis of the right liver; (B) metastasis of the left lateral section; (C) laparoscopic resection.

stay, tumor staging, etc., as well as no increase in morbidity or mortality and shorter hospital stay. Even so, it has not become popular.^{5,8-10}

In conclusion, the laparoscopic approach of the first stage in two-stage liver surgery is feasible and provides certain benefits. The combination of colon surgery and minor laparoscopic hepatectomy is safe and also provides certain advantages.

REFERENCES

- Machado MA, Makdissi FF, Surjan RC, Kappaz GT, Yamaguchi N. Two-stage laparoscopic liver resection for bilateral colorectal liver metastasis. *Surg Endosc.* 2010;24:2044-7.
- Ayiomamitis GD, Low JK, Alkari B, Lee SH, Ammori BJ. Role of laparoscopic right portal vein ligation in planning staged or major liver resection. *J Laparoendosc Adv Surg Tech.* 2009;19:409-13.
- Abu Hilal M, di Fabio F, Abu Salameh M, Pearce NW. Oncological efficiency analysis of laparoscopic liver resection for primary and metastatic cancer: a single-center UK experience. *Arch Surg.* 2012;147:42-8.
- Jain G, Parmar J, Mohammed MM, Bryant T, Kitteringham L, Pearce N, et al. Stretching the limits of laparoscopic surgery: two stage laparoscopic liver resection. *J Laparoendosc Adv Surg Tech.* 2010;20:51-4.
- Karoui M, Viganò L, Goyer P, Ferrero A, Aglietta M, Delbaldo C, et al. Combined first stage hepatectomy and colorectal resection in a two-stage hepatectomy strategy for bilobar synchronous liver metastases. *Br J Surg.* 2010;97:1354-62.
- Di Fabio F, Whistance R, Rahman S, Primrose JN, Pearce NW, Abu Hilal M. Exploring the role of laparoscopic surgery in two-stage hepatectomy for bilobar colorectal liver metastases. *J Laparoendosc Adv Surg Tech.* 2012;22:647-50.
- Adam R, Laurent A, Azoulay D, Castaing D, Bismuth H. Two-stage hepatectomy: a planned strategy to treat irresectable liver tumors. *Ann Surg.* 2000;232:777-85.
- Robles R, Marín C, Lopez-Conesa A, Capel A, Perez-Flores D, Parrilla P. Comparative study of right portal vein ligation versus embolisation for induction of hypertrophy in two-stage hepatectomy for multiple bilateral colorectal liver metastases. *Eur J Surg Oncol.* 2012;38:586-93.
- Polignano FM, Quyn AJ, Sanjay P, Henderson NA, Tait IS. Totally laparoscopic strategies for the management of colorectal cancer with synchronous liver metastases. *Surg Endosc.* 2012;26:2571-8.
- Hatwell C, Bretagnol F, Farges O, Belghiti J, Panis Y. Laparoscopic resection of colorectal cancer facilitates simultaneous surgery of synchronous liver metastases. *Colorectal Dis.* 2013;15:e21-8.
- Pessaux P, Panaro F. Advantages of the first-step totally laparoscopic approach in 2-staged hepatectomy for colorectal synchronous liver metastases. *Surgery.* 2008;145:453.

José Manuel Ramia*, Farah Adel, Roberto de La Plaza, Pilar Veguillas, Jorge García-Parreño

Unidad de Cirugía Hepatobiliopancreática, Servicio de Cirugía General y Aparato Digestivo, Hospital Universitario de Guadalajara, Guadalajara, Spain

*Corresponding author.

E-mail address: jose_ramia@hotmail.com (J.M. Ramia).

2173-5077/\$ – see front matter

© 2013 AEC. Published by Elsevier España, S.L.U. All rights reserved.

Conservative “In Situ” Treatment of Pneumoperitoneum[☆]

Tratamiento conservador «in situ» del neumoperitoneo

The radiological finding of free air in the abdominal cavity is generally considered a surgical emergency. It is associated with perforated abdominal viscus in more than 90% of

cases.¹⁻³ Nevertheless, the remaining 10% are not caused by perforation; these cases of non-surgical, asymptomatic, benign, idiopathic pneumoperitoneum are a diagnostic and therapeutic dilemma.²

We present the case of a 77-year-old woman with amyotrophic lateral sclerosis (ALS) who presented dysphagia and nocturnal hypoventilation, so she was admitted to the

[☆] Please cite this article as: Gutiérrez Andreu M, Yuste García P, Gómez Rodríguez P, de la Cruz Vigo F. Tratamiento conservador «in situ» del neumoperitoneo. *Cir Esp.* 2015;93:127-129.