

from the outside.¹⁰ Clinically, these patients can present symptoms compatible with intestinal obstruction, port infection or failure to lose weight.³⁻⁸ As the perforations are slow to develop, they normally do not present peritonitis, which allows the chronic inflammatory reaction to isolate them. In our case, it is interesting that the patient had pancreatitis previously, which seems to have been circumstantial.

Diagnosis is complex, and a high rate of suspicion is necessary. Persistent infection of the port site can be the first manifestation. CT scan with iv contrast should be the diagnostic technique of choice as it is able to more precisely identify the location of the band and determine its repercussions.⁴ Fluoroscopy, on the other hand, is simple to do and detects the migration of the band, while upper gastrointestinal endoscopy can be therapeutic for withdrawal of the band when possible.³

Treatment will depend on symptoms and degree of band migration. If more than 50% of the band's circumference is within the stomach, endoscopic extraction can be attempted, which is less invasive and causes less morbidity.² In cases where it has migrated towards the small bowel or further and is associated with perforations, an open approach is required. The withdrawal of the band followed by immediate reinstallation is not recommended because of the high rates of failure and risk.

REFERENCES

1. McBride CL, Kothari V. Evolution of laparoscopic adjustable gastric banding. *Surg Clin North Am.* 2011;91:1239-47.
2. Sapalidis K, Liavas L, Panteli N, Kosmatopoulos E, Anastasiadis I, Charalambides S, et al. Intrajejunal migration of adjustable gastric band: a case report. *Curr Health Sci J.* 2013;39:118-20.

3. Bueter M, Thalheimer A, Meyer D, Fein M. Band erosion and passage, causing small bowel obstruction. *Obes Surg.* 2006;16:1679-82.
4. Salar O, Waraich N, Singh R, Awan A. Gastric band erosion, infection and migration causing jejunal obstruction. *BMJ Case Rep.* 2013. <http://dx.doi.org/10.1136/bcr-2012-007737>.
5. Lantsberg L, Kirshtein B, Leytzin A, Makarov V. Jejunal obstruction caused by migrated gastric band. *Obes Surg.* 2008;18:225-7.
6. Egbear DM, Myers AF, Lawrance RJ. Small bowel obstruction secondary to intragastric erosion and migration of a gastric band. *J Gastrointest Surg.* 2008;12:983-4.
7. Bassam A. Unusual gastric band migration outcome: distal small bowel obstruction and coming out per-rectum. *Pan Afr Med J.* 2012;13:59.
8. Shah KG, Molmenti EP, Nicasastro J. Gastric band erosion and intraluminal migration leading to biliary and small bowel obstruction: case report and discussion. *Surg Obes Relat Dis.* 2011;7:117-8.
9. Creedon L, Leeder P, Awan A. Laparoscopic adjustable gastric band erosion and migration into the proximal jejunum. *Surg Obes Relat Dis.* 2014;10:e19-21.
10. Tekin A. Migration of the connecting tube into small bowel after adjustable gastric banding. *Obes Surg.* 2010;20:526-9.

Federico Oppliger*, Horacio Ríos, Luis Manríquez

Departamento de Cirugía, Universidad del Desarrollo – Clínica Alemana, Santiago, Chile

*Corresponding author.

E-mail address: foppliger@gmail.com (F. Oppliger).

2173-5077/

© 2014 Published by Elsevier España, S.L.U. on behalf of AEC.

En Masse Reduction of an Incarcerated Inguinal Hernia. Emergency Laparoscopic Management[☆]



Reducción en masa de una hernia inguinal encarcerada. Abordaje urgente por laparoscopia

Reduction *en masse* of an incarcerated inguinal hernia occurs when the hernia sac is reduced in the preperitoneal space after a taxis manoeuvre or during hernia repair surgery. The intestinal loops remain incarcerated in the sac, so the intestinal obstruction continues despite the apparently successful hernia reduction.^{1,2} Reported for the first time by Luke³ in 1843, reduction *en masse* is an extremely rare complication. In 1908, its frequency was estimated by Corner and Howitt⁴ at approximately 0.3% of incarcerated hernias,

although the current incidence is probably lower due to the increase in early-stage hernia repairs.

We report the case of a 40-year-old intellectually disabled man. He came to the Emergency Department due to abdominal pain associated with a painful left inguinal mass, but he was not able to specify when the symptoms had appeared. Upon examination, the abdomen was soft with no signs of peritoneal irritation; peristalsis was audible. In the left inguinal area, there was a painful mass, compatible with

[☆] Please cite this article as: Maupoey Ibáñez J, Carreño Sáenz O, Beltrán Herrera H, Moya Sanz A, Carbonell Tatay F. Reducción en masa de una hernia inguinal encarcerada. Abordaje urgente por laparoscopia. *Cir Esp.* 2015;93:603-605.

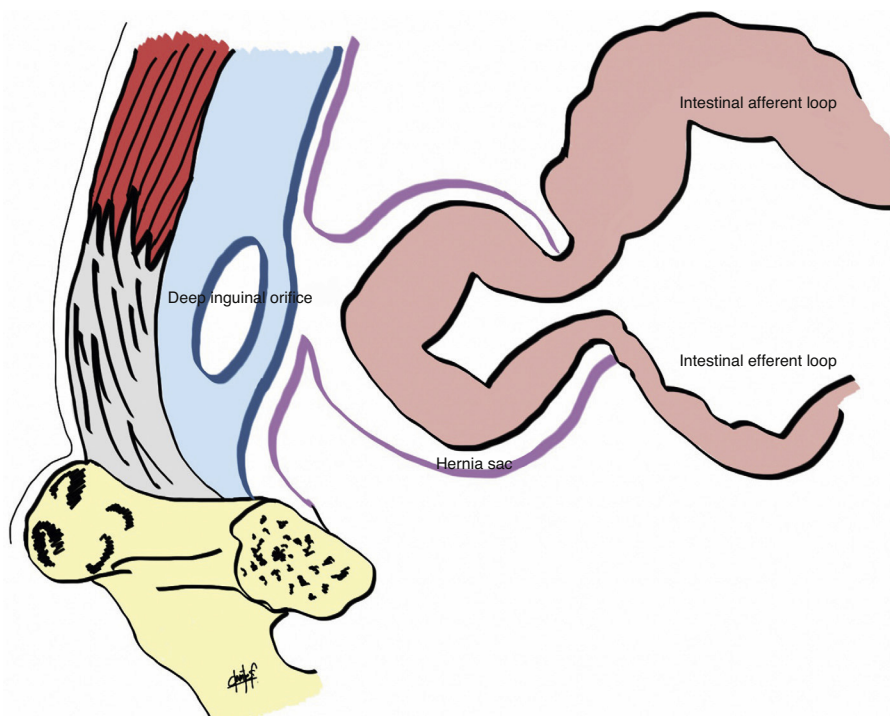


Fig. 1 – Schematic diagram of the reduction *en masse* phenomenon: the small bowel loop was incarcerated in the hernia sac located within the preperitoneal space.

incarcerated inguinal hernia. The mass was spontaneously and completely reduced during a slight exploratory manoeuvre in the Emergency Room. Blood workup and simple abdominal radiograph showed no pathologic findings, so the need for urgent surgical treatment was ruled out; management was planned with hernioplasty scheduled for a later date. Notwithstanding, we decided to keep the patient overnight for observation. Twelve hours later, the patient's condition clearly worsened and he presented symptoms of occlusion and distended small bowel loops on simple abdominal radiograph. However, there was no palpable hernia in the inguinal canal upon examination.

Emergency laparoscopic surgical exploration was indicated. Previous computed tomography was not ordered because the results would not modify the indication for surgery given the worsening symptoms. A 3-port approach was used: 12 mm umbilical incision, and two 5 mm incisions in both iliac fossae on the midclavicular lines. An indirect inguinal hernia was observed with a segment of the incarcerated ileum in a hernia sac situated in the preperitoneal space, over the deep inguinal orifice (Fig. 1). This was released by means of traction manoeuvres; the affected loop had a congested appearance, with no signs of irreversible ischaemia. Afterwards, hernia repair was performed using the transabdominal preperitoneal (TAPP) hernioplasty technique with a 15 cm×10 cm polypropylene mesh placed in the preperitoneal space and attached with a spiral endostapler; closure was done with a peritoneal flap. Before the conclusion of the procedure, we once again verified the viability of the affected bowel segment, which had good colour and had recovered peristalsis. The patient had an uneventful recovery, and he was discharged 3 days after the intervention.

Reduction *en masse* of an inguinal or femoral hernia should be suspected in patients with persistent obstructive symptoms after the apparently effective reduction of an incarcerated hernia. Examination of the inguinal canal will show no evidence of hernia. The diagnosis is confirmed by computed tomography or during surgery, as in the case of our patient. It is important for surgeons to know about this complication because, as it is an uncommon phenomenon, its diagnosis and urgent surgery can be delayed, which can negatively affect prognosis.⁵

Three conditions are necessary for the reduction *en masse* phenomenon to occur: a relatively lax deep inguinal ring, a narrow and fibrous neck of the hernia and a space for the preperitoneal sac.¹ These factors usually coincide in cases of hernias that have progressed over a long period of time, with a previous history of repeated forced reductions.⁶ In this case, we have no idea how long the hernia had been evolving or when the acute symptoms had started. We believe that the decision to keep the patient under observation was correct, as was the indication for urgent surgery, which provided a diagnosis and treatment at the same time.

Several authors have used the laparoscopic approach in this phenomenon to verify the visibility of the affected loop⁷ as well as to provide definitive treatment.⁸ Hernioplasty using the TAPP technique can be used to manage incarcerated hernias with satisfactory results.⁹ First of all, the incarceration is released, which will occasionally require a small herniotomy on the fibrous neck and later hernia repair¹⁰ (Fig. 2). Although it was not the case in this patient, if there were irreversible ischaemia of the affected loop, bowel resection can be done by mini-laparotomy after concluding the hernioplasty. We should also mention the option of an open

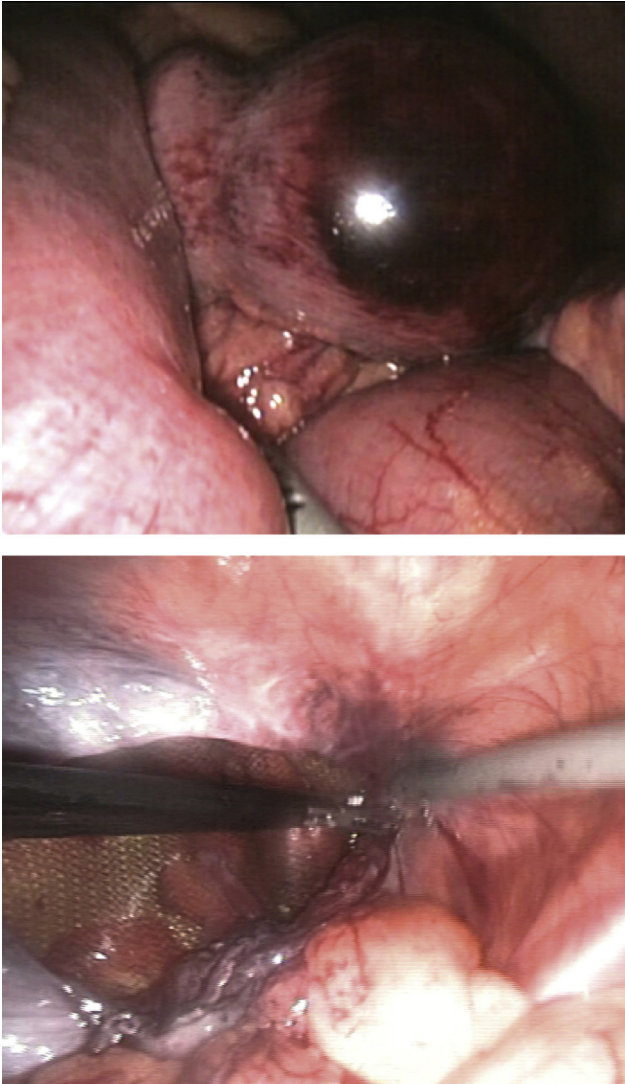


Fig. 2 – Reduction and exploration of incarcerated small bowel segment and hernia repair by means of transabdominal preperitoneal hernioplasty (TAPP technique).

preperitoneal approach (which allows for the affected loop to be evaluated), bowel resection without midline laparotomy (if needed), and hernia repair (which could also be done with locoregional anaesthesia).

In conclusion, reduction *en masse* is an uncommon complication that requires a high rate of suspicion for early diagnosis and treatment. We suggest the laparoscopic surgical approach and hernia repair with the TAPP technique as an

effective, less invasive method that accelerates the recovery process, which justifies its use in these patients.

Conflict of Interests

The authors declare having no conflict interest.

REFERENCES

1. Ravikumar H, Babu S, Govindrajan M, Kalyanpur A. Reduction en-masse of inguinal hernia with strangulated obstruction. *Biomed Imaging Interv J.* 2009;5:e14.
2. Wright RN, Arensman RM, Coughlin TR, Nyhus LM. Hernia reduction en masse. *Am Surg.* 1977;43:627-30.
3. Luke J. Cases of strangulated hernia reduced “en masse,” with observations. *Med Chir Trans.* 1843;6:159-87.
4. Corner EM, Howitt AB. The reduction en masse of strangulated and non-strangulated herniae. *Ann Surg.* 1908;47:573-87.
5. Sahoo MR, Kumar A. Laparoscopic management of reduction-en-masse. *BMJ Case Rep.* 2012;20:2012.
6. Casten D, Bodenheimer M. Strangulated hernia reduction en masse. *Surgery.* 1941;9:561-6.
7. Altaf N, Ahmed J, Doran J. Laparoscopic assessment of bowel viability after reduction en masse. *Ann R Coll Surg Engl.* 2006;88:316-22.
8. Kaiwa Y, Namiki K, Matsumoto H. Laparoscopic relief of reduction en masse of incarcerated inguinal hernia. *Surg Endosc.* 2003;17:352.
9. Legnani GL, Rasini M, Pastori S, Sarli D. Laparoscopic transperitoneal hernioplasty (TAPP) for the acute management of strangulated inguino-crural hernias: a report of nine cases. *Hernia.* 2008;12:185-8.
10. Wu CC, Kang JC, Huang YM. Laparoscopic transabdominal preperitoneal hernioplasty for reduction en masse of an incarcerated inguinal hernia: a case report. *J Gastrointest Surg.* 2012;16:1433-5.

Javier Maupoey Ibáñez*, Omar Carreño Sáenz, Homero Beltrán Herrera, Amparo Moya Sanz, Fernando Carbonell Tatay

Servicio de Cirugía General y del Aparato Digestivo, Hospital Universitario y Politécnico La Fe, Valencia, Spain

*Corresponding author.

E-mail address: javiermaupoey@gmail.com (J. Maupoey Ibáñez).

2173-5077/

© 2013 AEC. Published by Elsevier España, S.L.U. All rights reserved.