



Scientific letter

Perforated Hemorrhagic Cholecystitis[☆]

Colecistitis hemorrágica perforada

Hemorrhagic cholecystitis is an uncommon, acute, serious complication of acute cholecystitis that may or may not be associated with lithiasis. Due to inflammatory changes, the hemorrhage causes ulceration of the mucosa and necrosis, distends the gallbladder and finally leads to its rupture and haemoperitoneum. The most frequent site of the perforation is the fundus of the gallbladder due to poor vascular irrigation.¹

We present the case of a 59-year-old male patient who was allergic to ampicillin, was an ex-smoker, and had alcoholic cirrhosis. He came to the emergency room (ER) due to colicky abdominal pain in the right hypochondrium and jaundice that had been progressing for several days and was increasing. The ER work-up showed: total bilirubin 5.20 mg/dL, glutamic-pyruvic transaminase (GPT) 69.00 U/L, glutamate-oxaloacetate-transaminase (GOT) 114 U/L, gamma-glutamyl-transferase (GGT) 1294 U/L and prothrombin activity 65%. In the ER, the patient presented symptoms of shock with arterial hypotension (70/30 mmHg), abdominal distension and signs of peritonism that required the intervention of the intensive care unit, with emergency intubation and haemodynamic stabilisation with vasoactive drugs. Abdominal CT scan reported "Perisplenic and perihepatic hyperdense fluid, and a very distended gallbladder with hyperdense material in its interior associated with cholelithiasis. Compatible with haemocholecystitis open to the peritoneum and active extravasation of contrast" (Figs. 1 and 2).

Given the abdominal CT scan findings and the situation of shock of the patient, emergency surgery was indicated.

Urgent midline exploratory laparotomy detected massive haemoperitoneum with a perforated gallbladder and capillary bleeding in its interior, as well as macronodular cirrhosis, without any other identified bleeding point. Cholecystectomy was performed. The patient's condition progressed favourably during hospitalisation, and he was discharged on the ninth day post-op, without incident.

The pathology study reported hemorrhagic cholecystitis.

Hemorrhagic cholecystitis is a rare emergency associated with high mortality. Most perforations of the gallbladder occur in lithiasic cholecystitis (3%–10%)¹ and are much less frequent in alithiasic types.² Atherosclerotic changes in the gallbladder wall represent the most common predisposing factor.³

Perforation of the gallbladder can be seen as an acute process with the leakage of bile to the peritoneal cavity (type I), subacute symptoms that cause a gallbladder abscess (type II), or a chronic process with the formation of a cholecystoenteric or cholecystocutaneous fistula (type III).⁴

Involved in the aetiology are gallstones (50% of cases), anticoagulation,⁵ antiaggregation or coagulopathies, gallbladder cancer, trauma, portal hypertension, corticosteroid therapy, blood dyscrasia, ectopic gastric or pancreatic mucosa and parasites.⁶

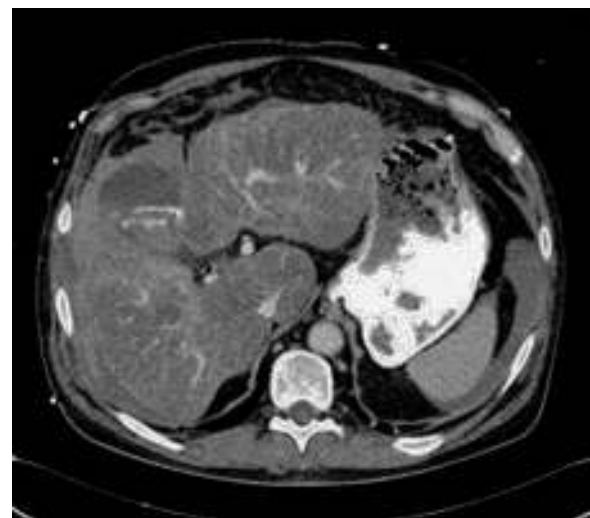

Fig. 1 – Abdominal CT scan: hyperdense perihepatic fluid; distended gallbladder and active extravasation of contrast material in its interior.

[☆] Please cite this article as: Calvo Espino P, Chaparro Cabezas MD, Jiménez Cubedo E, Lucena de la Poza JL, Sánchez Turrión V. Colecistitis hemorrágica perforada. Cir Esp. 2016;94:e35-e36.

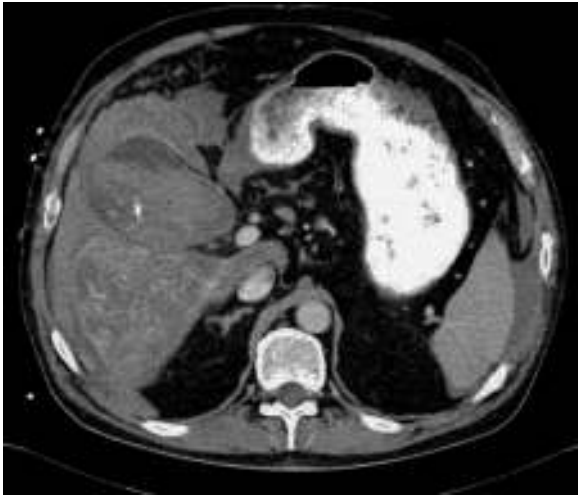


Fig. 2 – Abdominal CT scan: haemocholecystitis; active extravasation of gallbladder contrast.

When there is a hemorrhage in the gallbladder, it can be evacuated through the cystic duct, which causes abdominal pain, bile duct obstruction, jaundice, and/or haematemesis. In the presence of cholelithiasis, with a gallstone in the infundibulum or cystic duct that impedes the blood to flow out, the gallbladder will become distended, causing its rupture and haemoperitoneum.

Ultrasound and CT scans are the main diagnostic tests utilised in hemorrhagic cholecystitis. On ultrasound (with a sensitivity of 38.4%),⁷ the blood is seen as a hyperechoic material in the lumen, and on CT (with a sensitivity of 69.2%)⁷ it is seen with greater intensity than the bile and gallstones.² On CT scans with contrast material, leaks are occasionally observed from the gallbladder lumen.⁵ The main disadvantage of both tests is the difficult diagnosis of the gallbladder wall defect, especially when contrast material is not used. Magnetic resonance is more sensitive for detecting a rupture and for distinguishing blood from the ascitic liquid. The greatest disadvantage of this test is its limited availability in emergency departments.

The treatment of choice is emergency surgical intervention, either by laparoscopy or laparotomy, in combination with antibiotic treatment.⁸

In short, hemorrhagic cholecystitis is an uncommon condition with high morbidity and mortality, which presents as symptoms of abdominal pain and shock. Certain imaging tests, such as CT scan with contrast material in our case, can aid in the diagnosis, and treatment is emergency surgery.

Conflict of Interests

The authors have no conflict of interests to declare.

REFERENCES

1. Roslyn J, Busuttill RW. Perforation of the gallbladder: a frequently mismanaged condition. *Am J Surg.* 1979;137:307–12.
2. Tavernaraki K, Sykara A, Tavernaraki E, Chondros D, Lolis ED. Massive intraperitoneal bleeding due to hemorrhagic cholecystitis and gallbladder rupture: CT findings. *Abdom Imaging.* 2011;36:565–8.
3. Demir MK, Kilicoğlu G, Akinci O. Case report: perforated haemorrhagic cholecystitis: MR imaging features. *Clin Radiol.* 2006;61:899–901.
4. Roslyn JJ, Thompson JE Jr, Darvin H, DenBesten L. Risk factors for gallbladder perforation. *Am J Gastroenterol.* 1987;82:636–40.
5. Pandya R, O'Malley C. Hemorrhagic cholecystitis as a complication of anticoagulant therapy: role of CT in its diagnosis. *Abdom Imaging.* 2008;33:652–3.
6. Morris DS, Porterfield JR, Sawyer MD. Hemorrhagic cholecystitis in an elderly patient taking aspirin and cilostazol. *Case Rep Gastroenterol.* 2008;2:203–7.
7. Kim PN, Lee KS, Kim IY, Bae WK, Lee BH. Gallbladder perforation: comparison of US findings with CT. *Abdom Imaging.* 1994;19:239–42.
8. Vijendren A, Cattle K, Obichere M. Spontaneous haemorrhagic perforation of gallbladder in acute cholecystitis as a complication of antiplatelet, immunosuppressant and corticosteroid therapy. *BMJ Case Rep.* 2012. 92012.

Pablo Calvo Espino*, María Dolores Chaparro Cabezas, Elena Jiménez Cubedo, José Luis Lucena de la Poza, Víctor Sánchez Turrión

Servicio de Cirugía General y Aparato Digestivo, Hospital Universitario Puerta de Hierro-Majadahonda, Majadahonda, Madrid, Spain

*Corresponding author.

E-mail address: pcalvoespino@gmail.com (P. Calvo Espino).

2173-5077/

© 2014 AEC. Published by Elsevier España, S.L.U. All rights reserved.