



## Original article

# Clinical Results of a New Strategy (Modified CHIVA) for Surgical Treatment of Anterior Accessory Great Saphenous Varicose Veins<sup>☆,☆☆</sup>



Nicolás Maldonado-Fernández,<sup>a</sup> Jose Patricio Linares-Palomino,<sup>b,\*</sup> Cristina López-Espada,<sup>b</sup> Francisco Javier Martínez-Gómez,<sup>a</sup> Eduardo Ros-Díe<sup>b</sup>

<sup>a</sup>Servicio de Angiología y Cirugía Vasculard, Complejo Hospitalario de Jaén, Hospital Universitario Médico-Quirúrgico, Jaén, Spain

<sup>b</sup>Departamento de Cirugía, Universidad de Granada, Granada, Spain

## ARTICLE INFO

## Article history:

Received 27 September 2015

Accepted 31 October 2015

Available online 8 March 2016

## Keywords:

Anterior accessory great saphenous vein

Haemodynamic venous surgery

CHIVA technique

Varicose veins surgery

## A B S T R A C T

**Introduction:** Traditionally, anterior accessory great saphenous vein insufficiency was managed by crossectomy and resection of varicose veins. The aim of this paper is to show the safety and efficacy of a new therapeutic strategy for anterior accessory great saphenous varicose veins.

**Methods:** This non-randomised prospective study included 65 patients with varicose veins from the anterior accessory great saphenous vein. The novelty of the technique is to avoid the great saphenous vein crossectomy and perform just flebectomy of the visible veins. Venous duplex studies were performed preoperatively, a month and a year postoperatively. The clinical assessment was done by the Fligelstone scale.

**Results:** The baseline CEAP clinical classification was: 58% C2, 26% C3 and 15% C4-6. The new strategy was applied to all cases. Complications: 3 haematomas, 7 cases of asymptomatic partial anterior saphenous thrombosis. Reduction of the initial average diameter was from 6.4 mm anterior saphenous to 3.4 mm by one year ( $P < .001$ ). At twelve months a forward flow is maintained in 82% of cases. Recurrence of varicose veins was 8%. All patients improved their clinical status based on the Fligelstone scale. Cases with saphenous diameter bigger than 7.5 mm and obesity were identified as predictors of worse clinical and haemodynamic outcome.

**Conclusions:** This modified surgical strategy for anterior saphenous varicose veins results in better clinical outcomes at one year postoperatively.

© 2015 AEC. Published by Elsevier España, S.L.U. All rights reserved.

<sup>\*</sup> The content of this article is original and has not been submitted for consideration at any other publication, either in its entirety or partially. Preliminary results of this study were presented at the 30th Conference of the Andalusian Society of Angiology and Vascular Surgery in 2013 and included in the supplement of the scientific journal *Actualidad Médica* that was published in relation to the conference: *Actual Med* 2013; 98: (789). Supl. 13-16.

<sup>\*\*</sup> Please cite this article as: Maldonado-Fernández N, Linares-Palomino JP, López-Espada C, Martínez-Gómez FJ, Ros-Díe E. Resultados clínicos de una nueva estrategia quirúrgica (CHIVA modificado) en el tratamiento de las varices dependientes de la vena safena magna accesoria anterior. *Cir Esp*. 2016;94:144-150.

<sup>\*</sup> Corresponding author.

E-mail address: [jlinaresp@ugr.es](mailto:jlinaresp@ugr.es) (J.P. Linares-Palomino).

## Resultados clínicos de una nueva estrategia quirúrgica (CHIVA modificado) en el tratamiento de las varices dependientes de la vena safena magna accesoria anterior

### R E S U M E N

#### Palabras clave:

Vena safena magna accesoria anterior  
Cirugía hemodinámica venosa  
Técnica CHIVA  
Cirugía de varices

**Introducción:** Tradicionalmente la insuficiencia de safena anterior se trataba mediante cosectomía y resección de los paquetes varicosos. El objetivo del trabajo es mostrar la seguridad y eficacia de una nueva estrategia terapéutica en las varices dependientes de la vena safena magna accesoria anterior.

**Métodos:** Estudio prospectivo no randomizado que incluyó 65 pacientes con varices dependientes de la safena anterior con safena interna anterógrada. La modificación en la técnica consiste en hacer solamente flebectomía de los paquetes varicosos, sin ligar el cayado de la safena. Se realizó un estudio hemodinámico venoso preoperatorio, al mes y al año, y para la valoración clínica se utilizó la escala de Fligelstone.

**Resultados:** Clasificación clínica basal CEAP: C2 58%, C3 26% y C4-6 15%. Complicaciones: 3 hematomas, 7 casos de trombosis parciales asintomáticas de safena anterior. Se observó una reducción del diámetro medio inicial de safena anterior de 6,4 mm a 3,4 mm al año ( $p < 0,001$ ). A los doce meses mantenían un flujo anterógrado el 82% de los casos. Hubo una recidiva de varices visibles en el 8% de los casos. Todos los pacientes han reflejado una mejoría clínica en la escala de Fligelstone. El diámetro de safena anterior mayor de 7,5 mm y la obesidad se identifican como predictores de un peor resultado clínico y hemodinámico.

**Conclusiones:** La modificación de la estrategia quirúrgica sobre las varices dependientes de la safena anterior presenta un resultado clínico favorable al año de la intervención.

© 2015 AEC. Publicado por Elsevier España, S.L.U. Todos los derechos reservados.

## Introduction

Chronic venous insufficiency (CVI) is a disease with a very high prevalence that requires surgical treatment in most cases. It is one of the most frequently performed scheduled surgeries in Spanish hospitals and has one of the largest waiting lists as well as very elevated healthcare costs.<sup>1,2</sup>

A review of the activity registry of the Spanish Society of Angiology and Vascular Surgery and an analysis of the last five years show how the surgical treatment of varicose veins surpasses 25,000 procedures annually, with a waiting list of some 14,000 patients.<sup>3-7</sup>

Surgical treatment for CVI has two modalities: ablation or destruction therapies (classic saphenectomy, endovenous laser ablation, radiofrequency, venous sclerosis, etc.), and haemodynamic treatments that preserve the saphenous veins like ambulatory conservative haemodynamic correction of venous insufficiency (CHIVA).

The CHIVA strategy has been developed over the past twenty years and is currently the second most frequent surgical method (after saphenectomy) for the surgical treatment of CVI.<sup>8</sup> This treatment is a therapy designed for the needs of each patient according to the haemodynamic condition responsible for the venous insufficiency, while also preserving the saphenous axis. Most other similar publications and studies about this subject have been concerned with the great saphenous vein. Cases about the anterior accessory saphenous vein have been included amongst them, and the documentation about the anterior saphenous vein itself is limited.

The aim of this study is to evaluate the safety and efficacy of a modification of the standard CHIVA procedure in patients that present varicose veins related with the anterior accessory

saphenous vein, without involving the great saphenous vein or the saphenofemoral junction.

## Methods

This prospective study commenced in January 2010 with the inclusion of the first patients who presented with varicose veins of the anterior accessory saphenous vein.

### Selected Patients

Identification of the anterior saphenous vein was done in accordance with the recommendations and consensus guidelines for ultrasound examination and the denomination of the superficial venous system that the International Union of Phlebology published in 2006. According to this consensus, the anterior accessory saphenous vein (AASV) is an ascending venous segment parallel to the great saphenous vein (GSV) in the thigh that is found within its own fascial compartment. There are two ultrasound signs (the “eye sign” and the “alignment sign”) that allow for its identification and differentiation from the GSV.<sup>9</sup>

The ultrasound examination was done with a linear multi-frequency transducer (Esaote Technos, Genoa, Italy) with the patient standing, at which time the saphenofemoral junction, saphenopopliteal junction, deep venous system, saphenous veins and related varicose veins were observed. The Doppler examination allowed us to assess the permeability and competence of the vessels examined, as well as the presence of reflux and the distribution in venovenous shunts. Reflux was defined as a flow that was inverse to the physiological flow for more than 0.5 s. We took measurements of the length and

diameter of the AASV at its midpoint and of the diameter of the GSV 15 cm from its origin. We completed the study with a Reflux Elimination Test (RET) of the AASV, described by Zamboni.<sup>10</sup> The venovenous shunts described for the GSV by the European CHIVA Society at the conference in Teupitz in 2002 were adapted to the AASV region.<sup>11</sup>

The inclusion criteria used were as follows:

- Patients with CVI of the AASV with positive RET and antero-grad GSV.
- Acceptance of surgery and signed informed consent form.

The exclusion criteria were:

- Patients with CVI of the AASV and GSV.
- Patients with deep venous insufficiency.
- Negative RET test in the AASV.
- Patients with limitations to walk normally.
- Patients who refused to give their informed consent.
- Patients with a saphenous diameter >8.5 mm.

A registry of epidemiological data was created, including: sex, age, pregnancies, body mass index, and CEAP classification.

### Surgical Procedure

The modification of the CHIVA strategy consisted of disconnection and removal of the tertiary network from the AASV, interrupting the venovenous shunt and forcing antero-grad

flow through the AASV itself, without operating on the main leak point located at the saphenofemoral junction (Fig. 1). The surgery was conducted as part of the major outpatient surgery programme at our hospital. A strategic incision was made to disconnect the varicose vein network of the AASV and afterwards multiple complementary incisions were made to eliminate the varices. Local anaesthesia was used, with postoperative wrapping and low molecular weight heparin at prophylactic doses (bemiparin 2500-3500 units/day) for 10 days, following known criteria.<sup>8</sup>

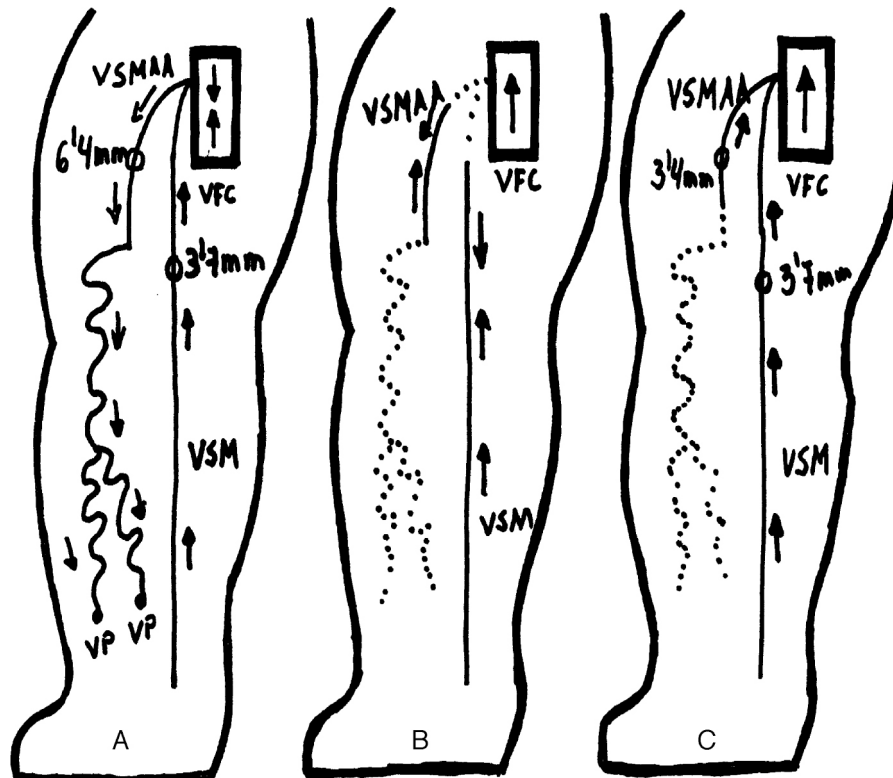
The duration of surgery was variable and basically depended on the phlebectomy done, although it was always less than 90 min.

### Follow-up

The first follow-up visit was one month later, and patients were checked for the presence of clinical and haemodynamic complications (deep vein thromboses or saphenous thromboses) as well as the presence of reflux in the AASV. After one year, ultrasound studies were conducted in the same manner.

Treatment was considered haemodynamically successful when there was a reduction in the diameter of the AASV, which became antero-grad and lost reflux. Treatment was considered a haemodynamic failure when the AASV presented reflux, the GSV had increased in size or presented reflux, or there was thrombosis of the femoral vein.

Twelve months later, the efficacy of the procedure was determined with the assessment of the clinical results by



**Fig. 1** – Patient mapping with varicose tributaries of the saphenous vein: (A) baseline situation of AASV-related varicose veins; (B) CHIVA cure 1 + 2 (traditional), non-haemodynamic approach: crosssection of the saphenofemoral junction and disconnection of the varicose veins from the AASV and extensive phlebectomy; (C) haemodynamic CHIVA cure (innovative procedure): disconnection of the varices from the AASV and extensive phlebectomy.

means of the Fligelstone scale and the absence of recurrences.<sup>12</sup> Patient satisfaction was assessed using a numeric scale from 1 to 10.

### Study Variables and Statistical Analysis

The predictive variables that were contemplated included age, sex, excess weight (BMI >25), reoperation of varices, length of AASV (longer or shorter than 10 cm), diameter of the GSV (75th percentile greater than 7.5 mm) and type of haemodynamic shunt (type 3 or type 5). We have considered variables resulting from haemodynamic success or failure (antegrade flow or reflux), saphenous vein thrombosis and the presence of varicose recurrence, all one year later.

The data were processed statistically with SPSS v21 software. To determine whether there was a relationship between certain variables and the presence of recurrence, saphenous vein thrombosis and haemodynamic failure, the corresponding analyses were completed. For qualitative variables, Fisher's exact test or the chi-squared test were used. For quantitative variables, prior to the analysis normality was checked with the Shapiro-Wilk test. For the variables that followed a normal distribution, Student's test was applied; when this was not verified, the non-parametric Mann-Whitney U test was applied. The multivariate analysis was conducted by means of nominal logistic regression.

## Results

### Demographic Data

The 12-month follow-up was completed by 65 patients, who were predominantly female: 58 women and 7 men. Mean age was 46. A previous internal saphenectomy had been done in 6 (9%) patients. The female subjects had an average of 2 prior pregnancies. Twenty-six (40%) patients were overweight. CEAP distribution was class II in 27 (41%) cases, class III in 20 (31%) and classes IV, V or VI in 18 (28%) cases, with four open ulcers.

### Haemodynamic Results

Data were collected for ultrasound and haemodynamic parameters. The most frequent type of venovenous shunt described in the AASV was type III (50, 77%) followed by type V (14, 22%) and only one case of IIa (1%). The new CHIVA strategy applied in all the cases was haemodynamic. The AASV was less than 10 cm in 33 cases (51%), and greater than 10 cm in the 32 (49%) remaining cases. The mean starting diameter of the AASV was 6.4 mm; after 12 months, this had been reduced to 3.4 mm, with a mean reduction of 3 mm. The GSV diameter was not modified (Table 1). A favourable haemodynamic result was observed in 53 (82%) patients, while reflux persisted in the AASV in 12 (18%) cases (Fig. 2).

### Clinical Results

The application of the Fligelstone scale showed clinical and aesthetic improvement in all patients (Tables 2 and 3).

**Table 1 – Results of the Variation in Diameters of the Internal and Anterior Saphenous Veins One Year After Surgery.**

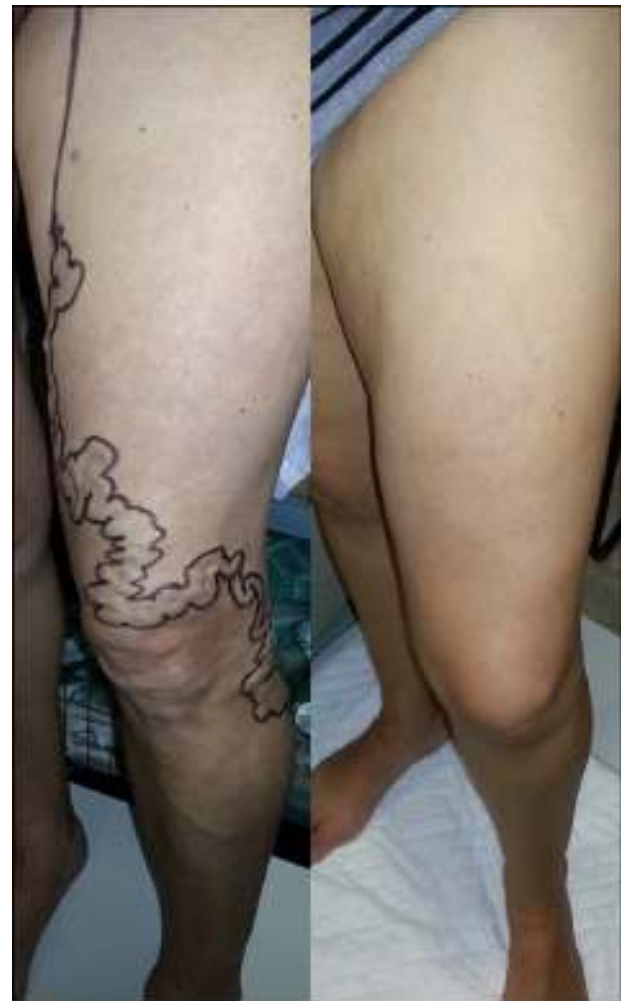	Evolution of saphenous diameters (mm)		
	Initial	12 months	P
AASV diameter	6.49±1.2	3.41±1.1	<.001
GSV diameter	3.73±0.6	3.70±0.6	.258

A search for clinical recurrence revealed 5 (8%) cases of recurrent varices larger than 5 mm.

Overall patient assessment of the treatment defined by the numerical scale showed that none of the patients gave our performance poor marks. Their evaluations were predominantly positive, with an excellent average score of 9.4.

### Complications

Three (5%) haematomas were detected, none of which required surgical treatment. There were no deaths, hospitalisations, deep venous or symptomatic superficial thromboses, infections or episodes of neuritis. Early ultrasound tests detected 7 (11%)



**Fig. 2 – One-year results after surgery: image showing varicose tributaries of the AASV; the left image shows the preoperative mapping, and situation 12 months after surgery is on the right.**

**Table 2 – Symptomatic and Aesthetic Assessment 12 Months After Surgery of the 65 Patients in Follow-up.**

<i>Patient assessment of symptoms (Fligelstone scale)</i>	
1. - Asymptomatic, no discomfort	37 (57%)
2. - Quite improved, but occasional mild discomfort	26 (40%)
3. - Improved, but with frequent mild symptoms	2 (3%)
4. - Same: no improvement; same symptoms as before	0
5. - Worse: symptoms have worsened	0
<i>Patient assessment of aesthetics (Fligelstone score)</i>	
1. - Excellent	27 (42%)
2. - Very good: very satisfied with the results	29 (46%)
3. - Good: satisfied with the results	9 (14%)
4. - Same: poor result; the improvement was not important	0
5. - Worse: aesthetic improvement has been minimal	0
<i>Aesthetic assessment by an independent observer (Fligelstone score)</i>	
1. - No visible varicosities	52 (80%)
2. - Superficial varicosities <5 mm	8 (12%)
3. - Superficial varicosities >5 mm on the thigh or calf	4 (6%)
4. - Superficial varicosities >5 mm on the thigh and calf	1 (2%)
5. - Varicose vein complications: eczema, ulcers	0

**Table 3 – Clinical Results After 12 Months.**

<i>Recurrent varices &gt;5 mm</i>	
No new varices	60 (92%)
Appearance of new varices	5 (8%)
<i>Haemodynamic results</i>	
Normal anterograde flow	53 (82%)
Persistent retrograde flow	12 (18%)
<i>Clinical results (Fligelstone score)</i>	
Improved (CEAP 1,2,3)	65 (100%)
Worsened (CEAP 4,5)	0 (0%)

partial thromboses of the AASV, although no patients reported spontaneous symptoms requiring emergency room attention.

### Analysis of the Results

The statistical analysis used to determine whether there was a correlation between the variables and the presence of clinical recurrence, saphenous thrombosis and the haemodynamic results showed no statistically significant association with sex, prior intervention, length of the AASV or shunt type. In contrast, the initial diameter of the AASV >7.5 mm and excess weight were statistically significant as factors associated with a poor haemodynamic result, without showing significance for clinical recurrence (Table 4).

### Discussion

The AASV is responsible for 11% of the varices of the extremities, 10%–43% of recurrent varicose veins and poorer results after treatment, according to some authors.<sup>13–17</sup>

The classic treatment for varicose veins originating in the groin with distribution in the region of the anterior saphenous vein involves standard crosssectomy of the saphenofemoral junction, with ligation and disconnection of all the tributaries, including the AASV and GSV, as well as internal saphenectomy, to reduce the number of recurrences. In the last decade, several authors have treated the AASV exclusively, without removing or operating on the healthy GSV. In a study from 2001, Prinz recommended that, in cases of AASV-related varices with a competent GSV, standard crosssectomy should be done of the saphenofemoral junction with removal of the initial cm of the AASV as well as the GSV, plus complementary phlebectomy, while leaving intact the rest of the GSV.<sup>18</sup> In 2011, Theivacumar used a treatment with endovenous laser in patients with AASV varicose veins with a minimal length of 10 cm and a diameter of 3 mm, without affecting the GSV, with good results.<sup>19</sup>

Careful haemodynamic mapping of the AASV varices allowed us to design this treatment in which we disconnect the venovenous shunt and eliminate the varicose network, without the need to operate in the groin with closure of the saphenofemoral junction, thus respecting the GSV. Crosssectomy is avoided and the GSV is preserved for future material in case revascularisation bypass were ever needed.

In our series, the GSV was not modified by our actions and was maintained anterograde in all cases. Meanwhile, the AASV remained with anterograde flow in 82% of the cases. Currently, there are no studies about haemodynamic surgery that have described this type of treatment in AASV-related varices.

In our approach, we have assumed the treatment proposed for the GSV by Zamboni more than a decade ago, which support performing haemodynamic surgery in patients with a positive RET test in the GSV after the interruption of the venovenous shunt by compression of the R3. In the first series from 2001, the patients who were treated in this manner presented a GSV with anterograde flow in 85% of cases after 6 months. The second series presented a three-year follow-up with anterograde saphenous vein flow of 18% in the cases that presented incompetence of the ostial valve and 86% in those with competent ostial valves. In 2003, Escribano presented six-month results for anterograde flow of only 12%.<sup>10,20,21</sup>

Saphenous vein thrombosis was one of the complications that we feared. We used low-molecular-weight heparin for one month to minimise this risk. One month later, 7 partial AASV thromboses were detected, although they were asymptomatic and did not persist after one year. The clinical complications presented were local haematomas, which resolved spontaneously with no problems. These results coincide with the study about CHIVA surgery complications published by our group some years ago, and they provide evidence about the safety of this therapeutic modality.<sup>8</sup>

The clinical results have been favourable in all cases, including patients that have presented recurrence, with very high patient satisfaction. We have not found statistically significant associations between most variables and the presence of recurrence, saphenous vein thrombosis or haemodynamic failure. We have found, however, that excess weight and AASV diameter >7.5 mm are associated with

**Table 4 – Analysis of Factors Related With the Results of Recurrence and Poor Haemodynamic Results After 12 Months.**

Factor	Recurrence			Poor HD results		
	%	Univar	Multivar	%	Univar	Multivar
Female sex	8.6	0.55	0.26	19	0.61	0.821
Overweight	15	0.07	0.218	34	0.009	0.044
Reoperation	40	0.04	0.121	60	0.04	0.178
AASV length >10 cm	6	0.51	0.339	25	0.15	0.38
Shunt 3/shunt 5	10-0	0.03	0.23	24-0	0.263	0.067
Initial diameter AASV >7.5 mm	21	0.23	0.04	37	0.030	0.02

This table shows the different factors that have been studied with regards to recurrence variables after 12 months and poor haemodynamic results (according to the criteria established in Table 3). The percentages represent the presence of each factor. The univariate analysis was done with the chi squared or Fisher text, and the P reached for each test is shown. For the multivariate analysis, a nominal logistic regression model was followed, and P values are also included.

AASV: anterior accessory saphenous vein.

HD: haemodynamic.

poorer haemodynamic results. In these cases and in the future, we would consider other therapeutic options.

The limitations of our study include the small number of cases and a follow-up period that is still short. It is useful to observe that the potential thrombosis of the AASV with extension to the saphenofemoral junction and the common femoral vein, which could be associated with this treatment variation for AASV-related varicose veins, did not occur. Nor did we observe a high number of recurrences. Furthermore, the percentage of complications was low and patient satisfaction high.

It is possible that this technique is not the technique of choice for patients with an anterior saphenous vein larger than 7.5 mm or in very obese patients.

This new haemodynamic treatment method for AASV varicose veins presents successful haemodynamic and clinical results 12 months later, with high patient satisfaction. It is safe, and complications are local and benign. It enables us to correct AASV-related varices without having to operate on the saphenofemoral junction or the GSV, which continues to function correctly and is potentially useable for revascularisation surgery.

## Funding

No institutional funding was received for the elaboration of this study.

## Authorship/Collaborators

NMF: design, data collection, analysis, writing, critical review and approval.

JPLP: design, analysis, writing, critical review and approval.

CLE: analysis, writing, critical review and approval.

FJMG: design, data collection and approval.

ERD: writing critical review and approval.

## Conflict of Interests

The authors declare having no conflict of interests.

## REFERENCES

- Bellmunt S, Miquel C, Reina L, Lozano F. La insuficiencia venosa crónica en el Sistema Nacional de Salud. Diagnóstico, indicaciones quirúrgicas y priorización de listas de espera. Documento de la Sociedad Española de Angiología y Cirugía Vascular (SEACV) y del Capítulo de Flebología y Linfología de la SEACV. *Angiología*. 2013;65:61-71.
- Escudero Rodríguez JR, Fernández Quesada F, Bellmunt Montoya S. Prevalencia y características de la enfermedad venosa crónica en pacientes atendidos en atención primaria en España: resultados del estudio internacional Vein Consult Program. *Cir Esp*. 2014;92:539-46.
- Morales-Cuenca G, Moreno-Egea A, Aguayo-Albasini JL. Los cirujanos generales frente a la cirugía de las varices. *Cir Esp*. 2009;85:205-13.
- Moreno-Carriles RM, Dolores-Aguilar AM. Registro de Actividad de la Sociedad Española de Angiología y Cirugía Vascular, año 2008. *Angiología*. 2009;61:325-48.
- Moreno-Carriles R. Registro de actividades de la Sociedad Española de Angiología y Cirugía Vascular, año 2009. *Angiología*. 2010;62:183-99.
- Moreno-Carriles RM. Registro de actividades de la Sociedad Española de Angiología y Cirugía Vascular, año 2010. *Angiología*. 2012;64:13-30.
- Moreno-Carriles RM. Registro de actividades de la Sociedad Española de Angiología y Cirugía Vascular, año 2011. *Angiología*. 2013;65:16-33.
- Maldonado-Fernández N, López-Espada C, Martínez-Gómez FJ, Mata-Campos JE, Galán-Zafra M, Sánchez-Maestre ML. Complicaciones postoperatorias de la estrategia CHIVA para el tratamiento de la insuficiencia venosa crónica. *Angiología*. 2010;62:91-6.
- Cavezzi A, Labropoulos N, Partsch H, Ricci S, Caggiati A, Myers K, et al. Duplex ultrasound investigation of the veins in chronic venous disease of the lower limbs. IIP Consensus Document. Part II. Anatomy. *Eur J Vasc Endovasc Surg*. 2006;31:288-99.
- Zamboni P, Cisno C, Marchetti F, Quaglio D, Mazza P, Liboni A. Reflux elimination without any ablation or disconnection of the saphenous vein. A haemodynamic model for venous surgery. *Eur J Vasc Endovasc Surg*. 2001;21:361-9.
- Juan-Samsó J, Escribano-Ferrer JM, Rodríguez-Mori A, Bofill-Brossa M, Matas-Docampo M. Cirugía hemodinámica venosa en el tratamiento del síndrome varicoso. *Angiología*. 2003;55:460-75.

12. Fligelstone L, Carolan G, Pugh N, Minsk P, Shandall A, Lane I. An assessment of the long saphenous vein for potential use as a vascular conduit after varicose vein surgery. *J Vasc Surg.* 1993;18:836-40.
13. García-Gimeno M, Rodríguez-Camarero S, Tagarro-Villalba S, Ramalle-Gomara E, Ajona JA, González-González E, et al. Duplex mapping of 2036 primary varicose veins. *J Vasc Surg.* 2009;49:681-9.
14. Theivacumar NS, Gough MJ. Endovenous Laser Ablation (EVLA) to treat recurrent varicose veins. *Eur J Vasc Endovasc Surg.* 2011;41:691-6.
15. Juan-Samsó J. La recidiva varicosa: un problema de diagnóstico o de tratamiento. *Angiología.* 2005;(Supl 1):S75-83.
16. Garner JP, Heppell PSJ, Leopold PW. The lateral accessory saphenous vein – a common cause of recurrent varicose veins. *Ann R Coll Surg Engl.* 2003;85:389-92.
17. Chaar CI, Hirsch SA, Cwenar MT, Rhee RY, Chaer RA, Abu Hamad G, et al. Expanding the role of endovenous laser therapy: results in large diameter saphenous, small saphenous, and anterior accessory veins. *Ann Vasc Surg.* 2011;25:656-61.
18. Theivacumar NS, Darwood RJ, Gough MJ. Endovenous laser ablation of the anterior accessory great saphenous vein: abolition of sapheno-femoral reflux with preservation of the great saphenous vein. *Eur J Vasc Endovasc Surg.* 2009;37:477-81.
19. Zamboni P, Giancesini S, Menegatti E, Tacconi G, Palazzo A, Liboni A. Great saphenous varicose vein surgery without sapheno-femoral junction disconnection. *Br J Surg.* 2010;97:820-5.
20. Escribano JM, Juan J, Bofill R, Maesso J, Rodríguez-Mori A, Matas M. Durability of reflux-elimination by a minimal invasive CHIVA procedure on patients with varicose veins. A 3 year prospective case study. *Eur J Vasc Endovasc Surg.* 2003;25:159-63.
21. Juan J, Escribano JM, Criado E, Fontcuberta J. Haemodynamic surgery for varicose veins: surgical strategy. *Phlebology.* 2005;20:2-13.