

Primary Retroperitoneal Mucinous Cystadenoma[☆]



Cistoadenoma mucinoso retroperitoneal primario

Primary retroperitoneal mucinous cystadenomas are defined as cystic epithelial neoplasms composed of cells that contain intracytoplasmic mucin. When these masses are associated with an invasive carcinoma, they are known as cystadenocarcinoma. These tumors share many histological similarities with other neoplasms with the same name located in the ovaries, pancreas or bile duct, although their localization in the retroperitoneal region is extremely rare.

We present the case of a 20-year-old woman, with no prior medical history of interest, who was asymptomatic and reported the sensation of having an abdominal mass.

Physical examination revealed a large non-painful mass in the right flank with an apparently uniform surface. Pregnancy test and tumor markers were negative. Computed tomography demonstrated a large subhepatic right retroperitoneal mass measuring 16 cm×12 cm×6 cm that was cystic, unilocular and showed homogeneous density (Fig. 1). During exploratory laparotomy, the only finding was this cystic-appearing retroperitoneal mass, which was resected in its entirety without incident (Fig. 2A and B).

The pathology study reported the presence of ovarian-like stroma in the mass, and its inner surface was covered by a mucinous epithelium of a row of cells, findings that led to the diagnosis of a primary retroperitoneal mucinous cystadenoma. As the mass was extracted “en bloc” and the pathology study ruled out malignancy, the patient received no other treatment.

A search of the scientific literature on PubMed and MEDLINE found 30 similar cases published,¹⁻⁴ only two of which were males.^{5,6} Interestingly, the number of cases published with retroperitoneal cystadenocarcinoma was almost double, with the same proportion of cases in men (only 5 cases).⁷ These data clearly show the malignant progression of these tumors.

These tumors usually grow rapidly and can become large in size, even surpassing 20 cm in diameter in some cases. This growth leads to their diagnosis based on compressive abdominal symptoms and the displacement of intraabdominal organs^{1,2}; in most cases, however, the presentation of the abdominal mass is asymptomatic.

As for the origin of these tumors, several theories have been proposed, although 2 receive the most support. One of them suggests that they originate from heterotopic ovarian tissue or remnants of the urogenital apparatus, since they present a stroma similar to ovarian stroma with

estrogen receptors and mainly affect women; although this theory would not explain the cases found in males. Another theory proposes that they arise from the invagination of cells from the mesothelial layers, and that these cells undergo mucinous metaplasia.^{3,4}

It is important to establish the differential diagnosis with other retroperitoneal masses, such as cystic teratoma, cystic lymphangioma, renal cyst and cystic neoplasia of the pancreas or ovaries^{3,5}; therefore it is essential to establish the absence of dependence on other retroperitoneal organs. Given its availability, the main diagnostic tool is computed tomography, which enables us to observe the cystic nature of the mass and whether there are radiological findings suggestive of malignancy, such as the existence of a solid pole or septations.⁵

After the clinical and radiological findings, and given the malignant potential of these masses, immediate surgery is important since invasive diagnostic methods like fine needle aspiration are not sensitive enough to rule out malignancy, and tumor markers are normal in most cases.^{2,8}

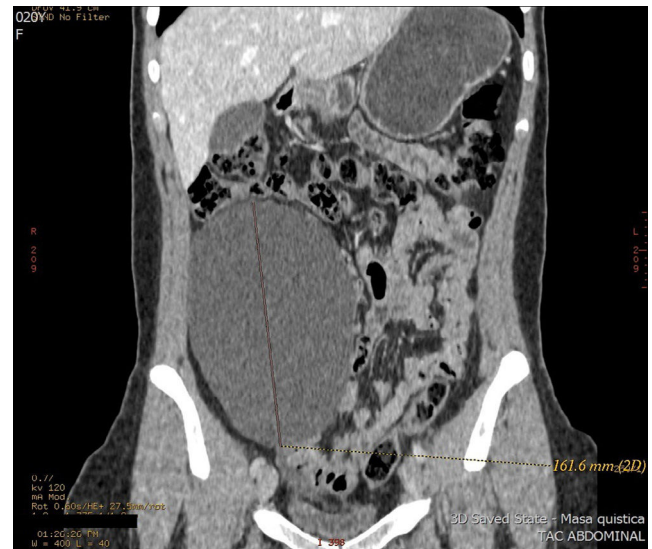

Fig. 1 – Computed tomography scan showing the retroperitoneal cystic mass in the right anterior renal region measuring 16 cm×12 cm×6 cm, with homogenous density.

[☆] Please cite this article as: Zevallos Quiroz JC, Toran Monserrat FJ, de Santiago Urquijo FJ, Cormenzana Lizarribar EP, Arrinda Yeregui JM. Cistoadenoma mucinoso retroperitoneal primario. Cir Esp. 2016;94:365-366.

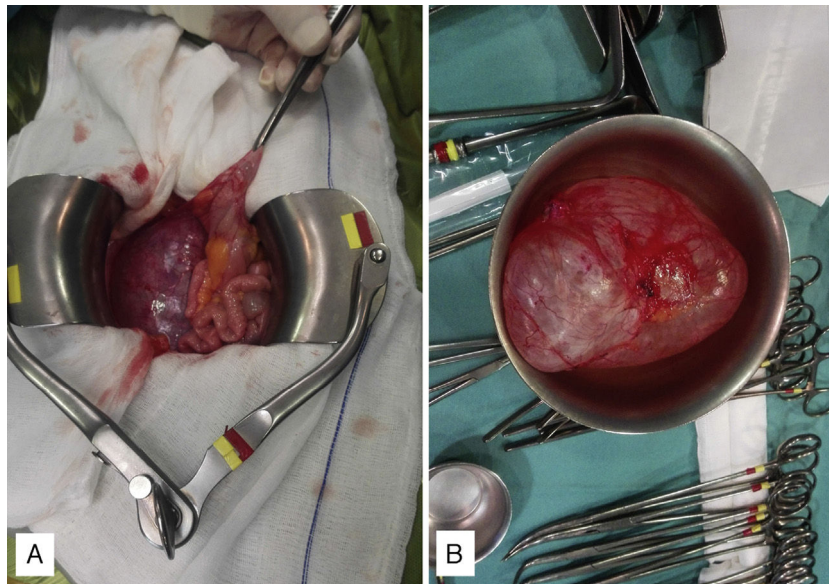


Fig. 2 – (A) Intraoperative image of the mass: note the medial displacement of the colon (held with forceps) and the small bowel and (B) whole surgical specimen, which is cystic in consistency.

REFERENCES

1. Yan SL, Lin H, Kuo CL, Wu HS, Huang MH, Lee YT. Primary retroperitoneal mucinous cystadenoma: report of a case and review of the literature. *World J Gastroenterol.* 2008;14:5769-72.
2. Navin P, Meshkat B, McHugh S, Beegan C, Leen E, Prins H, et al. Primary retroperitoneal mucinous cystadenoma. A case study and review of the literature. *Int J Surg Case Rep.* 2012;3:486-8.
3. Santo-Filho MA, Colleoni R, Shigueoka DC, Artigiani R, Scalabrini M, de Jesus Lopes-Filho G. Primary retroperitoneal mucinous cystadenoma – case report. *Arq Bras Cir Dig.* 2014;27:224-6 [Article in English, Portuguese].
4. Tapper EB, Shrewsbury AB, Oprea G, Majmudar B. A unique benign mucinous cystadenoma of the retroperitoneum: a case report and review of the literature. *Arch Gynecol Obstet.* 2010;281:167-9.
5. Prabhuraj AR, Basu A, Sistla SC, Jagdish S, Jayanthi S. Primary retroperitoneal mucinous cystadenoma in a man. *Am J Clin Oncol.* 2008;31:519-20.
6. Fujita N, Nishie A, Asayama Y, Kiyoshima K, Kubo Y, Honda H. A male case of primary retroperitoneal mucinous cystadenoma: a diagnostic dilemma. *Jpn J Radiol.* 2012;30:594-7.
7. Feng J, Liu H, Chen D. Primary retroperitoneal mucinous cystadenocarcinoma in a male patient: a rare case report. *Hippokratia.* 2013;17:271-3.
8. Moral González M, García-Blanch de Benito G, Sánchez Gil A, Díaz García GA, Cuberes Monserrat R. Primary retroperitoneal mucinous cystadenocarcinoma. *Cir Esp.* 2008;84:169-71.

Julio César Zevallos Quiroz^{a,*},
Francisco Javier Toran Monserrat^a,
Fernando Jesús de Santiago Urquijo^a,
Enrique Pedro Cormenzana Lizarribar^a,
José María Arrinda Yeregui^b

^aServicio de Cirugía General, Hospital Bidasoa, Hondarribia, Guipúzcoa, Spain

^bServicio de Anatomía Patológica, Hospital Bidasoa, Hondarribia, Guipúzcoa, Spain

*Corresponding author.

E-mail address: juliozeva@hotmail.com (J.C. Zevallos Quiroz).

2173-5077/

© 2014 AEC. Published by Elsevier España, S.L.U. All rights reserved.