



Scientific Letters

Aggressive Angiomyxoma. A Rare Mesenchymal Pelvic Tumor[☆]



Angiomixoma agresivo. Un raro tumor mesenquimal pélvico

Aggressive angiomyxomas are mesenchymal tumors that are extremely rare in men. They most frequently affect adult women of reproductive age, and the female:male ratio is 7:1. Although they are usually benign tumors and distant metastasis is rare, there is a high rate of local recurrence. Described for the first time in 1986 by Steeper and Rosai, they originate in the soft tissue of the pelvic, perineal, vulvar or gluteal regions. In men, reported cases have been located in the groin, scrotum, and spermatic cord.¹ Their name is related with the presence of spindle and stellate cells seen in histology studies, along with blood vessels of varying sizes in a myxoid matrix.² There have been approximately 150 cases reported in premenopausal women and 43 cases in males; 70 of these were located in the pelvic and/or retroperitoneal regions.^{3,4} The clinical diagnosis is almost always difficult due to the lack of specific signs and symptoms.

In this present communication, we provide 4 new cases treated at Hospital de la Santa Creu i Sant Pau between 2011 and 2015: one male and 3 females, aged 40–65 (mean: 48 years) (Table 1). Their symptoms were nonspecific and related with compression and pelvic organ displacement (bladder, rectum, uterus, etc.), including 2 cases of dysuria, one case of rectal tenesmus and one case of pelvic pain. In the case of the male,

physical exploration detected a right perineal mass that, on rectal examination, protruded laterally to the lumen of the rectum. In another case, the protrusion of the tumor appeared on the right labia majora of the patient's genitals. Radiologically, a retroperitoneal pelvic mass was seen with well-outlined edges, causing displacement of the pelvic organs and extension toward the ischiorectal fossa in the case of the male and toward the vulvar region in one woman. All patients were treated surgically with radical resection. The approach was abdominal in 3 patients and abdominoperineal in the case of the patient with vulvar extension, with mobilization to the plane of the levator ani and dissection of the mass from the adjacent planes to allow for specimen extraction. Care was taken to maintain adequate margins, and there was no tumor recurrence in any of the cases.

Macroscopically, the tumors were 4–26 cm in size and had a soft, elastic consistency. The histopathologic aspect of all the lesions was fibromyxoid, with blood vessels of varying sizes and no areas of necrosis or hemorrhage, except for the male patient, where areas of superficial bleeding were observed (Fig. 1A). From an immunohistochemistry standpoint, there was positivity for desmin as well as estrogen receptors (Fig. 1B and C). During the current follow-up, none of the patients have presented tumor recurrence.

Table 1 – Anatomic and Clinical Data of Patients Treated for Aggressive Angiomyxoma.

Case No.	Sex	Age (years)	Reason for consultation	Tumor size	Surgery	Necrosis/Hemorrhage	Tumor recurrence
1	Male	65	Rectal tenesmus, dysuria, sensation of perineal weight	26 cm	Laparotomy	Yes	No
2	Female	41	Vulvar lesion, dysuria	6 cm	Laparotomy	No	No
3	Female	44	Vulvar nodule and pelvic pain	12 cm	Perineal	No	No
4	Female	40	Gynecological follow-up, pelvic pain	4 cm	Laparotomy	No	No

[☆] Please cite this article as: Artigas Raventós V, Rivero Cruces D, González López J, Rodríguez Blanco M, Bogaña I. Angiomixoma agresivo. Un raro tumor mesenquimal pélvico. Cir Esp. 2016;94:359-361.

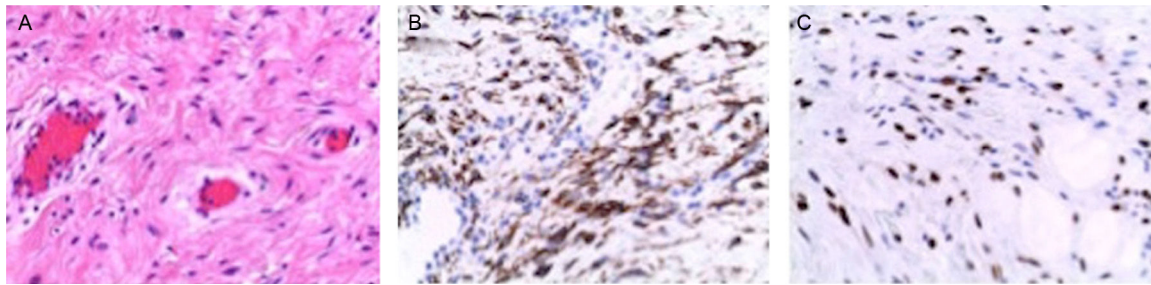


Fig. 1 – (A) Aggressive angiomyxoma (HE 200×): tumor cells with uniform oval nuclei without atypia, in an edematous stroma with collagen fibers and numerous dilated vessels; (B) Positive immunohistochemistry of the cells for desmin; (C) Positive immunohistochemistry of the cells for estrogen receptors.

CT images can be variable and often show a homogenous and hypodense mass compared to the muscle, and with slight intravenous contrast uptake. On MRI, their characteristics include an iso- or hypointense mass compared with the muscle in the enhanced images in T1 and hyperintense in T2 sequences, related with abundant myxoid matrix and high water content. They present notable enhancement in post-gadolinium sequences, with typical spiral-shaped uptake pattern and bands of different intensity inside caused by the fibrovascular stroma of the tumor.^{5,6}

On histopathology, aggressive angiomyxomas are pseudo-papillary in appearance. The surrounding myxoid tissue appears in places containing a proliferation of dense collagen. Generally, the tumor cells do not show cytonuclear atypia.^{7,8} A study by Rotmensch et al. demonstrated how aggressive angiomyxomas can be positive for estrogen and progesterone receptors and consequently be treated with hormone therapy.⁹

Surgical treatment is based on extensive surgery of the tumor while maintaining free margins, as this usually guarantees a cure with few functional consequences.⁵ Nonetheless, their infiltrating nature makes complete exeresis difficult, which occurred in our male patient. This is especially true when the location is pelvic and in contact with the rectum and/or bladder and reaches the ischioanal space. In these cases, complete excision is more complex (either R1 or R2) and there is a greater risk of recurrence.

The success of radiotherapy and/or chemotherapy (especially given tumor recurrence) is low due to the existence of a large quantity of collagen in this type of tumors, associated with a low rate of mitotic activity and low cellularity.¹⁰

In conclusion, we can say that aggressive angiomyxomas are rare mesenchymal tumors that are benign in nature. They are more frequent in premenopausal women than in men and have a tendency toward local recurrence after their complete removal. There is no chemotherapy and/or radiotherapy that could improve the prognosis or could avoid or reduce the recurrence rate. It is therefore important to understand that the surgical exeresis of this tumor should be as complete and radical as possible.

Conflict of Interest

The authors have no conflict of interests to declare.

REFERENCES

- Morag R, Fridman E, Mor Y. Aggressive angiomyxoma of the scrotum mimicking huge hydrocele: case report and literature review. *Case Rep Med.* 2009;157624. 2009.
- Andrés LA, Mishra MJ. Angiomyxoma diagnosed in a man presenting for abdominal lipectomy. *Can J Plast Surg.* 2007;15:163-4.
- Idrees MT, Hoch BL, Wang BY, Unger PD. Aggressive angiomyxoma of male genital region. Report of 4 cases with immunohistochemical evaluation including hormone receptor status. *Ann Diagn Pathol.* 2006;10:197-204.
- Adwan H, Patel B, Kamel D, Glazer G. A solitary encapsulated pelvic aggressive angiomyxoma. *Ann R Coll Surg Engl.* 2004;86:W1-3.
- Lachkhem A, Mardassi A, Gamra S, Ouertani B, Kochbati H, Elmay L. Angiomyxome agressif de la joue: A propos d'une observation. *J Tun ORL.* 2008;20:59-61.
- Outwaker EK, Marcetto BE, Wagner BJ, Siegelman ES. Aggressive angiomyxoma: findings on CT and MR imaging. *AJR Am J Roentgenol.* 1999;172:435-8.
- Fletcher CD, Tsang WY, Fisher C, Lee KC, Chan JK. Angiomyofibroblastoma of the vulva: a benign neoplasm distinct from aggressive angiomyxoma. *Am J Surg Pathol.* 1992;16:373-82.
- Yamashita Y, Tokunaga O, Goto M. Aggressive angiomyxoma of the oral floor: report of a case. *J Oral Maxillofac Surg.* 2004;62:1429-31.
- Rotmensch EJ, Kasznica J, Hamid MA. Immunohistochemical analysis of hormone receptors and proliferating cell nuclear antigen in aggressive angiomyxoma of the vulva. *Int Gynecol Obstet.* 1993;41:171-219.
- McCluggage WG, Connolly L, McBride HA. HMGA2 is a sensitive but not specific immunohistochemical marker of vulvovaginal aggressive angiomyxoma. *Am J Surg Pathol.* 2010;34:1037-42.

Vicente Artigas Raventós^{a,*}, Diego Rivero Cruces^a,
José González López^a, Manuel Rodríguez Blanco^a,
Isidre Boguñá^b

^aUnidad de Cirugía HBP-Oncológica, Servicio de Cirugía General
y Digestiva, Hospital Santa Creu i Sant Pau, Universidad Autónoma
de Barcelona, Barcelona, Spain

^bUnidad de Cirugía Onco-Ginecológica, Hospital Santa Creu i Sant
Pau, Universidad Autónoma de Barcelona, Barcelona, Spain

*Corresponding author.

E-mail address: vartigas@santpau.cat (V. Artigas Raventós).

2173-5077/

© 2016 AEC. Published by Elsevier España, S.L.U. All rights
reserved.

Radioguided Intraoperative Detection of Ectopic Adrenocorticotrophic Hormone-Producing Carcinoid Tumor[☆]



DetECCIÓN INTRAOPERATORIA RADIOGUIADA DE TUMOR CARCINOIDE PRODUCTOR DE HORMONA ADRENOCORTICOTROPA ECTÓPICA

Carcinoid tumors are malignant neuroendocrine neoplasms that originate in the enterochromaffin cells of the diffuse endocrine system (APUD). The location of about 10% of these tumors is bronchopulmonary, and 1%–2% may be associated with paraneoplastic syndromes like Cushing's syndrome.¹

SRI (¹¹¹In-octreotide) may be indicated for the detection of disseminated carcinoid tumors or millimetric functioning tumors that are difficult to locate with other imaging studies.^{2,3} There are anecdotal reports of its use in the literature, and in our case it was essential for the complete resection of the lesions.⁴

The patient is a 30-year-old male with no medical history of interest who presented symptoms of Cushing's syndrome. Lab analyses showed evidence of hyperglycemia (300 mg/dL with negative ketonuria), elevated glycosylated hemoglobin (6.3%), mild hypokalemia, hypercholesterolemia, and hypercortisolism (3978 µg/day). Treatment was initiated with insulin. Levels of 5-hydroxyindoleacetic acid and chromogranin A were 8.5 mg/24 h and 225 ng/mL, respectively, suggesting carcinoid tumor. The episodic secretions of adrenocorticotrophic hormone (ACTH) were 153 µg and 83.3 µg after 8 and 23 h, respectively, which guided the diagnosis toward an extra-adrenal ACTH-dependent etiology. The absence of dexamethasone suppression and the normal results of a hypophyseal magnetic resonance imaging study led to a diagnosis of ectopic ACTH secretion syndrome.

Thoracoabdominal computed tomography (CT) scan revealed no pathologic findings, but the SRI showed a millimetric pathologic uptake in the right lung hilum (Fig. 1), although no endobronchial lesions were observed on bronchoscopy.

Twenty-four hours after the injection of the radioactive tracer (octreotide), we conducted an exploratory thoracotomy with manual palpation of the lung and scintigraphy scan

using an intraoperative catheter (Fig. 2). In addition to the small quantity of serous pleural fluid, a peripheral nodule measuring 6 mm was found in the RLL along with an interlobar lymph node (both with hyperuptake and value of 34 and 37 over the "pulmonary pool" of 2). Atypical pulmonary resection was performed with systematic mediastinal lymphadenectomy and intraoperative pathology confirmation of the lesions.

The immunohistochemistry study revealed a type 1 neuroendocrine carcinoma. Interlobar lymphadenopathy and the cytology of the pleural liquid were positive for malignancy, corresponding with stage IVa (T1N1M1). No adjuvant therapy was administered. The Cushing's syndrome was resolved after the surgery, and after 5 years of follow-up the patient remains asymptomatic, with no signs of relapse.

15%–20% of cases with Cushing's syndrome can be caused by non-hypophyseal tumors comprised by neuroendocrine tissue.¹ Bronchial carcinoid tumors are the most common cause of ectopic ACTH secretion (25%).¹

In our case, once the hypercortisolism had been confirmed, the differential diagnosis was initiated with Cushing's disease and ectopic Cushing's. After having confirmed the ectopic origin, a thoracoabdominal CT scan showed no lesions.

As reported by certain authors, a considerable number of bronchial carcinoid tumors are undetectable by conventional imaging techniques due to their small size and/or location in the pulmonary hilum, where they are particularly difficult to differentiate from the normal vasculature.² A review by Özkan et al. assessing SRI mentions a series of 90 cases, in which 47% were secondary to intrathoracic tumors and in 19% of cases the lesion was not located.³ More recent publications report the localization of hypersecretory tumors in only 62.5% of

[☆] Please cite this article as: Rombolá CA, Genovés-Crespo M, López-Jiménez L, Martín-Ordoñez F, León-Atance P. Detección intraoperatoria radioguiada de tumor carcinoide productor de hormona adrenocorticotropa ectópica. Cir Esp. 2016;94:361–362.