



## Image of the Month

Giant Retroperitoneal Liposarcoma: The Silent Tumour<sup>☆</sup>

## Liposarcoma retroperitoneal gigante: el tumor silencioso

Jorge Galván Fernández,<sup>a,\*</sup> María Isabel Jiménez Cuenca,<sup>a</sup> Susana González Fuentes,<sup>a</sup> Fernanda Benavides de la Rosa<sup>b</sup>

<sup>a</sup> Servicio de Radiodiagnóstico, Hospital Clínico Universitario de Valladolid, Valladolid, Spain

<sup>b</sup> Servicio de Cirugía General y del Aparato Digestivo, Hospital Clínico Universitario de Valladolid, Valladolid, Spain

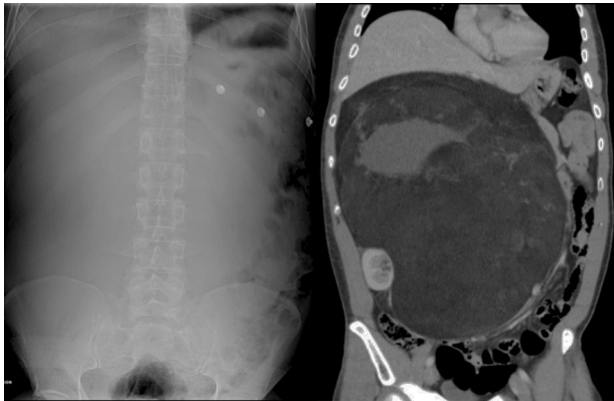


Fig. 1

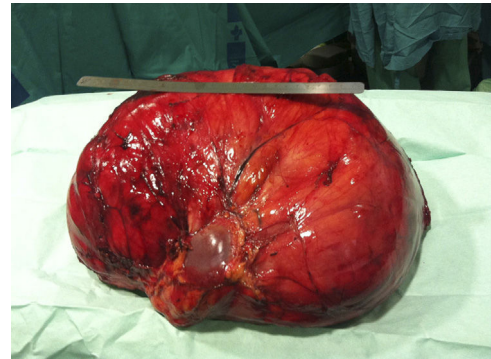


Fig. 2

The patient is a 46-year-old male who came to our Emergency Department due to progressive increase in abdominal perimeter associated with diffuse abdominal pain. On examination, a non-painful abdominal mass was palpated, which extended from the upper hemiabdomen to the pelvis. Abdominal radiography and abdominal computed tomography identified a well-outlined mass measuring 33 cm×15 cm×27 cm that occupied practically the entire abdomen and displaced structures. The mass had fatty density and solid uptake areas (Fig. 1). We performed radical resection of the tumour (9.75 kg), including right nephrectomy through a midline laparotomy (Fig. 2). Retroperitoneal liposarcomas grow silently and rarely develop metastasis. It is not easy to achieve complete resection of the tumour, and recurrences are frequent. Diagnosis: giant retroperitoneal liposarcoma.

<sup>☆</sup> Please cite this article as: Galván Fernández J, Jiménez Cuenca MI, González Fuentes S, Benavides de la Rosa F. Liposarcoma retroperitoneal gigante: el tumor silencioso. Cir Esp. 2016;94:411.

\* Corresponding author.

E-mail address: [jgfgalvan@gmail.com](mailto:jgfgalvan@gmail.com) (J. Galván Fernández).