



Image of the month

An Unusual Presentation of a Mucinous Cystadenoma of the Appendix[☆]



Cistoadenoma mucinoso apendicular con presentación inusual

Maria D. Balsalobre Salmeron,^{*} Arancha García López, Nuria M. Torregrosa Perez, Jose Luis Vazquez Rojas

Servicio de Cirugía General, Hospital Universitario Santa Lucía, Cartagena, Murcia, Spain

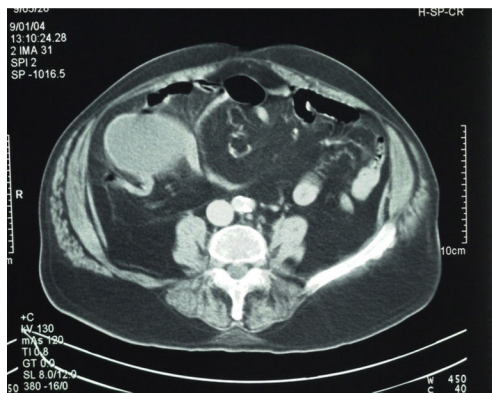


Figure 1

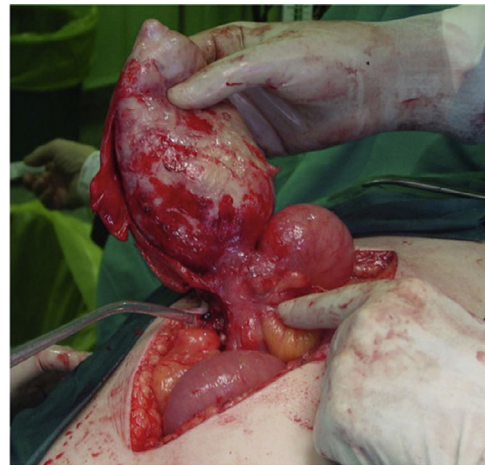

Figure 2

Mucinous cystadenoma of the appendix is a rare disease (0.2%–0.6% of appendectomies) that presents with variable clinical symptoms.

We present the case of a 76-year-old male, with no prior surgical history, who reported abdominal pain and constipation. Physical examination demonstrated pain in the right iliac fossa, with guarding and the detection of a mass. Abdominal radiograph was compatible with symptoms of small bowel obstruction. Ultrasound and computed tomography revealed a structure measuring 20 cm in diameter that was cystic and adhered to the cecum, causing obstruction at the ileocecal valve by extrinsic compression (Fig. 1). Laparotomy discovered a mass measuring 20 cm × 8 cm dependent on the appendix (Fig. 2). Because of the suspicion of appendiceal mucocele and due to the size of the mass, appendectomy and *en bloc* ileocecal resection were performed. The pathology results reported the presence of areas of adenomatous glandular tissue with hyperplastic mucosa, compatible with mucinous cystadenoma. Three years after surgery, the patient continues to be disease free.

[☆] Please cite this article as: Balsalobre Salmeron MD, García López A, Torregrosa Perez NM, Vazquez Rojas JL. Cistoadenoma mucinoso apendicular con presentación inusual. Cir Esp. 2016;94:537.

^{*} Corresponding author.

E-mail address: mariadolores.balsalobre2@um.es (M.D. Balsalobre Salmeron).