

Under general anesthesia, the common femoral vein was punctured, an 8 fr introducer was placed, and a pigtail catheter was advanced until right atrium. Cavogram confirmed CT angiography findings (Fig. 1B). We placed a cuff vela (ENDOLOGIX INC, 11 Studebaker, Irvine, CA 92618, United States) that excluded the pseudoaneurysm from the circulation without compromising renal and suprahepatics veins. Ten days later CT angiography (Fig. 1C) and cavogram (Fig. 1D) showed stent patency.

Inferior vena cava (IVC) pseudoaneurysm is a hematoma, with disruption of one or more vessel layers, that has high rate of rupture. It can be caused by different injuries (traumatic, iatrogenic injury, etc.) associated or not with inflammatory processes, such as infection. Patients can be completely asymptomatic or present with life-threatening conditions.<sup>1</sup>

Surgical therapies (patch repair, vein grafts, atriocaval shunting, etc.) are definitive treatments for stable patients. Like in our patient, to achieve hemostasis in retrohepatic or subhepatic IVC injuries require extensive organs dissection, worsening the patient condition. That is the reason why it has been estimated mortality up to 70% in such conditions. Endovascular approach should be consider in either stable or unstable hemodynamically patients, since it can be done with relative ease and speed, causing minimal additional surrounding tissue injury.<sup>1,2</sup>

De Naeyer reported the use of a talent endoluminal stent-graft to treat infrarenal IVC perforation due to a lumbar vertebral fusion,<sup>3</sup> Erzurum et al. reported the use of an aneurix aortic extension cuff in a retrohepatic IVC injury during a retroperitoneal leiomyosarcoma resection,<sup>4</sup> and Watarida et al. reported the use of a fenestrated stent-graft for a traumatic juxtahepatic IVC injury.<sup>5</sup>

Since potential risks are associated with the use of these devices in IVC (erosion or even rupture of it, thrombosis and probable pulmonary embolization, etc.) close follow-up of these patients is strongly advised.<sup>2</sup>

Particularly in hemodynamically unstable patients with injury of retrohepatic or subhepatic IVC injury, endovascular approach should be consider, since it can be performed with

relatively speed and ease, offering an alternative solution for such life-threatening condition.

#### REFERENCES

1. Kunkala M, Jenkins D, McEachen J, Stockland A, Zielinski M. Nonoperative management of traumatic suprahepatic inferior vena cava pseudoaneurysms. *J Vasc Surg*. 2011;54 Suppl. 6:80s-2s.
2. Piffaretti G, Carrafiello G, Piacentino F, Castelli P. Traumatic IVC injury repair: the endovascular alternative. *Endovasc Today*. 2013;39-44.
3. De Naeyer G, Degrieck I, Belgium A. Emergent infrahepatic vena cava stenting for life-threatening perforation. *J Vasc Surg*. 2005;41:552-4.
4. Erzurum V, Shoup M, Borge M, Kalman P, Rodriguez H, Silver G, et al. Inferior vena cava endograft to control surgically inaccessible hemorrhage. *J Vasc Surg*. 2003;38:1437-9.
5. Watarida S, Nishi T, Furukawa A, Shiraiishi S, Kitano H, Matsubayashi K, et al. Fenestrated stent-graft for traumatic juxtahepatic inferior vena cava injury. *J Endovasc Ther*. 2002;9:134-7.

Pamela Ines Causa Andrieu<sup>a,\*</sup>, Natalia Gomez<sup>b</sup>,  
Martin Jose Rabellino<sup>a</sup>, Juan Pejokl<sup>b</sup>, Ricardo Garcia-Monaco<sup>a</sup>

<sup>a</sup>Servicio de Radiología Diagnóstica, Hospital Italiano de Buenos Aires, Buenos Aires, Argentina

<sup>b</sup>Servicio de Cirugía, Hospital Italiano de Buenos Aires, Buenos Aires, Argentina

\*Corresponding author.

E-mail address: [pamela.causa@hospitalitaliano.org.ar](mailto:pamela.causa@hospitalitaliano.org.ar)  
(P.I. Causa Andrieu).

2173-5077/

© 2016 AEC. Published by Elsevier España, S.L.U. All rights reserved.

## Spontaneous Perforation of the Rectum With Transanal Evisceration of the Small Bowel: A Case Report and Review of the Literature<sup>☆</sup>

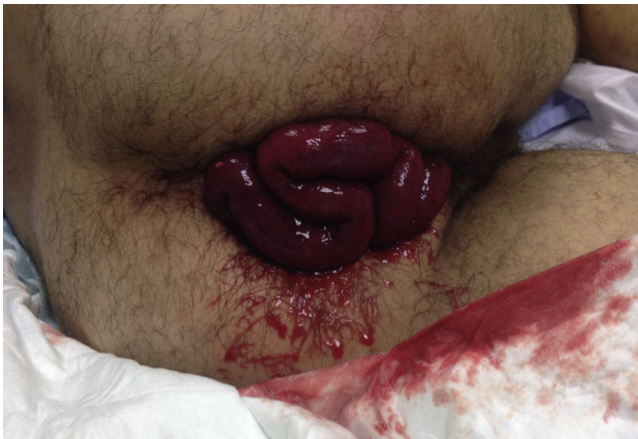

### Perforación rectal espontánea con evisceración transanal del intestino delgado. A propósito de un caso y revisión de la literatura

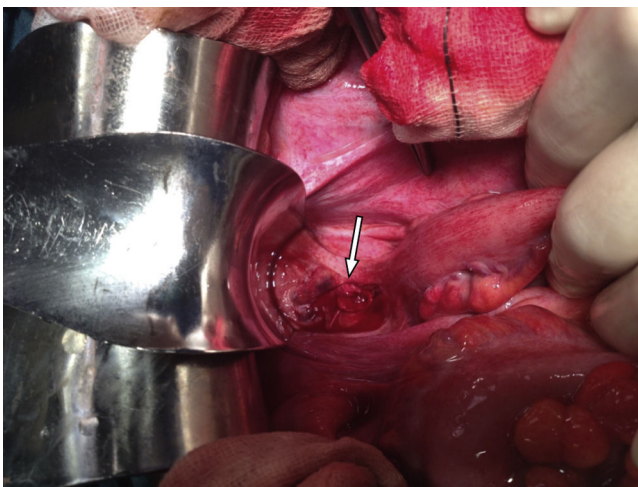
Small bowel prolapse through a spontaneous perforation of the rectum is an extremely rare condition. Since Benjamin Brodie<sup>1</sup> documented the first case in 1827, around 70 cases have been reported in the scientific literature. Rectal perforations with evisceration of intestinal content can have multiple etiologies, which are traditionally classified into 2 groups, trauma-related and spontaneous, whose etiologic mechanism is uncertain.<sup>2</sup>

Small bowel prolapse through a spontaneous perforation of the rectum is an extremely rare condition. Since Benjamin Brodie<sup>1</sup> documented the first case in 1827, around 70 cases have been reported in the scientific literature. Rectal perforations with evisceration of intestinal content can have multiple etiologies, which are traditionally classified into 2 groups, trauma-related and spontaneous, whose etiologic mechanism is uncertain.<sup>2</sup>

<sup>☆</sup> Please cite this article as: Salvador Rosés H, Falgueras Verdaguer L, Marinello F, Farrés Coll R, Codina Cazador A. Perforación rectal espontánea con evisceración transanal del intestino delgado. A propósito de un caso y revisión de la literatura. *Cir Esp*. 2017;95:299-301.



**Fig. 1 – Transanal evisceration of the small bowel in the emergency room.**



**Fig. 2 – Cranial view of the longitudinal intraperitoneal perforation on the anterior side of the rectum.**

We present the case of a patient who developed transanal intestinal evisceration secondary to spontaneous rectal perforation.

The patient is a 34-year-old male who came to the emergency room due to abdominal pain and prolapse of small bowel loops through the anus, which had occurred during the effort of defecation. The patient reported no pathologic history of interest and denied having had a history of rectal trauma, rectal instrumentation, anal sexual activity or constipation. Physical examination detected the protrusion of small bowel loops through the anus with signs of congestion. Following aseptic measures and after having performed lavage with warm saline, the loops were reintroduced into the abdominal cavity to avoid ischemia. The abdomen was soft, with pain upon deep palpation in the hypogastrium and no rebound tenderness. Upon rectal examination, an interruption in the anterior wall of the rectum was palpated. Urgent abdominal CT scan with

endorectal contrast agent demonstrated a rectal perforation located approximately 9–10 cm from the anal margin.

Emergency laparotomy was indicated, which demonstrated a laceration on the anterior side of the rectum, above the perineal flexure, and purulent liquid in the pelvis. The laceration was approximately 4 cm long, extending from 1 cm below the flexure to approximately 3 cm above, with no signs of ischemia. The ileal loops were congestive and edematous, with signs of viability. The sigmoid colon and upper rectum were mobilized, and we proceeded with anterior resection of the rectum, creating an end colostomy in the left iliac fossa. The procedure was completed with lavages of the abdominal cavity.

The patient's condition progressed correctly, and he was discharged on the 6th day post-op. The patient is currently awaiting surgical reconstruction of the intestinal tract (Figs. 1 and 2).

Spontaneous perforation of the rectum with transanal prolapse of intestinal content is a very rare pathology that requires urgent surgical treatment. Most clinical cases described in the literature are elderly, and more than 70% present a history of rectal prolapse.<sup>3,4</sup>

Unlike traumatic perforations, the etiology of spontaneous presentations is unknown. Certain findings, such as the location of the perforation on the anterior side of the rectum and its association with difficult defecation, suggest a spontaneous rupture,<sup>5</sup> as we suspected in the case of our patient. The main risk factor is rectal prolapse, but other risk factors have been described, such as increased depth of the rectovesical and rectovaginal spaces.<sup>6</sup>

There are several hypotheses that may explain the mechanism of spontaneous rectal perforation and intestinal evisceration. Wroblewski and Dailey report that, regardless of the mechanism involved, the sudden increase in intra-abdominal pressure seems to be the main contributing factor, violently pushing the ileal intestinal loops in the rectovesical or rectovaginal space and pressing on the anterior wall of the rectum.<sup>1</sup> Additionally, the antimesenteric border of the rectum presents poorer irrigation. The traction generated by rectal prolapse can favor ischemia in this region and, consequently, perforation.<sup>7</sup> Other etiological hypotheses include situations associated with excessive tension at the anterior side of the rectum or pre-existing rectal disease, such as diverticulosis, colitis, ulceration, adhesions or irradiation.<sup>8</sup>

Management of transanal bowel evisceration requires urgent surgery. The surgical procedure used to treat the rectal perforation and prolapsed bowel segment will depend on the contamination of the peritoneal cavity, intestinal viability, comorbidities and the hemodynamic state of the patient. The treatment of choice is resection of the perforated rectal segment and rectosigmoid anastomosis in a single operation.<sup>9</sup> The alternative is a Hartmann's procedure with end colostomy and reconstruction of the tract in a second operation. In the case we present, we decided not to perform colorectal anastomosis because, at the time of surgery, the etiology of the perforation was unknown and we suspected the cause had been trauma-related.

In conclusion, transanal evisceration is an unusual surgical emergency. Elderly patients with chronic rectal prolapse and increased intra-abdominal pressure present higher risk.

Evisceration usually occurs during the effort of defecation and involves abdominal pain and transanal protrusion of the bowel. As described in this case report, this pathology can also appear in young patients with no associated risk factors.

#### REFERENCES

1. Wroblewski DE, Dailey TH. Spontaneous rupture of the distal colon with evisceration of small intestine through the anus: report of two cases and review of the literature. *Dis Colon Rectum*. 1979;22:569-72.
2. Nari GA, Moreno E, Ponce O. Transanal prolapse of the small intestine secondary to spontaneous rupture of the rectum. *Ann Chir*. 2001;126:818-20 [in French].
3. Furuya Y, Yasuhara H, Naka S, Yamazaki K, Yanagie H, Wakahara T, et al. Intestinal evisceration through the anus caused by fragile rectal wall. *Int J Colorectal Dis*. 2008;23:721-2.
4. Berwin JT, Ho TK, D'Souza R. Small bowel evisceration through the anus-report of a case and review of literature. *BMJ Case Rep*. 2012;2012.
5. Bhat S, Azad TP, Kaur M. Spontaneous perforation of rectum with evisceration of small bowel simulating intussusception. *N Am J Med Sci*. 2010;2:596-7.
6. Ellul JP, Mannion S, Khoury GA. Spontaneous rupture of the rectum with evisceration of the small intestine through the anus. *Eur J Surg*. 1995;161:925-7.
7. De Vogel PL, Kamstra PE. Rupture of the rectum with evisceration of small intestine through the anus: a complication of advanced rectal prolapse. Case report. *Eur J Surg*. 1994;160:187-8.
8. Al-Abkari HA. Spontaneous rupture of the rectum with evisceration of omentum through the anus: a case report and review of the literature. *Ann Saudi Med*. 2000;20:246-7.
9. Papapolychroniadis C, Kaimakis D, Giannoulis K, Parlapani A, Karpini E, Georgiou M, et al. Spontaneous rupture of the rectosigmoid with small bowel evisceration through the anus. *Tech Coloproctol*. 2004;8 Suppl 1:S126-8.

Helena Salvador Rosés\*, Laia Falgueras Verdaguer, Franco Marinello, Ramón Farrés Coll, Antonio Codina Cazador

Departamento de Cirugía General y del Aparato Digestivo, Hospital Universitario de Girona Doctor Josep Trueta, Girona, Spain

\*Corresponding author.

E-mail address: [hsalvadorroses@gmail.com](mailto:hsalvadorroses@gmail.com)

(H. Salvador Rosés).

2173-5077/

© 2016 AEC. Published by Elsevier España, S.L.U. All rights reserved.

## Normothermic ex Vivo Liver Perfusion From Donors After Type 2 Cardiac Arrest<sup>☆</sup>



## Perfusión normotérmica ex vivo de injerto hepático procedente de donante en asistolia tipo 2

The use of liver grafts from non-heart-beating donors is one of the most effective strategies for increasing the availability of organs for transplantation.<sup>1</sup> However, its utility is limited due to the impact on the quality of the organ of the period of warm ischemia after cardiac arrest.

Ex vivo normothermic machine perfusion (NMP) can be considered a useful tool for assessing the viability of marginal organs before liver transplantation and thereby assisting in the decision-making process. The NMP method is able to evaluate post-reperfusion injury, without compromising the situation of a recipient in critical condition.

The international multi-center prospective study COPE-WP2 (in which our hospital participated) compared the effect of NMP and classic cold preservation on the prevention of

preservation injury and graft dysfunction.<sup>2</sup> The liver grafts used in this study were from brain-dead donors or type 3 non-heart-beating donors. With the experience acquired, we can confirm that the use of NMP is feasible and can improve organ quality by ostensibly reducing cold ischemia time, which is limited to bench surgery. This fact explains why NMP is especially attractive in grafts that are more vulnerable to injury caused by cold ischemia, such as type 2 non-heart-beating donation (NHBD-T2).

Although NHBD-T2 are especially important to generate liver grafts,<sup>3</sup> their use is limited by the inferior post-transplantation results compared to those obtained with conventional donors.<sup>4-7</sup> This determines the partial acceptance of liver grafts from NHBD-T2. In an experimental model,

<sup>☆</sup> Please cite this article as: Pavel M-C, Fondevila Campo C, Molina Santos V, Diaz Lorca A, Garcia-Valdecasas Salgado JC. Perfusión normotérmica ex vivo de injerto hepático procedente de donante en asistolia tipo 2. *Cir Esp*. 2017;95:301-303.