



Image of the month

Foreign Body of the Rectum[☆]

Cuerpo extraño rectal

Elena Romera Barba,^{*} Rafael González-Costea Martínez, María Inmaculada Navarro García, José Luis Vázquez Rojas

Servicio de Cirugía General y del Aparato Digestivo, Hospital General Universitario Santa Lucía, Cartagena, Murcia, Spain

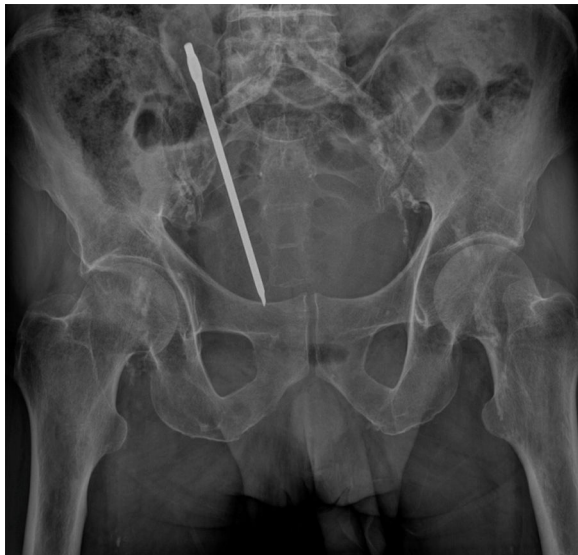

Fig. 1

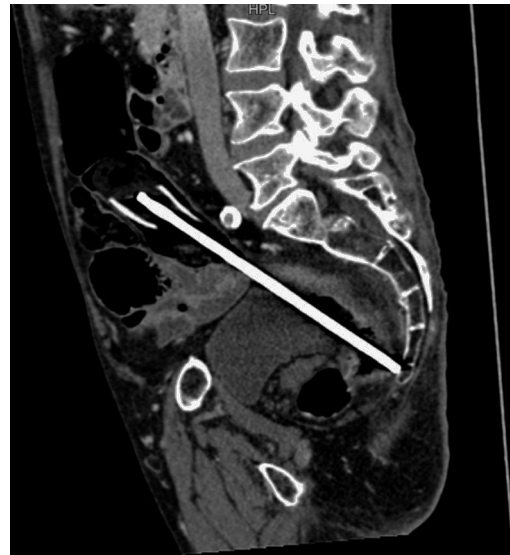


Fig. 2

The patient is a 68-year-old male with a history of a villous adenoma that had been removed using colonoscopy, who came to the emergency room due to the introduction of a screwdriver in the anus. During abdominal examination, he presented pain in the hypogastrum upon palpation, with no defense or peritonism. During digital rectal examination, the end of a metallic object could be felt with the tip of a finger, although it could not be extracted. Abdominal radiograph (Fig. 1) demonstrated the foreign body within the pelvis. Abdominal computed tomography (Fig. 2) confirmed its presence and location, while also ruling out bowel perforation. Under spinal blockage, the object was extracted transanally, followed by rectoscopy, which showed no injury to the rectal mucosa. The patient was discharged 24 h later, with no complications.

[☆] Please cite this article as: Romera Barba E, González-Costea Martínez R, Navarro García MI, Vázquez Rojas JL. Cuerpo extraño rectal. Cir Esp. 2017;95:169.

^{*} Corresponding author.

E-mail address: percentila@hotmail.com (E. Romera Barba).