



Scientific letters

Somatostatin Receptors Expression in Breast Cancer[☆]

Expresión de receptores de somatostatina en cáncer de mama

Breast cancer is the leading cause of cancer-related death in women. The American Cancer Society estimates that 40 890 women will die of the disease within 2016 in the United States.¹ Data of mortality from breast cancer has been improving over the past 25 years, mainly in relation to developments in early detection and better treatment.² The estimated number of breast cancers diagnosed in Spain during 2014 was 26 354; this number represented an adjusted rate to the European standard population of 85 per 100 000 women.³ Breast cancer is heterogeneous disease, including different histological, immunological and molecular subtypes. Several studies have reported somatostatin receptors in primary breast cancers.⁴⁻⁷ We present the case of an unsuspected breast carcinoma with expression of somatostatin receptors diagnosed by imaging during the assessment of a hypertension study. Written informed consent for scientific use of the images was obtained from the patient.

A 46-year-old woman was referred to Nuclear Medicine Department with the suspicion of pheochromocytoma or paraganglioma. She had a 2-year history of resistant hypertension. Laboratory findings revealed increased urinary levels of norepinephrine 231 $\mu\text{g}/24\text{ h}$ (normal range 15–80 $\mu\text{g}/24\text{ h}$) and vanillylmandelic acid 8.5 mg/24 h (normal range 2–8 mg/24 h), with normal serum levels of renin 10 pg/ml (normal range 2–21 pg/ml) and aldosterone 18 ng/dl (normal range 2–23 ng/ml). ¹²³I-Metaiodobenzylguanidine whole-body scintigraphy showed a suboptimal image quality due to anti-hypertensive therapy. In this context, ¹¹¹In-Pentetreotide scan was requested (Fig. 1). Whole-body and single photon emission computed tomography (SPECT) scans identified a focal pathological uptake in the left chest wall, although its exact location (breast or axilla) was not achieved. Left lateral thoracic planar image performed with the patient lying prone revealed the localization of the focal uptake in the breast tissue.

Physical examination was normal. Complementary imaging tests (Fig. 2) included mammography, ultrasound

scan and magnetic resonance imaging (MRI). Mammography showed fibroglandular tissue, but focal mass was not detected. Ultrasound scan identified a hypo echoic and

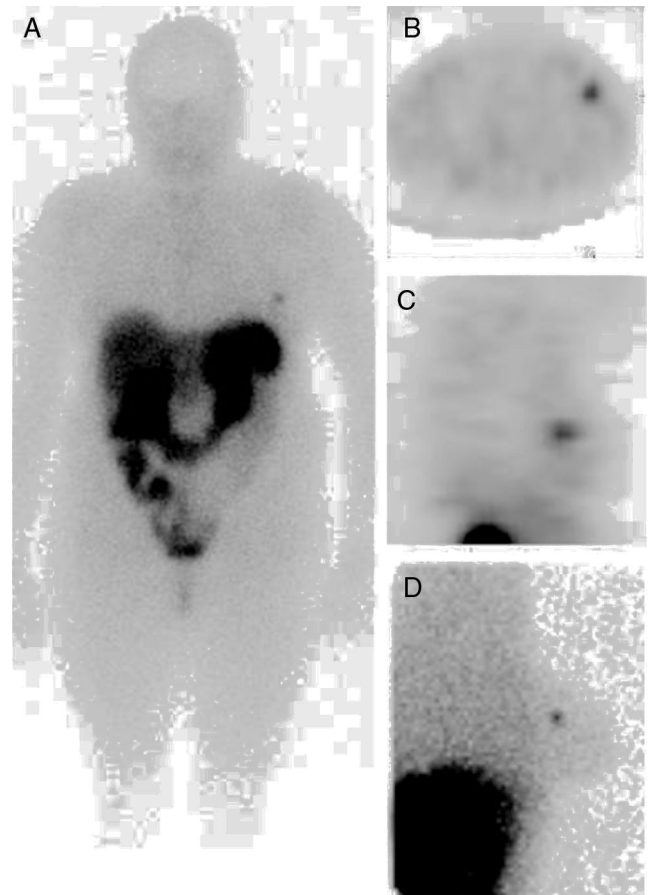


Fig. 1 – Whole-body (A), SPECT (axial view [B], sagittal view [C]) and left lateral planar in prone position (D) images identified a focal increased uptake in the left breast.

[☆] Please cite this article as: Gómez-de la Fuente F-J, Jiménez-Bonilla J, Estévez J, Martínez-Rodríguez I, Banzo I. Expresión de receptores de somatostatina en cáncer de mama. Cir Esp. 2017;95:545–547.

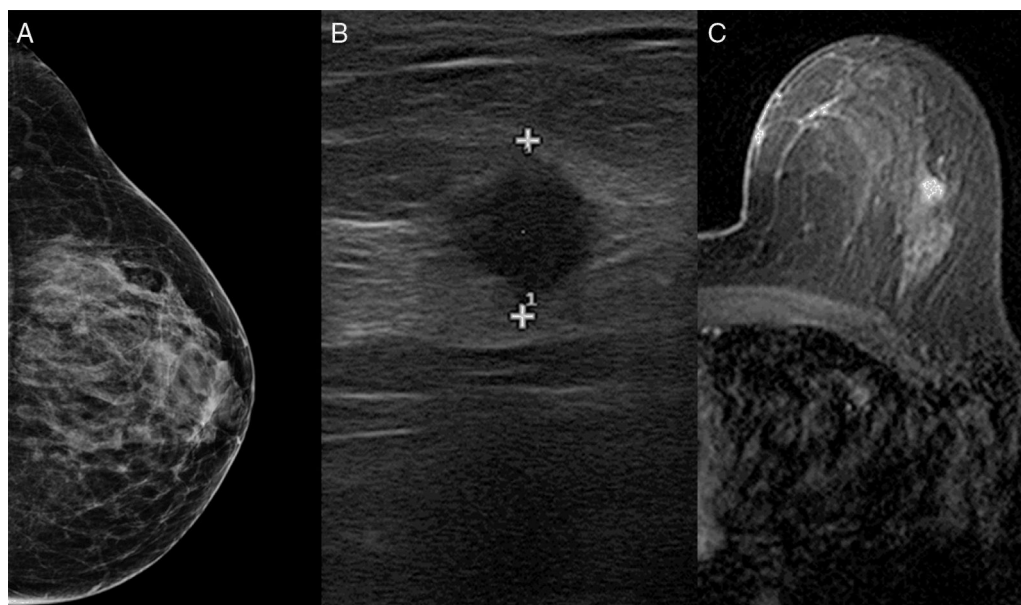


Fig. 2 – Mammogram (A) showed fibroglandular tissue. Ultrasonogram (B) identified a 10 mm nodule within the left breast. MRI (C) located the lesion at the upper outer quadrant of the left breast with kinetic malignant features.

homogeneous nodule of 10 mm in the left breast. MRI located the lesion at the upper-outer quadrant of the left breast, with kinetic malignant features. No other lesion was found. A large needle biopsy was performed. Histological result revealed ductal carcinoma, ER+++ , PR+++ , Cadherine-E+++ , Ki-67 10% and Her-2+.

The patient underwent left lumpectomy and sentinel lymph node biopsy. After a concentric incision around areola in upper-outer quadrant, an excision of tissue with wire-guided localization was performed. Specimen size was 6 × 6 × 3 cm in its length × width × height. Distance from closet margin was 5 mm. Two sentinel lymph nodes were removed at axilla level II. Final pathological analysis reported an invasive ductal carcinoma of 0.8 mm, Grade 1 (tubule formation, score 2; nuclear pleomorphism, score 2; mitotic count, score 1). No vascular, lymphatic or perineural invasion was observed. Immunohistochemical staining of the tumor cells were positive for neuroendocrine proteins chromogranin and synaptophysin. The two-sentinel lymph node were negative for metastases. Adjuvant hormoneotherapy with Tamoxifen and radiotherapy (48 Gy, with boost to the tumor bed) was also administered with good tolerance. After 9 months, she continues on treatment with Tamoxifen (20 mg/24 h). There is no clinical evidence of recurrence. Hypertension has been controlled with Spironolactone 25 mg/48 h; Amlodipine + Valsartan 10/160 mg/24 h; Bisoprolol 2.5 mg/12 h.

¹¹¹In-Pentetreotide scintigraphy allows study in vivo of the presence of somatostatin receptors, mainly subtype 2, but also subtype 5. Somatostatin receptors are frequently expressed in breast cancer compared to normal breast tissue.^{4,5,8} Reubi et al. demonstrated somatostatin receptors in 46% of breast cancer tissues analyzed by in vitro autoradiography.⁶ This incidence was even higher (74%) in a series of 52 primary

breast carcinomas reported by van Eijck et al, who used somatostatin receptor imaging.⁴ In other report, Bajc et al. found a higher incidence of somatostatin receptors in patients with breast cancer than in controls, and detected all ductal breast carcinomas greater than 20 mm in size studied with ¹¹¹In-Pentetreotide scan.⁵

Among the 5 subtypes of somatostatin receptors, the subtype 2 is predominant in breast cancer. A correlation between the tumor grade and the expression of somatostatin receptor 2 has been indicated by Orlando et al.⁷ These authors found that breast cancers expressing an up regulation of somatostatin receptor 2 mRNA may have a better prognosis. The presence of somatostatin receptor 2 has been also correlated with estrogen and progesterone levels.⁹ Frati et al.¹⁰ reported also a correlation between expression of somatostatin receptors subtype 2 and subtype 4 with luminal breast cancer, but not with triple negative or HER2 tumor marker.

We considered that the present clinical case is relevant in different aspects. First, the management of the breast lesion initially detected on somatostatin receptor imaging led up to early diagnosis of breast cancer in an asymptomatic patient from the breast point of view. Lesion size and somatostatin receptors density would be determining factors for the breast cancer imaging with somatostatin scintigraphy.⁸ Second, as the tumor was positive on ¹¹¹In-Pentetreotide imaging, an indicator of somatostatin receptors expression, the surgical specimen was immunohistochemically tested to search neuroendocrine markers. This procedure is not routinely performed in invasive breast carcinomas. Third, the patient might benefit from treatment with somatostatin analogs, although the clinical studies still have to demonstrate the effectiveness of the use of such therapy in breast cancer patients.

REFERENCES

1. Siegel RL, Miller KD, Jemal A. Cancer Statistics, 2016. *CA Cancer J Clin.* 2016;66:7-30.
2. Berry DA, Cronin KA, Plevritis SK, Fryback DG, Clarke L, Zelen M, et al. Effect of screening and adjuvant therapy on mortality from breast cancer. *N Engl J Med.* 2005;353:1784-92.
3. Galcerani J, Ameijide A, Carulla M, Mateos A, Quirós JR, Alemán A, et al. Estimaciones de la incidencia y la supervivencia del cáncer en España y su situación en Europa. Red española de registros de cáncer (REDECAN); 2014. Available from: <http://www.redecn.org> [accessed 07.09.16]
4. Van Eijck CHJ, Krenning EP, Bootsma A, Oei HY, van Pel R, Lindemans J, et al. Somatostatin-receptor scintigraphy in primary breast cancer. *Lancet.* 1994;343:640-3.
5. Bajc M, Ingvar C, Palmer J. Dynamic Indium-111-Pentetreotide scintigraphy in breast cancer. *J Nucl Med.* 1996;37:622-6.
6. Reubi JC, Waser B, Foekens JA, Klijn G, Lamberts SWJ, Laissue J. Somatostatin receptor incidence and distribution in breast cancer using receptor autoradiography: relationship to EGF receptors. *Int J Cancer.* 1990;46:416-20.
7. Orlando C, Raggi CC, Bianchi S, Distante V, Simi L, Vezzosi V, et al. Measurement of somatostatin receptor subtype 2 mRNA in breast cancer and corresponding normal tissue. *Endocr Relat Cancer.* 2004;11:323-32.
8. Dalm S, Melis M, Emmering J, Kwekkeboom DJ, de Jong M. Breast cancer imaging using radiolabelled somatostatin analogues. *Nucl Med Biol.* 2016;43:559-65.
9. Kumar U, Grigorakis SI, Watt HL, Sasi R, Snell L, Watson P, et al. Somatostatin receptors in primary human breast cancer: quantitative analysis of mRNA for subtypes 1-5 and correlation with receptor protein expression and tumor pathology. *Breast Cancer Res Treat.* 2005;92:175-86.
10. Frati A, Rouzier R, Lesieur B, Werkoff G, Antoine M, Rodenas A, et al. Expression of somatostatin type-2 and -4 receptor and correlation with histological type in breast cancer. *Anticancer Res.* 2014;34:3997-4003.

Francisco-Javier Gómez-de la Fuente^a, Julio Jiménez-Bonilla^a, José Estévez^b, Isabel Martínez-Rodríguez^a, Ignacio Banzo^{a,*}

^aServicio de Medicina Nuclear, Grupo de Investigación Imagen Molecular IDIVAL, Hospital Universitario Marqués de Valdecilla, Universidad de Cantabria, Santander, Spain

^bServicio de Obstetricia y Ginecología, Hospital Universitario Marqués de Valdecilla, Universidad de Cantabria, Santander, Spain

*Corresponding author.

E-mail address: ignacio.banzo54@gmail.com (I. Banzo).

2173-5077/

© 2016 AEC. Published by Elsevier España, S.L.U. All rights reserved.

Giant Primary Extra Gastrointestinal Stromal Tumor of the Liver[☆]



Tumor del estroma extragastrointestinal primario hepático gigante

Gastrointestinal stromal tumors (GIST) are a group of mesenchymal neoplasms that affect the gastrointestinal tract, defined by the expression of the CD117 (c-kit) onco-protein.¹ Their appearance outside of the gastrointestinal tract is uncommon.

We present a case of primary hepatic extra-gastrointestinal stromal tumor (EGIST) in an adult patient with a negative extension study for another primary tumor, who was treated surgically, progressed favorably and is currently disease free.

The patient is a 41-year-old male with no personal history of interest. He was under study for abdominal discomfort and

weight loss in previous months. Upon examination, a mass was observed in the hypochondrium and right flank, which reached the right anterior superior iliac spine. Complete blood count was normal, with the following biochemistry results: cholesterol = 222 mg/dL (HDL = 69 mg/dL); total bilirubin = 1.65 g/dL at the expense of indirect (1.38 mg/dL) and GGT = 102 U/L. Liver enzymes, coagulation and tumor markers (α -fetoprotein, CEA, CA-125, CA 15.3 and CA 19.9) were normal.

CT scan and MRI showed a mass measuring 20 × 19.5 × 13.6 cm in length with significant contrast uptake, central necrotic areas and exophytic location (liver segments V and VI), with no infiltration of neighboring organs. The

[☆] Please cite this article as: Carrillo Colmenero AM, Serradilla Martín M, Redondo Olmedilla MD, Ramos Pleguezuelos FM, López Leiva P. Tumor del estroma extragastrointestinal primario hepático gigante. *Cir Esp.* 2017;95:547-550.