



CIRUGÍA ESPAÑOLA

www.elsevier.es/cirugia



Image of the month

Cutaneous Fistula Caused by Postcholecystectomy Residual Lithiasis[☆]



Fístula cutánea secundaria a litiasis residual poscolecistectomía

E. Rovira Pujol,^{*} N. Artech Gonzalez, F. Lopez Lanau

Unidad de la Hiperplasia Benigna de Próstata, Hospital Santa Caterina, Salt, Gerona, Spain

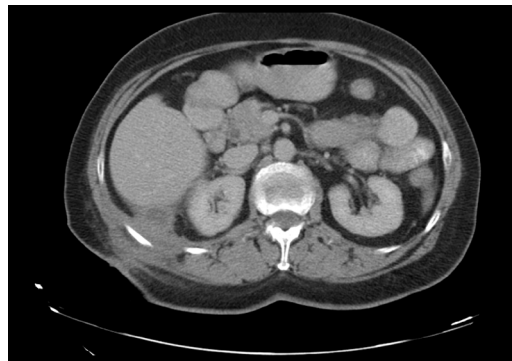


Fig. 1

A 68-year-old patient with a history of cholecystitis, treated with emergency surgery, presented a fistulous cutaneous lesion secondary to residual post-cholecystectomy lithiasis.

Laparoscopic approach of the cutaneous fistula and examination of the abdominal cavity (Fig. 1).

[☆] Please cite this article as: Rovira Pujol E, Artech Gonzalez N, Lopez Lanau F. Fístula cutánea secundaria a litiasis residual poscolecistectomía. Cir Esp. 2017;95:346.

^{*} Corresponding author.

E-mail address: Retse98rov@hotmail.com (E. Rovira Pujol).